Elsadawy *et al. Egypt J Radiol Nucl Med* (2024) 55:39
https://doi.org/10.1186/s43055-024-01204-3

Egyptian Journal of Radiology and Nuclear Medicine

RESEARCH

Open Access

Bronchogenic carcinoma: the added value of FDG PET/CT advanced volumetric and metabolic parameters in initial evaluation and their impact on prognosis and clinical outcome

Momena Essam Ibrahim Elsadawy[1*], Yehia Omar[2] and Noha M. Taha[1]

Abstract

Background Bronchogenic carcinoma is considered to be one of the most common causes of cancer-related mortalities. It is divided into two main subtypes; small cell and non-small cell carcinoma. CT is considered the most commonly used radiological modality for early detection and staging. PET/CT can efficiently give both structural and functional information about the tumoral mass and malignant activity overall the body and hence can accurately assess the tumor staging and tumor response to therapy. Our study aim was to evaluate the different ^{18}F-FDG PET/CT advanced volumetric and metabolic parameters in initial staging of bronchogenic carcinoma and their capability to predict the impact on prognostic pathway and hence the clinical outcomes.

Results Forty patients with pathologically proven bronchogenic carcinoma were included in this study, and all of them did PET/CT in which different volumetric and metabolic parameters were measured and showed significant differences in different tumor grades.

Conclusion PET/CT can give both structural and functional data about the tumor mass adding to its proper assessment of the initial evaluation and predicting its prognostic pathway.

Keywords PET/CT, Bronchogenic carcinoma, SUV, TLG, MTV

Background

Bronchogenic carcinoma is one of the most common causes of cancer-related mortalities. Bronchogenic carcinoma subdivided into two main histopathological subtypes; non-small cell, which is more common, and small cell type [1].

Different radiological imaging modalities play an essential role in staging and hence prognosis of bronchogenic carcinoma [2].

CT has been considered as the imaging modality of choice for bronchogenic carcinoma staging due to its rapid scanning, high-resolution images and wide availability, but it has some limitations as in proper differentiation of the actual tumoral margins from the adjacent non-malignant pulmonary changes such as the consolidation, atelectasis and collapse [3]. Also, assessment of mediastinal, pericardial and pleural invasions is sometimes challenging in CT [4].

*Correspondence:
Momena Essam Ibrahim Elsadawy
Momena.essam@yahoo.com
[1] Ain Shams University, Cairo, Egypt
[2] Misr Radiology Center, Cairo, Egypt

Bronchogenic carcinoma radiological follow-up to assess response to therapy using CT has been well established using response evaluation criteria in solid tumor (RECIST criteria) relying mainly on the tumoral mass size change [5]. Yet, the structural changes may occur later following positive biological response and hence giving a false impression of stationary disease course. Also, hemorrhage and central necrosis secondary to treatment regimen may be the cause of some tumor mass size increase, giving a pseudo-progressive CT image [6, 7].

PET/CT is a special radiological modality that can efficiently assess both structural as well as tumoral metabolic activities by tracing fluorodeoxyglucose (FDG) metabolic uptake by the pathologically malignant tissue [8]. So, it can accurately help to delineate the size and activity of the tumor mass, also it can effectively detect the early biological changes in therapy response that is even precede the structural changes. In addition, PET/CT can effectively detect pulmonary nodules activity and hence differentiating the benign from malignant lesions as well as early and precise detection of metastatic lesions [9].

Bronchogenic carcinoma follow-up using PET/CT was mainly relying on tumor mass changes of standardized uptake value (SUV uptake). Other volumetric and metabolic parameters have been recently added mainly to enhance the assessment of tumor staging, which include total lesion glycolysis (TLG) and metabolic tumor volume (MTV) that have proved to be sensitive parameters in accurate staging process [10].

PET/CT can efficiently give both structural and functional information regarding both tumoral mass and malignant activity overall the body and hence can precisely assess the tumor staging as well as the response to therapy [11].

The aim of the current work was mainly to evaluate the different ^{18}F-FDG PET/CT advanced volumetric and metabolic parameters in initial staging of bronchogenic carcinoma and their capability to predict the impact on prognostic pathway and hence the clinical outcomes.

Methods

Patients

- This study was conducted during the period from November 2022 till June 2023. Forty patients were included with pathologically proven bronchogenic carcinoma, twenty-four of which were males (63.2%) and sixteen were females (36.8%) with age group ranging between 38 and 70 years and 55.42 mean age (Table 1). They came to the radiology department for initial staging.

Table 1 Demographic data of patients

	Min	Max	Mean	SD
Age (years)	38.00	70.00	55.42	9.19
		N	%	
Sex	Male	24	63.2%	
	Female	16	36.8%	

- The study was a retrospective evaluation after getting approval of the concerned ethical committee with written consent requirement.
- The images were recalled from our picture archiving and communication system (PACS).
- The inclusion criteria were adult patients (above 18 years old) pathologically proven bronchogenic carcinoma without any sex predilection.
- The exclusion criteria included treated bronchogenic carcinoma cases and poor-quality images that were an obstacle for proper assessment. Pediatric patients below 18 years old were also not included in our study. Patients with high blood glucose level (more than 150 mg/dl) and pregnant patients were also not included as well.

Technique of FDG PET/CT examination

- Hybrid PET and CT images were performed by PET/CT system (GE medical system; Discovery IQ 16 PET/CT scanner; USA). The whole-body PET images were performed from the skull vault down to the knee by using multiple bed positions acquisition, each was approximately 15-cm axial filed with 4-mm spatial resolution and 2-min time of acquisition of the emission scan for each bed, with 12–17-min total time range. The patients were strictly informed to be totally fasting for 6–8 h prior to the examination, and the blood glucose level was strictly kept less than 150 mg/dl before tracer injection. The scan was performed 45–60 min after injection of 0.1-mCi 18F-FDG/kg.
- A diagnostic post-contrast-enhanced CT scan was performed immediately after PET images with injection of 100 ml of non-ionic iodinated contrast media (Omnipaque 300) at 2–3 ml/s rate in contrast studies using the following parameters: 120 kV, 350 mA, 5-mm slice thickness and 0.5 tube rotation time. All the patients were scanned from the skull bases down to the mid-thigh.
- PET, CT and the fused PET/CT images were reviewed by GE workstation, multi-planner refor-

matted images, 3D maximum intensity projection (MIP) images were reconstructed for the PET images.

Data analysis

Images analysis

- The FDG PET/CT images were evaluated independently by three radiologists with a range of 10–15 years' experience in nuclear medicine imaging reporting field, and the final diagnosis was reached by consensus in case of discrepancy.
- The FDG PET/CT images were evaluated initially by the qualitative visual analysis of the metabolically active lesions by measuring the maximum standardized uptake value (SUVmax), total lesion glycolysis (TLG) and metabolic tumor volume (MTV) of the main tumor by drawing a region of interest (ROI) on the lesion.
- SUVmax: Maximum concentration of FDG in the lesion of interest (injected dose/body weight). MTV: Metabolic tumor volume which is calculated by including an area of the tumor with FDG concentration equal or more than 41% (well-known standard software cut-off point) of SUVmax in the region of interest (ROI). TLG: Total lesion glycolysis is the sum of multiplication of MTV and SUVmean together in each lesion.
- SUVmax, TLG and MTV were also measured at the most active regional nodal deposits and other distant metastatic deposits if present.

Statistical analysis

- Data were analyzed by Statistical Package for the Social Sciences (IBM Corp. Released 2017. IBM SPSS Statistics for Windows, Version 25.0. Armonk, NY: IBM Corp.). Parametric quantitative data were described as mean ± standard deviation (SD), which were described as frequency and percentage. Median and range values were used to describe the non-parametric quantitative data. An independent same *t*-test was performed as well to compare the mean of continuous variables.
- The sensitivity and specificity were calculated as well. Receiver operator characteristic (ROC) curve analysis was done to calculate the optimal cut-off value. The odd ratio reciprocal was calculated and described the negative association (odd ratio reciprocal = 1/original odd ratio). P value < 0.05 was considered as statistically significant.

Results

Forty patients with pathologically proved bronchogenic carcinoma were included in the current study, twenty-four of them were males (63.2%) and sixteen were females (36.8%) with age group ranging between 38 and 70 years and 55.42 mean age (Table 1).

Adenocarcinoma was the most common primary pathology (32 lesions, 84.2%) followed by squamous cell carcinoma (4 lesions, 10.6%) and two lesions were pathologically proved as large cell carcinoma (2 lesions, 5.2%) and small cell carcinoma accounted for 2 lesions (5.2%). Regarding the histopathological grading, 18 patients (47.4%) were grade II, 8 patients (15.8%) were grade III and 14 patients (36.8%) were grade IV (Table 2).

Regarding the cell differentiation, 10 lesions (21.1%) were low grade/well differentiated, 4 lesions (10.5%) were intermediate grade/moderately differentiated and 26 lesions (68.4%) were high grade/poorly differentiated (Table 2).

Table 2 Histopathological criteria of bronchogenic carcinoma

		N	%
Side	Right	28	73.7
	Left	12	26.3
Site	Upper lobe	32	78.9
	Lower lobe	6	15.8
	Middle lobe	2	5.3
Histopathological grade	Grade 2	18	47.4
	Grade 3	8	15.8
	Grade 4	14	36.8
Histopathology	Adenocarcinoma	32	84.2
	Squamous cell carcinoma	4	10.6
	Large cell carcinoma	2	5.2
	Small cell carcinoma	2	5.2
T staging	T1	2	5.2
	T2	12	31.6
	T3	10	26.3
	T4	16	36.8
N staging	N0	18	47.4
	N2	14	31.6
	N3	8	21.1
M staging	M0	24	57.9
	M1	16	42.1
Pathological stage	1a3	12	31.6
	3a	10	26.3
	4b	16	42.1
Grade (cell diff)	Low (well differentiated)	10	21.1
	Intermediate (moderately differentiated)	4	10.5
	High (poorly differentiated)	26	68.4

Most of the lesions (28 lesions) were seen in the right lung lobe (73.6%) and 12 lesions (26.3%) were seen in the left lung lobe, 32 lesions were in the upper lobes (78.9%), six lesions were in the lower lobes (15.8%) and two lesions were in the middle lobe (5.3%) (Table 2).

Regarding the TNM staging of the patients, two patients were T1 stage (5.3%), 12 patients were T2 stage (31.6%), 10 patients were T3 stage (26.3%) and 16 patients were T4 stage (36.8%). Eighteen patients were N0 stage (47.4%), 14 patients were N2 stage (31.6%) and eight patients were N3 stage (21.1%). Twenty-four patients were M0 stage (57.9%), and 16 patients were M1 stage (42.1%) (Table 2).

Table 3 Minimum, maximum, standard deviation and mean values of SUVmax, MTG and TLG

	Min	Max	Mean	SD
SUVmax	3.00	23.00	11.89	5.46
SUVmean	2.00	21.70	10.88	5.37
MTV	8.30	47.40	25.83	11.96
TLG	30.00	650.00	313.32	217.29

The mean SUVmax in different carcinoma subtypes was measured 11.89, the mean value of SUVmean measured 10.88, while the mean value of MTV equals 25.83, and the mean value of TLG was 313.32 (Table 3).

There were highly significant differences in volumetric and metabolic parameters including TLG and SUVmax in different tumor stages, T stages and pathological stage of bronchogenic carcinoma with P value < 0.001 and P value as shown in Tables 4 and 5, Figs. 1, 2, 3, 4 and 5.

Regarding the cell differentiation into low-, intermediate- and high-grade tumors, significant relationship was seen as well between the tumor grading and the PET/CT parameters with P value 0.001 in SUVmax, TLG and P value 0.003 in MTV (Table 6).

No significant relationship was seen between different types of bronchogenic carcinoma and SUVmax, TLG and MTV with P value 0.33, 0.5 and 0.72, respectively.

A highly significant relationship was seen between MTV between the different grades, T stages and pathological stage of bronchogenic carcinoma with P value 0.002 and P value 0.003 as shown in Table 5.

Table 4 Relation between SUVmax and histopathological criteria of tumor

		SUVmax		Test value	*P* value
		Mean	SD		
Side	Right	13.43	5.27	2.28*	0.04
	Left	7.60	3.51		
Site	Upper lobe	11.33	5.59	0.86*	0.40
	Middle/lower lobe	14.00	5.03		
Histopathological grade	Grade 2	7.22[a]	2.77	18.80**	< 0.001
	Grade 3	15.33[b]	3.06		
	Grade 4	16.43[b]	3.64		
Histopathology	Adenocarcinoma	12.44	5.34	1.00*	0.33
	Other types	9.00	6.24		
T staging	T1/T2	6.14	1.95	6.07*	< 0.001
	T3/T4	15.25	3.65		
LN	Negative	8.44	4.19	3.23*	0.01
	Positive	15.00	4.62		
M staging	M0	9.18	4.77	3.09*	0.01
	M1	15.63	4.07		
Pathological stage	1a3	6.00[a]	2.10	12.42**	0.001
	3a	13.00[b]	4.24		
	4b	15.63[b]	4.07		
Grade (cell diff)	Low (well differentiated)	6.25[a]	2.36	10.61**	0.001
	Intermediate (moderately differentiated)	5.50[a]	2.12		
	High (poorly differentiated)	14.62[b]	4.17		

* Student's t-test **One-way ANOVA test (a,b: post hoc test)

Table 5 Relation between TLG and histopathological criteria of tumor

		TLG		Test value	*P* value
		Mean	SD		
Side	Right	376.93	205.19	2.40*	0.03
	Left	135.20	147.67		
Site	Upper lobe	272.40	206.87	1.67*	0.11
	Middle/lower lobe	466.75	209.34		
Histopathological grade	Grade 2	111.44[a]	93.00	36.56**	< 0.001
	Grade 3	485.33[b]	82.98		
	Grade 4	499.14[b]	107.73		
Histopathology	Adenocarcinoma	328.50	217.51	0.69*	0.50
	Other types	232.33	241.72		
T staging	T1/T2	84.14	47.35	7.66*	< 0.001
	T3/T4	447.00	152.05		
LN	Negative	183.56	176.87	2.95*	0.01
	Positive	430.10	186.09		
M staging	M0	216.27	195.06	2.63*	0.02
	M1	446.75	178.63		
Pathological stage	1a3	70.33[a]	32.99	13.07**	< 0.001
	3a	391.40[b]	153.21		
	4b	446.75[b]	178.63		
Grade (cell diff)	Low (well differentiated)	75.50[a]	33.28	12.49**	0.001
	Intermediate (moderately differentiated)	60.00[a]	42.43		
	High (poorly differentiated)	425.46[b]	164.99		

* Student's t-test **One-way ANOVA test (a,b: post hoc test)

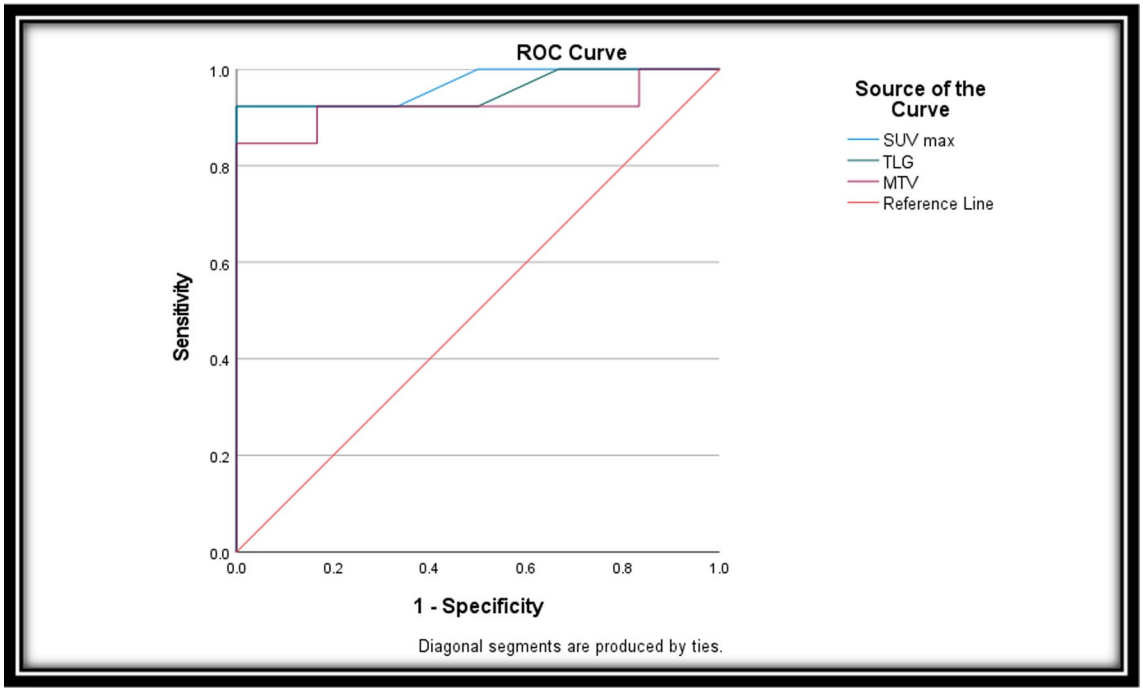

Fig. 1 ROC curve for ability of SUVmax, TLG and MTV for differentiation of grade (high grade vs low/intermediate grade)

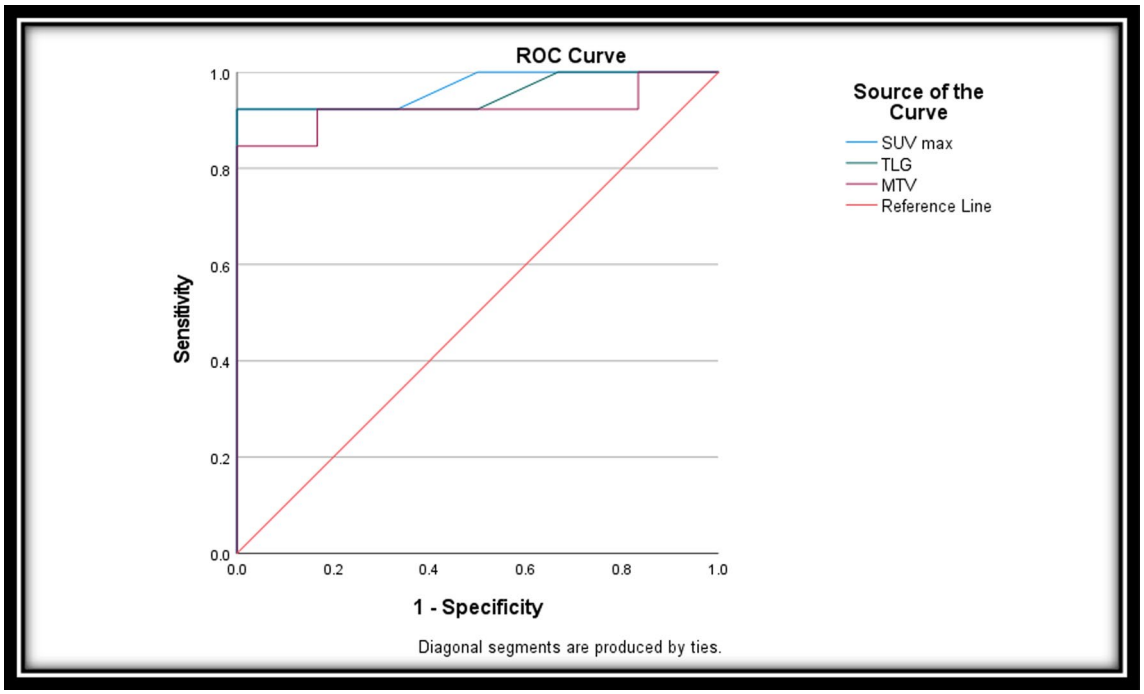

Fig. 2 ROC curve for ability of SUVmax, TLG and MTV for differentiation of stage (stage 3a/4b vs stage 1a)

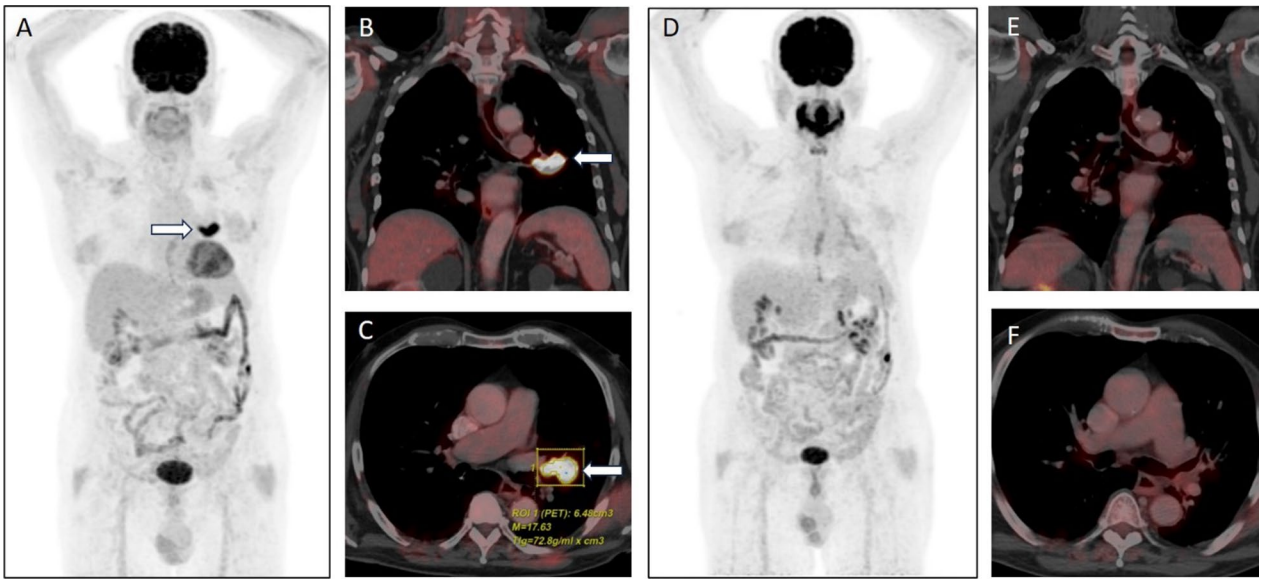

Fig. 3 A 79-year-old male presented with the left hilar/parahilar mass lesion which was pathologically proved to be adenocarcinoma grade 2. **A** MIP images of the PET/CT. **B** and **C** Coronal and axial images showing the left hilar/parahilar lesion with SUVmax 6, MTV 12 and the TLG was 72.8 g/ml. No metabolically active regional nodal or distant metastatic deposits. The patient was managed by immunotherapy and referred for follow-up after 3 months. **D, E, F** The post-therapy images showing complete resolution of the previously noted left hilar/parahilar lesion

Regarding the N stage of bronchogenic carcinoma; significant differences were seen in SUVmax and TLG between N0 and N, N2 stages with P value 0.01, significant differences were seen in MTV in N stage with P value 0.05 (Fig. 4).

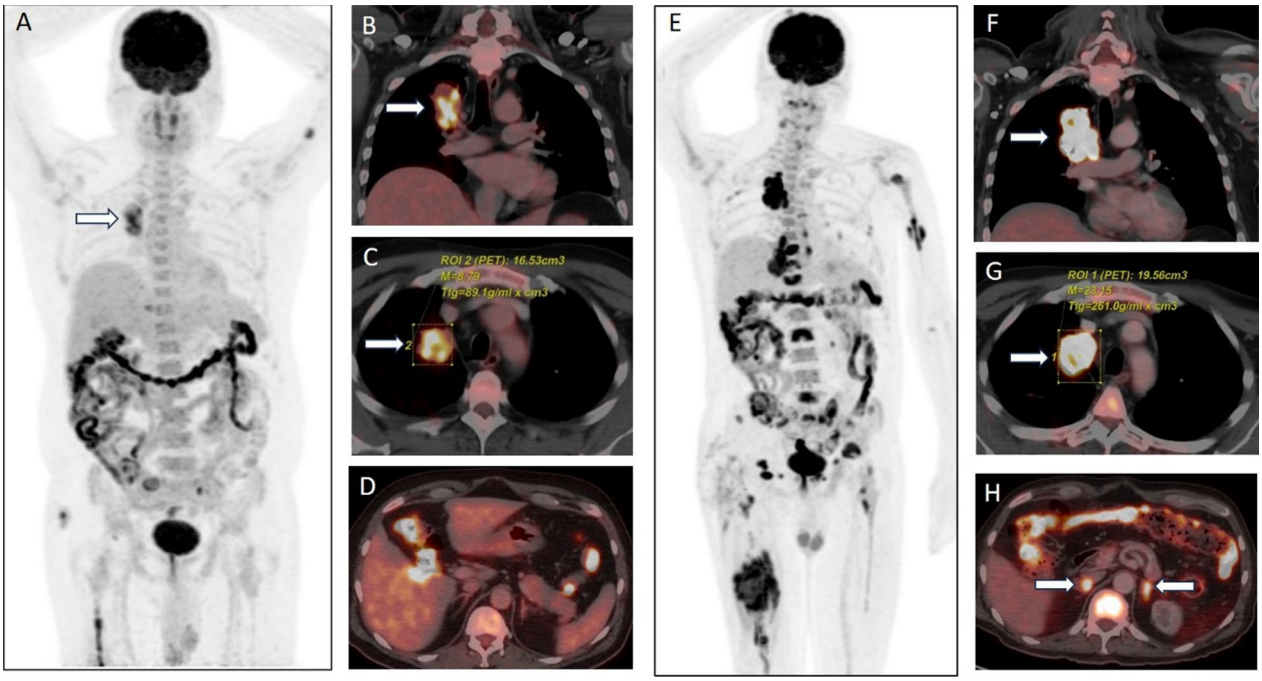

Fig. 4 A 58-year-old male patient presented with the right parahilar lesion **A, B** which was pathologically proved to be bronchogenic carcinoma (adenocarcinoma, grade 4). **C** The lesion shows high metabolic tumor parameters where the SUVmax was 19.6, MTV 13.3 ml and the TLG was 261 g/ml. **D** MIP images show multiple hypermetabolic lesions seen in the axial and appendicular skeleton indicating osseous metastases. **E** MIP image of the PET/CT showing multiple newly developed bony deposits. **F** and **G** are coronal and axial PET/CT fused images showing progressive course of the lung mass. **H** Axial PET/CT fused images showing newly developed metastatic bilateral adrenal deposits

Regarding the M stage of bronchogenic carcinoma; significant differences were seen in SUVmax and TLG between M0 and M1 stage with P value 0.01 and 0.02, respectively. Insignificant difference was seen in MTV in M stage with P value 0.13 (Fig. 6).

ROC curve for ability of SUVmax, TLG and MTV for differentiation of tumor grades (high grade vs low/intermediate grade) (Fig. 1) and stage (stage 3a/4b vs stage 1a), (Fig. 2) showed significant correlation and increase in sensitivity and the different measured PET/CT parameters with different tumor grades and stages.

The optimal cut-off value of different PET/CT parameters in differentiating between different tumor grades was ≥ 9 for SUVmax with sensitivity 92% and specificity 100%, ≥ 138.5 for TLG with sensitivity 92.3% and specificity 100% and ≥ 22.15 for MTV with sensitivity 84.6% and specificity 100% (Table 7).

Discussion

PET/CT is a multimodality radiological imaging procedure that combines both structural anatomical and metabolic imaging information that recently has been highly recommended for proper diagnosis, staging and accurate posttreatment evaluation of lung cancer [12].

^{18}F-FDG is considered recently the most commonly used molecular radio-active tracer which can efficiently reflect the metabolic activity, tumor cellular proliferation and tissue perfusion [12].

In the current study, we evaluated the variable volumetric and metabolic parameters, such as SUV, TLG and MTV of ^{18}F-FDG PET/CT in initial staging of different lung cancer cases and predict their correlated values impact on the prognostic pathway because some of the cases were not valid for follow-up studies, and our main aim was to initially study the different metabolic and volumetric values in different aspects of bronchogenic carcinoma; however, some of the cases were under follow up and showed significant correlation between different volumetric and metabolic values and disease prognosis.

In addition, we have expressed in our study the application of different volumetric and metabolic parameters of ^{18}F-FDG PET/CT in assessing the TNM staging of different lung cancers in which we found that there were highly significant differences in volumetric parameters including TLG and SUVmax in-between the different grades, T stages and pathological stage of bronchogenic carcinoma as well as the tumor pathological staging and grading, in which we found that low volumetric and

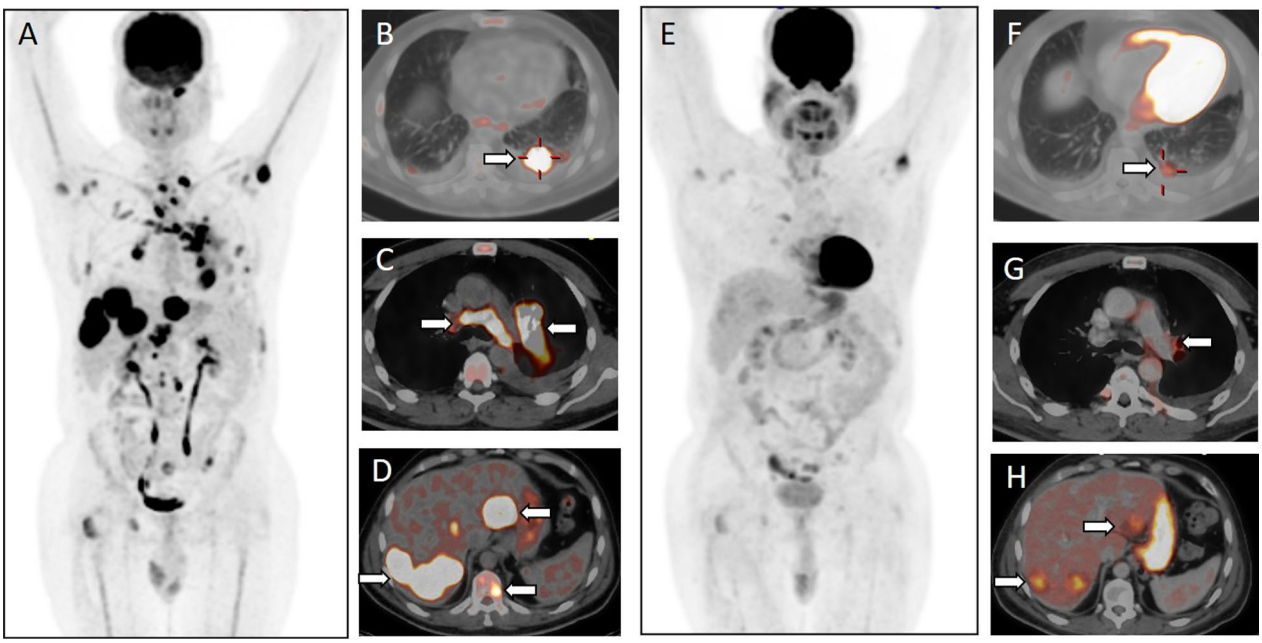

Fig. 5 A 45-year-old male patient presented with the left lower lung lobe hypermetabolic lesion which was pathologically proven as bronchogenic carcinoma (grade 2). **A** Whole-body PET-MIP image and **B** axial fused image showing the left lower lung lobe neoplastic lung mass with SUVmax 7, MTV 14.7 ml and TLG reaching 90 g/ml. **C** Axial fused image showed enlarged hypermetabolic metastatic left hilar and mediastinal lymph nodes. **D** Axial fused image showed multiple metastatic bi-lobar hepatic focal lesions as well as osseous vertebral body deposit. The patient received chemotherapy and was referred for follow-up after 3 months. The new scan revealed significant regressive course of the primary pulmonary mass **E** and hepatic deposits **F** as well as resolution of the infiltrated lymph nodes **G** and vertebral osseous deposits **H** reflecting favorable response to therapy

metabolic values are compatible with low tumor staging, and high parameters are consistent with higher disease staging. Ivayla Apostolova et al. [13] proved in their study that MTV and SUVmax were significantly correlated with T and N stages in NSCLC.

A retrospective analytical study has been conducted by Li et al. [14] on 107 NSCLC cases and showed that there is correlation between high SUVmax values and tumor stage.

Wei D Hu et al. [15] found that TLG and MTV had positive correlation with adenocarcinoma staging, and only MTV has positive correlation with different stages of squamous cell carcinoma.

Lee et al. [16] evaluated NSCLC prognosis using MTV, through analysis of 19 cases of lung cancer patients (stage I–stage IV) in which TNM stages were positively affected by different metabolic and volumetric parameters of ^{18}F-FDG PET/CT.

Our findings are consistent with other prior studies, in which higher metabolic parameters values are significantly associated with high disease stage.

Lee et al. [16] proved the significant prognosis of MTV values in 19 NSCLC cases and were almost similar to our results, in which they found that MTV higher values were associated with higher disease staging.

In the current study, no significant differences were found in the values of volumetric and metabolic parameters (SUVmax, MTV and TLG) in correlation to difference histopathological bronchogenic carcinoma subtypes, which could be attributed to the small sample volume or true non-existing valuable differences.

The results of differences in volumetric and metabolic parameters of PET/CT imaging among different pathological bronchogenic carcinoma types are not consistent. Some studies have stated that there is no significant difference in SUVmax among different histopathological subtypes of bronchogenic carcinoma (AC, SCC and small cell lung cancer) [17].

Wei et al. [15] proved that TLG, SUVmax and MTV values were higher in squamous cell carcinoma than in adenocarcinoma.

Zhang et al. [12] conducted a study including 94 cases and stated the significant differences in values of volumetric and metabolic parameters between squamous cell carcinoma and adenocarcinoma subtypes of bronchogenic carcinoma.

Table 6 Relation between MTV and histopathological criteria of tumor

		MTV		Test value	*P* value
		Mean	SD		
Side	Right	28.62	11.58	1.81*	0.09
	Left	18.02	10.23		
Site	Upper lobe	23.30	11.62	2.28*	0.06
	Middle/lower lobe	35.34	8.70		
Histopathological grade	Grade 2	16.70[a]	8.23	9.95**	0.002
	Grade 3	34.36[b]	1.07		
	Grade 4	33.92[b]	10.03		
Histopathology	Adenocarcinoma	26.28	12.10	0.37*	0.72
	Other types	23.46	13.41		
T staging	T1/T2	15.63	6.24	3.72*	0.002
	T3/T4	31.79	10.39		
LN	Negative	20.28	10.47	2.09*	0.05
	Positive	30.83	11.41		
M staging	M0	22.23	10.39	1.60*	0.13
	M1	30.78	12.85		
Pathological stage	1a3	13.51[a]	3.04	8.71**	0.003
	3a	32.70[b]	2.75		
	4b	30.78[b]	12.85		
Grade (cell diff)	Low (well differentiated)	14.52[a]	2.13	8.72**	0.003
	Intermediate (moderately differentiated)	11.50[a]	4.53		
	High (poorly differentiated)	31.52[b]	9.99		

* Student's t-test **One-way ANOVA test (a,b: post hoc test)

It is well known that status of hyperglycemia reduces ^{18}F-FDG uptake and, hence, tumor SUV, so, all patients were strictly requested to be fasting for more than 4 h in this study to keep the blood glucose concentration controlled at 4.10–7.80 mmol/L, in which different metabolic and volumetric parameters were not affected by the blood glucose concentration.

In a meta-analytical study of 5807 patients, Liu et al. [18] stated that higher values of TLG, SUVmax and MTV can predict higher disease recurrence risk in NSCLC patients, and they recommended the use of 18F-FDG PET/CT for selection of patients with higher disease recurrence risk that can benefit from additional treatment regimen.

In our study, there was significant valuable difference in TLG, SUV and MTV values regarding the prognostic predictive values in some cases of bronchogenic carcinoma (Figs. 1 and 3), and this was matching with the results of a study conducted by Mohammad et al. [19] who stated a statistically significant correlation between the overall survival time and volumetric FDG PET/CT semi-quantitative parameters, such as distant metastasis and metastatic regional lymph node based mainly on TLG, SUVmax or MTV value.

Recently, several studies have stated that the prognostic predictive value of TLG and MT is better than that of SUVmax, such as Ohri N et al. [20] who conducted a study upon 214 patients of stage III NSCLC and proved that MTV was an independent tumor prognostic predictor value. M Dosani et al. [21] performed a study of 134 NSCLC patients and found that MTV and TLG were significant values in predicting the disease prognosis more than SUVmax. Liao et al. [22] studied the prognostic value of the metabolic tumor burden in nonsurgical NSCLC cases and stated that FDG PET/CT semi-quantitative parameters are independent prognostic values of the clinical stage with low interobserver variability and can be used for further stratification of nonsurgical NSCLC patients. They also stated that TLG and MTV are better prognostic measures than SUVmax and SUVmean. Zaizen et al. [23] evaluated the prognostic significance of TLG in advanced NSCLC cases post-chemotherapy status and reported that TLG can be more beneficial than SUVmean and SUVmax in predicting the overall NSCLC survival and recommended routine TLG measurement in FDG-PET imaging in patients with advanced NSCLC status.

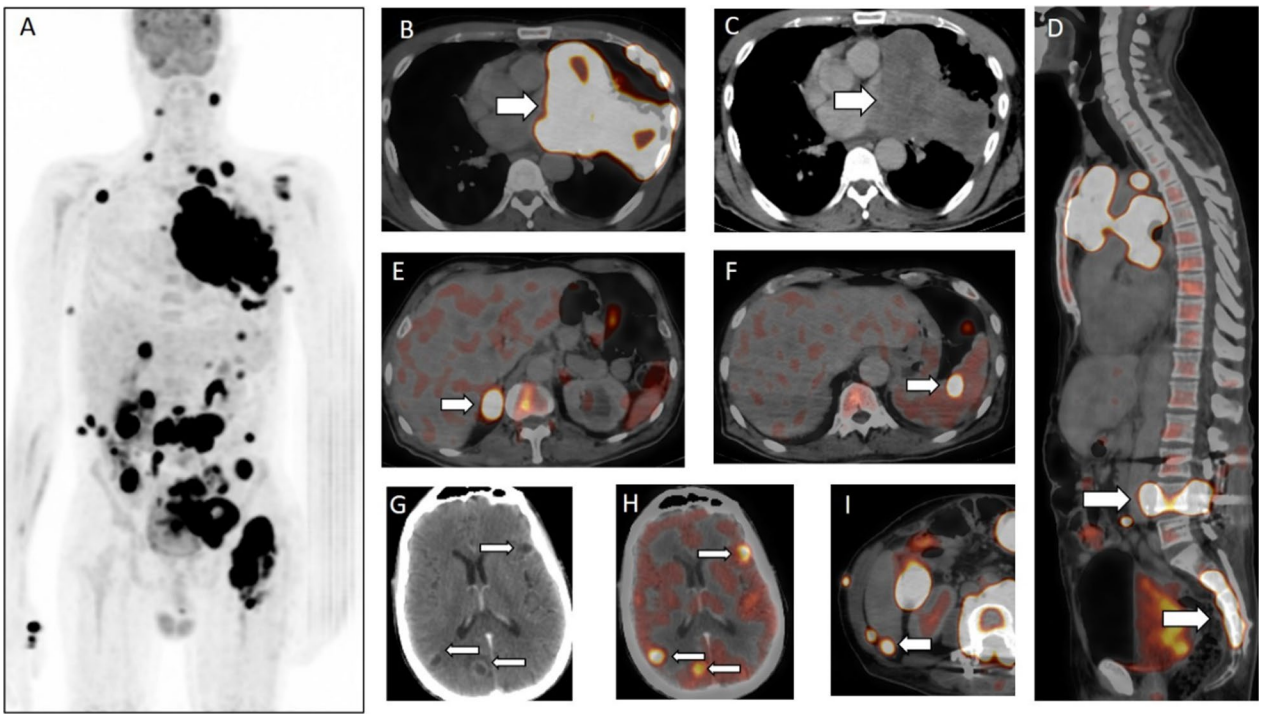

Fig. 6 A 56-year-old male patient presented with recently diagnosed pulmonary mass lesion which was pathologically proven bronchogenic carcinoma (grade 4). A large hypermetabolic left upper lobe pulmonary mass is noted extending from lateral pleural surface laterally and merging medially with enlarged left hilar and mediastinal lymph nodes. The SUVmax was 15, MTV was 47.4 ml and the TLG reaching 650 ml. The MIP images and the other images show multiple hypermetabolic metastatic nodal, left pleural, cerebral, splenic, osseous, right adrenal, peritoneal and subcutaneous nodules (the top images; **A**–**D**). The corresponding CT images (the bottom images; **G**–**I**) showed cerebral ring enhancing deposit, the pulmonary neoplastic mass and the paravertebral metastatic deposit. **D** Sagittal fused PET/CT image showing bony metastasis affecting L4 vertebra and sacrum. **E**, **F** Axial fused PET/CT images showing right adrenal and splenic deposits respectively. **G** Axial brain CT, **H** Axial fused PET/CT showing hypermetabolic cerebral ring enhancing deposits. **I** Axial fused PET/CT image showing hypermetabolic peritoneal and subcutaneous nodules

The current study had some limitations including retrospective structure and relatively small sample volume of 40 patients, for that small numbers of cases within each stage, we could not sufficiently stratify our analysis by individual stage, and we performed logistic analytical adjustment for stage, age and different volumetric and metabolic parameters. We used the segmentation algorithms from single commercial software workstations vendor for image analysis, and therefore, multiple vendor-provided segmentation algorithms are to be investigated in the future for similar structural studies.

Table 7 Best cut-off values, sensitivity and specificity of SUVmax, TLG and MTV parameters

Parameter	Best cut-off value	Sensitivity (%)	Specificity (%)
SUVmax	≥ 9.00	92	100
TLG	≥ 138.50	92.3	100
MTV	≥ 22.15	84.6	100

Further studies with a larger population sample volume are recommended for proper results validation and also further studies for correlation between different metabolic and volumetric parameters prognostic values in correlation to follow up studies are recommended.

Conclusions

PET/CT-based metabolic and volumetric parameters with gradient-based segmentation including SUV, MTV and TLG are potential diagnostic values that can efficiently provide a proper evaluation parameters of bronchogenic carcinoma lesions burden that can be measured both in primary tumors as well as metabolically active metastatic lesions throughout the whole-body imaging protocols. Although standardized methods for their measurements are still required, these metabolic- and volumetric-based parameters can be very promising sufficient prognostic factors. They can identify different risk levels in TNM stages thus providing an excellent tool for further characterization of different cases and hence

allowing specific tailored therapeutic protocols for each individual cases accordingly.

Abbreviations

AC	Adenocarcinoma
FDG	Fluorodeoxyglucose
MAX	Maximum
MIN	Minimum
MIP	Maximum intensity projection
MTV	Metabolic tumor volume
NSCLC	Non-small cell lung cancer
PACS	Picture archiving and communication system
PET/CT	Positron emission tomography/computed tomography
RECIST criteria	Response evaluation criteria in solid tumor
ROC	Receiver operator characteristic curve
SCC	Squamous cell carcinoma
SD	Standard deviation
SUV	Standardized uptake value
SUVmax	Maximum standardized uptake value
SUVmean	Mean standardized uptake value
TLG	Total lesion glycolysis

Acknowledgements
This research was carried out at Kings College Hospital, Dubai, which is fully equipped by dedicated machines for proper breast imaging. We want to thank our colleagues who helped us to do such research work.

Author contributions
N.T. contributed to conception, design, interpretation of data and drafted the manuscript; Y.O. contributed to interpretation of data and cases collection and M.E. drafted and revised the manuscript critically for important intellectual content and approved the final version for submission and publication. All authors have read and agreed with the published version of the manuscript.

Funding
No funding sources.

Availability of data and materials
The datasets used and analyzed during the current study are available from the corresponding author on reasonable request.

Declarations

Ethics approval and consent to participate
The protocol was reviewed and approved by the local ethical committee of "Research Ethics Committee at the Faculty of Medicine, Ain Shams University." It ruled that no formal ethics approval was required in this retrospective study, and so, no reference number was given by the IRB.

Consent for publication
This research is based on retrospective study; yet, written consent for publication was obtained for these cases.

Competing interests
No financial or non-financial competing interest.

Received: 7 August 2023 Accepted: 30 January 2024
Published online: 19 February 2024

References

1. Ferlay J, Soerjomataram I, Dikshit R et al (2015) Cancer incidence and mortality worldwide: Sources, methods and major patterns in GLOBOCAN. Int. J. Cancer 136:359–386
2. Cheng G, Huang H (2018) Prognostic value of (18)F-fluorodeoxyglucose PET/computed tomography in non-small-cell lung cancer. PET Clin 13:59–72
3. Toloza EM, Harpole L, Detterbeck F (2003) Invasive staging of non-small cell lung cancer: A review of the current evidence. Chest 123:157S-166S
4. Kandathil, A., Kay, F.U., Butt, Y.M. et al. Role of FDG PET/CT in the Eighth Edition of TNM staging of non-small cell lung cancer. *Radiographics* **2018**, *38*, 2134–2149.
5. Greenspan BS (2017) Role of PET/CT for precision medicine in lung cancer: Perspective of the society of nuclear medicine and molecular imaging. Transl Lung Cancer Res 6:617–620
6. De Ruysscher D, Kirsch CM (2010) PET scans in radiotherapy planning of lung cancer. Radiother Oncol 96:335–338
7. Konert T, van de Kamer JB, Sonke JJ et al (2018) The developing role of FDG PET imaging for prognostication and radiotherapy target volume delineation in non-small cell lung cancer. J Thorac Dis 10:S2508–S2521
8. Chung HW, Lee KY, Kim HJ et al (2014) FDG PET/CT metabolic tumor volume and total lesion glycolysis predict prognosis in patients with advanced lung adenocarcinoma. J Cancer Res Clin Oncol 140:89–98
9. Obara P, Pu Y (2013) Prognostic value of metabolic tumor burden in lung cancer. Chin J Cancer Res 25:615–622
10. Sharma A, Mohan A, Bhalla AS et al (2018) Role of various metabolic parameters derived from baseline 18F-FDG PET/CT as prognostic markers in non-small cell lung cancer patients undergoing platinum-based chemotherapy. Clin Nucl Med 43:8–17
11. Berghmans T, Dusart M, Paesmans M et al (2008) Primary tumor standardized uptake value (SUVmax) measured on fluorodeoxyglucose positron emission tomography (FDG-PET) is of prognostic value for survival in non-small cell lung cancer (NSCLC): A systematic review and meta-analysis (MA) by the European Lung Cancer Working Party for the IASLC Lung Cancer Staging Project. J Thorac Oncol 3:6–12
12. Lixia Z, Zhe RC, Xu Q et al (2021) Value of ^{18}F-FDG PET/CT metabolic and volumetric parameters in non-small cell lung cancer. Int J Gen Med 14:3699–3706
13. Apostolova I, Ego K, Steffen IG et al (2016) The asphericity of the metabolic tumour volume in NSCLC: correlation with histopathology and molecular markers. Eur J Nucl Med Mol Imaging 43(13):2360–2373. https://doi.org/10.1007/s00259-016-3452-z
14. Li M, Liu N, Hu M et al (2009) Relationship between primary tumor fluorodeoxyglucose uptake and nodal or distant metastases at pre- sentation in T1 stage non-small cell lung cancer. Lung Cancer 63(3):383–386. https://doi.org/10.1016/j.lungcan.2008.06.004
15. Hu WD, Wang HC, Wang YB et al (2019) Correlation study on 18F-FDG PET/CT metabolic characteristics of primary lesion with clinical stage in lung cancer. Quart J Nuclear Med Mol Imaging 65(2):172–177
16. Lee P, Weerasuriya DK, Lavori PW et al (2007) Metabolic tumor burden predicts for disease progression and death in lung cancer. Int J Radiat Oncol Biol Phys 69(2):328–333. https://doi.org/10.1016/j.ijrobp.2007.04.036
17. Ha S, Choi H, Cheon GJ et al (2014) Autoclustering of non-small cell lung carcinoma subtypes on (18) F-FDGPET using texture analysis: preliminary result. Nucl Med Mol Imaging. 48(4):278–286. https://doi.org/10.1007/s13139-014-0283-3
18. Liu J, Dong M, Sun X et al (2016) Prognostic value of 18F-FDG PET/CT in surgical non-small cell lung cancer: a meta-analysis. PLoS ONE 11:e0146195
19. Shadmehr MB, Khosravi A, Dezfouli AA, Bakhshayesh-Karam M, Jamaati H, Doroudinia A, Dorudinia A (2020) Clinical significance of quantitative FDG PET/CT parameters in non-small cell lung cancer patients. Tanaffos 19(3):186
20. Ohri N, Duan F, Machtay M et al (2015) Pretreatment FDG-PET metrics in stage III non-small cell lung cancer: ACRIN 6668/RTOG 0235. J Natl Cancer Inst. 107(4):004. https://doi.org/10.1093/jnci/djv004
21. Dosani M, Yang R, McLay M et al (2019) Metabolic tumour volume is prognostic in patients with non-small-cell lung cancer treated with stereotactic ablative radiotherapy. Current Oncol 26(1):e57–e63. https://doi.org/10.3747/co.26.4167
22. Liao S, Penney BC, Wroblewski K et al (2012) Prognostic value of metabolic tumor burden on 18F-FDG PET in nonsurgical patients with non-small cell lung cancer. Eur J Nucl Med Mol Imaging 39(1):27–38

23. Zaizen Y, Azuma K, Kurata S et al (2012) Prognostic significance of total lesion glycolysis in patients with advanced non-small cell lung cancer receiving chemotherapy. Eur J Radiol 81(12):4179–4184

Publisher's Note