Patil *et al. Egypt J Radiol Nucl Med (2024) 55:59*
https://doi.org/10.1186/s43055-024-01229-8

Egyptian Journal of Radiology
and Nuclear Medicine

CASE REPORT **Open Access**

Imaging in a rare case of cerebral phaeohyphomycosis caused by *Cladophialophora bantiana* in a renal transplant patient: a case report and the literature review

Pushpak N. Patil[1,3*], Rajendra Chavan[2] and Shivani S. Borse[1]

Abstract

Background Cerebral phaeohyphomycosis is a rare and potentially life-threatening fungal infection caused by dematiaceous fungi (Levin TP et al. in J Clin Microbiol 42(9):4374–4378, 2004). It may occur in both immunocompetent and immunodeficient individuals, with a relatively higher incidence in the former (Revankar SG et al. in J Trop Med Hyg 38(1):206–222, 2004). A search of the Pubmed and Google Scholar databases revealed seven cases of cerebral phaeohyphomycosis in renal transplant patients caused by *Cladophialophora bantiana* (*C. bantiana*).

Case presentation A 35-year-old male patient who had undergone a renal transplant presented with fever, imbalance while walking, and focal seizures involving the right lower limb. Magnetic Resonance Imaging (MRI) of the brain showed two lesions in the cerebral hemispheres. Craniotomy with excision of the lesion was done. The Periodic Acid Schiff (PAS) stain and the tissue culture on the Sabouraud dextrose agar suggested *C. bantiana*. The broad-spectrum antifungal drugs were started. However, the patient deteriorated in the subsequent follow-ups and eventually died of the disease.

Conclusions We present a detailed report on the imaging characteristics of a rare fungal brain abscess caused by *C. bantiana*, which is the first case of its kind (refer to Table 1). In immunodeficient cases, intracranial pathologies can encompass a wide range of conditions, from infections to neoplasms, which often exhibit significant imaging overlap. In such a setting, the remote possibility of phaeohyphomycosis is easy to miss clinically and imaging-wise. MRI can narrow down the differential diagnosis and raise suspicion. In every suspicious case, it is of the utmost importance to correlate with the histopathology and the culture reports to initiate the prompt targeted therapy and avoid a fatal outcome. Complete excision of the abscess and antifungal agents like Voriconazole and Posaconazole are the mainstay of management in these patients.

Keywords Cerebral phaeohyphomycosis, Renal transplant, *Cladophialophora bantiana*, Concentric target appearance

*Correspondence:
Pushpak N. Patil
pupatil08@gmail.com
Full list of author information is available at the end of the article

Background

Renal transplantation is one of the most frequently performed procedures worldwide. However, the administration of immunosuppressive agents, while essential for the success of the transplant, may create a conducive environment for the emergence of opportunistic infections [1]. This report presents an infrequent case of cerebral abscess caused by *Cladophialophora bantiana*, a fungus known to infect immunocompetent hosts more frequently than immunocompromised ones [2]. In the latter, intracranial pathologies can encompass a wide range of conditions, from infections to neoplasms, which often exhibit significant imaging overlap. In this context, phaeohyphomycosis, which closely mimics other common infections and neoplasms, may be overlooked clinically and radiologically despite its potential impact on morbidity and mortality.

Case presentation

A male patient, aged 35 years, underwent renal transplantation in May 2012 due to renal failure caused by long-standing hypertension and diabetes mellitus. In September 2020, 8 years post-transplantation, he presented with focal seizures affecting the right lower limb, fever, and gait imbalance.

MRI of the brain showed two lesions at the gray-white matter interface of the left high parietal and right frontal lobes with associated adjacent vasogenic edema (Fig. 1). Both the lesions appeared hypointense on the T2 weighted images (T2WI), T1 weighted images (T1WI), and the FLAIR images (Fig. 1). The left parietal lesion showed multiple intra-lesional hypointense projections from the wall on T2WI (Fig. 1a). The wall also appeared hypointense on T2WI. The wall showed crenations and a few lobulations as well. The apparent diffusion coefficient maps (ADC maps) showed hypointense signal involving the wall of the lesion but not in the core (Fig. 1b). The T1W fat-saturated post-contrast study (T1FS C+) showed peripheral enhancement involving the wall with a central non-enhancing core (Fig. 1d). The blooming artifact was noted at the periphery on the susceptibility-weighted images (SWI) in the right frontal lesion (Fig. 1g).

Single-voxel ^{1}H-MRS demonstrated a lipid lactate peak (1.3 parts per million [ppm]) with a maintained N acetyl aspartate (NAA) peak. The peaks were also noted at

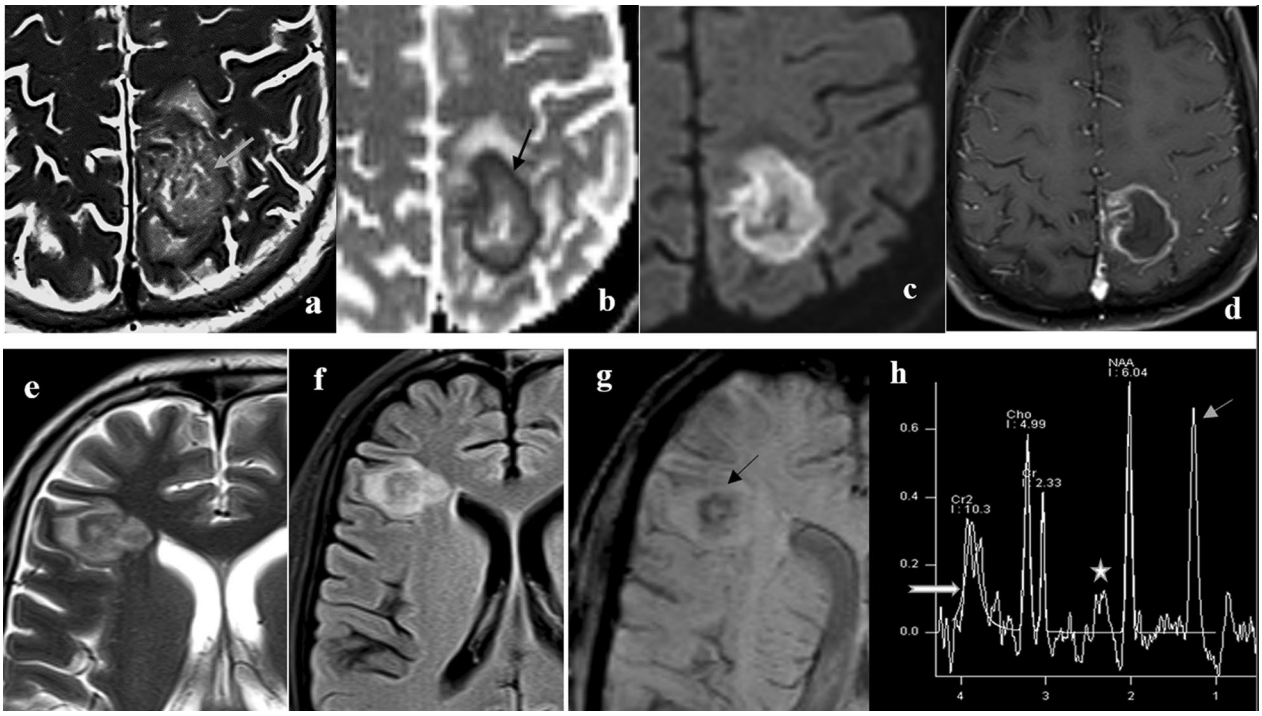

Fig. 1 **a–d** show left high parietal lesion. Multiple intra-lesional hypointense projections from the wall are noted on the axial T2WI (**a**). These projections do not show hypointensity on the ADC maps (**b**) or enhancement on the T1FS C+ images (**d**). Axial ADC map (**b**) shows hypointense signal involving the wall of the abscess. Axial DWI (**c**) shows hyperintense signal involving almost the entire lesion. T1FS C+ **d** shows peripheral enhancement. **e**–**g** show right frontal lesion. It appears iso-hypointense to the grey matter on axial T2WI (**e**) and FLAIR images (**f**) with surrounding vasogenic edema. Peripheral blooming artifacts are noted on the SWI (**g**). Single voxel ^{1}H-MRS (**h**) shows an elevated lipid lactate peak at 1.3 ppm (white arrow) with a maintained NAA peak. The peaks are also noted at 2.4 ppm (star), 3.2 ppm, and 3.6 ppm (notched arrow), consistent with the succinate, choline, and trehalose metabolites, respectively

2.4 ppm, 3.2 ppm, and 3.6 ppm, consistent with the succinate, choline, and trehalose metabolites, respectively (Fig. 1h). Based on the imaging findings, the possibility of infective etiology, likely a fungal abscess, was raised.

The CSF examination was insignificant. Cytomegalovirus—PCR was positive, and a low CD4 count of 115 was noted. Hence, the patient was started on the antiviral drugs and the Cotrimoxazole.

The patient's symptoms did not improve with the antiviral drugs. A left parietal craniotomy and excision of the lesion was performed in November 2020. Intraoperatively, a grayish-black friable mass with a thick wall was seen (Fig. 2a). Examination with special stains like PAS revealed brownish-pigmented, slender, septate fungal hyphae with occasional globose swelling resembling phaeohyphomycosis (Fig. 2b). The tissue culture on the Sabouraud dextrose agar at 37 degrees Celsius after 12 days showed grayish-black velvety colonies, confirming *C. bantiana*. Upon diagnosis, treatment with the Tab. Voriconazole was started. The patient's symptoms were alleviated, and he was discharged.

In January 2021, he again presented with fever, chills, headache, and vomiting. A follow-up MRI of the brain showed progression of both lesions (Fig. 3a–c). The patient was managed conservatively and discharged.

Seven weeks after that, he developed a high-grade fever and pus discharge from the operative site. A follow-up MRI of the brain (Fig. 3d–f) showed further progression. The abscess, along with the infected parietal bone, was removed. After the excision, the patient's clinical condition improved.

After 4 weeks, there was a deterioration in the patient's clinical condition. Brain MRI showed multiple areas of acute cerebral infarcts, increased mass effect, and a midline shift. A change in the imaging morphology of the right frontal lesion was seen, giving a "concentric target appearance" (Fig. 4a) on T2WI closely mimicking the neuro-toxoplasmosis (discussed below). Four days after the scan, the patient expired. For a summary of imaging findings, please refer to Table 1.

Discussion

The term "phaeohyphomycosis" or "dematiaceous" is used to describe the fungal infections caused by pigmented fungi [3]. Dematiaceous fungi, such as Cladophialophora, Rhinocladiella, Curvularia, and others, are known to cause central nervous system (CNS) disease, exhibiting distinct neurotropism. The CNS infection can also be a part of the disseminated process. Alternaria, Curvularia, Exophiala, Lomentospora, and others are the organisms associated with disseminated disease [4]. Due to their high melanin content, these fungi typically show dark-pigmented filamentous hyphae on histopathological examination. Melanin serves as a barrier against

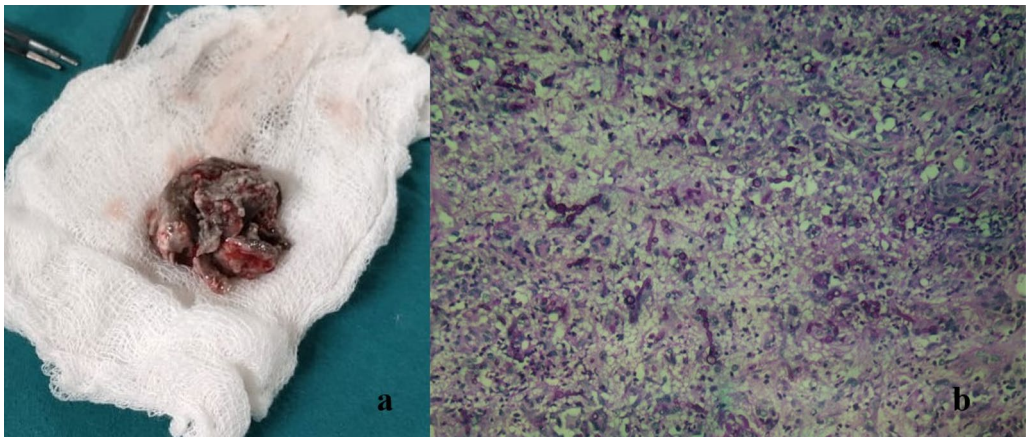

Fig. 2 The gross specimen of the greyish-black friable mass, **a** excised from the left parietal lobe, measuring 4 × 4 cm in size. The PAS stain **b** reveals brownish-pigmented, slender, septate fungal hyphae with occasional globose swelling resembling Phaeohyphomycosis in the background of large areas of necrosis and the dense infiltrate of neutrophils, lymphocytes, and the multinucleated giant cells

(See figure on next page.)

Fig. 3 **a**–**c** are the follow-up images done 3 months after the 1st scan. Coronal T2WI (a) and axial FLAIR images (b and c) show lesions that have increased in size compared to the initial imaging. Perilesional vasogenic edema has also increased. **d**–**f** are the follow-up images done 4 months after the previous scan. Coronal T2WI (**d**) and axial FLAIR images (**e**, **f**) at the same levels show a further increase in the size of the lesions and the mass effect. The lesion involves the left half of the splenium of the corpus callosum and the periventricular white matter. Perilesional vasogenic edema has increased

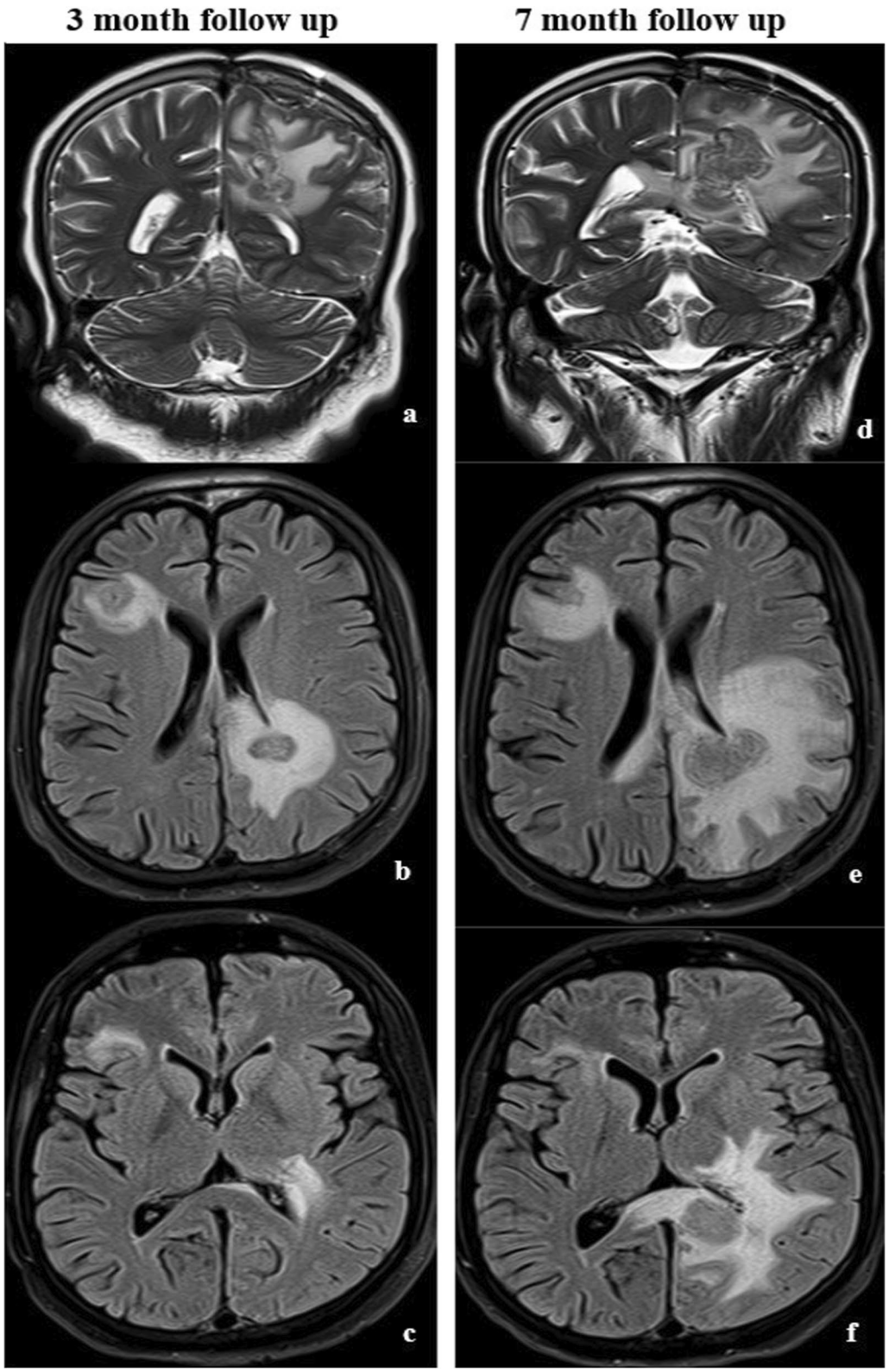

Fig. 3 (See legend on previous page.)

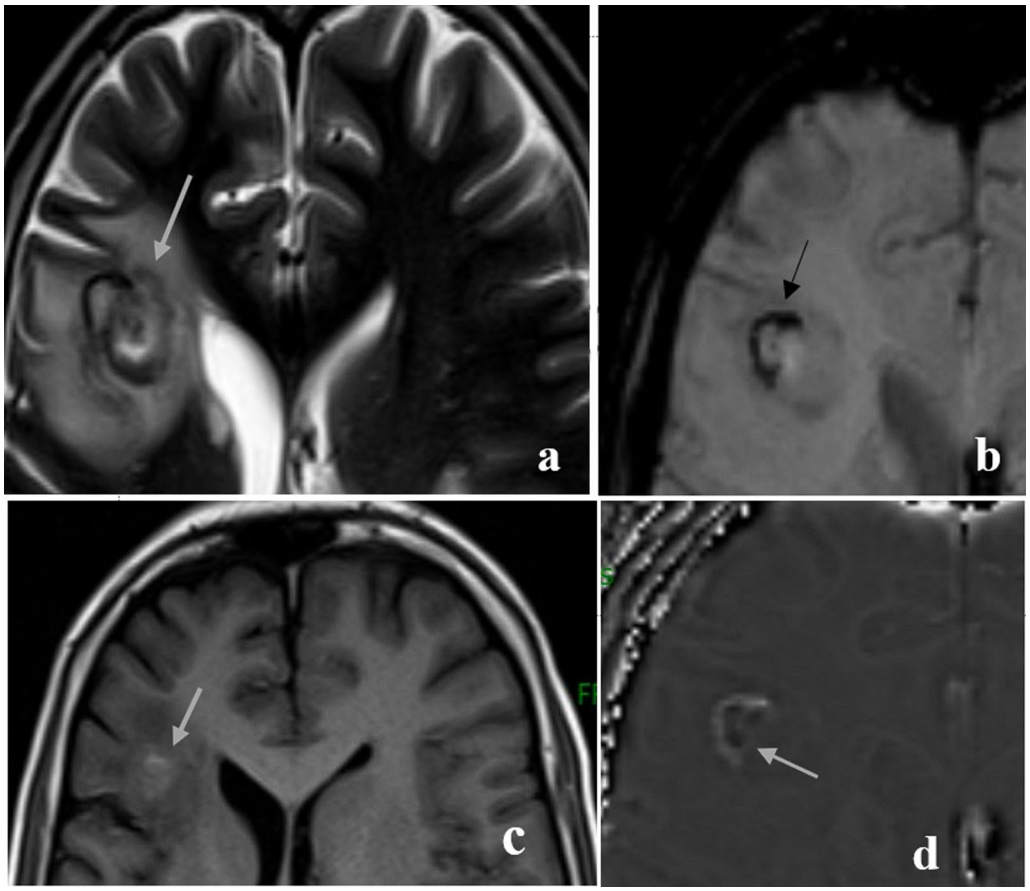

Fig. 4 The follow-up at the 8th month (4 weeks after the previous follow-up): Axial T2WI **a** shows changed morphology of the right frontal lesion, giving typical "concentric target appearance" closely mimicking toxoplasmosis (white arrow). Axial T1WI **c** shows hyperintense signal in the right frontal lesion (white arrow). Blooming artifacts are noted at the periphery on SWI (**b**: black arrow) but not in the region of T1W hyperintensity. Central T1W hyperintense signal shows hypointensity on the Phase Gradient images (**d**), suggesting that the T1W hyperintensity is not due to the blood products. Peripheral blooming artifact on SWI (**b**), shows a hyperintense signal on the phase gradient image (**d**) and hypointense signal on T2WI (**a**), suggesting the blood products

Table 1 Highlights of the imaging findings in *Cladophialophora bantiana* cerebral abscess

Highlights of the imaging findings in *Cladophialophora bantiana* cerebral abscess	
T2W images	"Concentric target appearance" Marked hypointensity Extensive intra-cavitary hypointense projections from the abscess wall that do not show low ADC or post-contrast enhancement
T1W images	Hypointense or Hyperintense (attributable to the rich "melanin content" within their cells and/or the blood products)
DWI/ADC maps	Restricted diffusion involving the wall of abscess with a hypointense signal on ADC maps No intra-cavitary signal drop on the ADC maps
^{1}H-MRS	Elevated lipid-lactate peak Maintained NAA peak Elevated trehalose, choline, and succinate peaks

the host's oxidative killing mechanism and offers resistance to the entry of antifungal drugs [5]. These fungi are abundantly found in the soil, thereby making inhalation a likely portal of entry into the human body and colonization into the lungs. They can then spread to the brain, resulting in multiple abscesses [2].

We comprehensively searched the Pubmed and Google Scholar databases using relevant keywords such as 'cerebral phaeohyphomycosis', '*C. bantiana*', 'renal transplant', 'fungal brain abscess', etc. We did not limit the search to any specific time frame and also explored the references cited in these articles to identify additional cases. Our inclusion criteria were renal transplant patients who had been histopathologically diagnosed with cerebral phaeohyphomycosis. This accounted for 17 cases, of which seven were caused by *C. bantiana*, with the current case under discussion being the 8th (Table 2).

Of the eight patients, 6 were males and 2 were females. 37.5% (3 of 8) expired; all were male patients. The average age of the patients was 46.625 years (range: 35–75 years). The median time to the detection of a *C. bantiana* cerebral abscess after renal transplant was 59 months (range: 9 months–10 years). The most common presenting symptom was headache. The parietal lobe was the most common lobe to be involved. It was involved in 75% (6 of 8) cases. Recurrence was noted in three cases, including the current case. All underwent resection of the lesion. Two of them expired, including the present case. All the details are mentioned in the Table 2.

Atypical imaging features for a fungal abscess in our study

The current case depicts imaging findings resembling those typically observed in a fungal abscess [6–10], with a few exceptions. Notably, the central portions of the present case exhibited hypointensity in most of the T2WI (Fig. 1a, 3a, d). The seventh and eighth-month follow-ups revealed T1WI hyperintensity in the right frontal lesion (Fig. 4c), which did not display a blooming artifact on the SWI (Fig. 4b).

Prior studies have suggested that melanin is weakly diamagnetic and does not show hypointense signal on SWI [10, 11]. Also, melanin appears hyperintense on T1WI and hypointense on T2WI [13]. It is worth noting that all MRI scans were conducted on a "left-handed" Siemens 3 Tesla MRI machine. Therefore, it is plausible that the high melanin content within the cells of these fungi could be responsible for the hyperintense signal in the lesion on the T1W images. However, further research is necessary since different studies have reported varying findings regarding melanin [12, 13].

We present an atypical imaging presentation of the "concentric target appearance" in this patient at a later stage of the disease (Fig. 4a). This particular imaging appearance has not been previously associated with cerebral phaeohyphomycosis or any other fungal infection in the literature. It is, however, a typical appearance of "neurotoxoplasmosis" [14], characterized by alternate rings of iso-hypointense and hyperintense signals with adjacent vasogenic edema on the T2WI. Nevertheless, the unresponsiveness to the drug Cotrimoxazole, in our case, eliminates the possibility of neurotoxoplasmosis. In the case of patients with immunodeficiency, we must, therefore, be mindful of the possibility of this fungal abscess if a 'concentric target sign' presents itself. While this sign has historically been associated with neurotoxoplasmosis, it is imperative to distinguish between the two conditions as their treatment protocols differ significantly. For a summary of imaging findings, please refer to Table 1.

The recurrence is also common. The reasons could be incomplete or partial resection, the proximity of the abscess to the vital structures in the brain, multiple abscesses, the patients' clinical condition, etc. In our case, the primary concern was the proximity to the superior sagittal sinus and multiple abscesses. Therefore, the time is essential. The surgical excision must be done without delay before the lesion grows to the proximity or involves the brain's vital structures. Thus, MRI plays an important role in raising the suspicion of this fungal infection, which carries a high mortality rate and is often missed clinically.

The complete abscess excision and the long-term antifungal treatment are essential in managing these patients, according to the various studies published so far [2]. In their guidelines for the treatment of phaeohyphomycosis, the American Society of Transplantation Infectious Diseases Community of Practice [15] and the European Fungal Infection Study Group of the European Society of Clinical Microbiology and Infectious Diseases [16] recommend Amphotericin B, Posaconazole, and Voriconazole as the first-line drugs that should be considered over the other drugs.

Also, this being the 1st case report demonstrating in detail the imaging features of the *C. bantiana* cerebral abscess, it is not possible at this stage to illustrate the imaging differences of this abscess between the immunocompetent and the immunocompromised hosts. However, the critical imaging differences between the *C. bantiana* cerebral abscess, typical fungal abscess, tubercular abscess, and the pyogenic abscess on the MRI have been highlighted in Table 3 [17].

Conclusions

We present a case report of a rare *C. bantiana* brain abscess, outlining its imaging characteristics in detail. Immunocompromised patients often exhibit a spectrum of intracranial pathologies, ranging from infections to neoplasms, with significant overlap in their imaging presentations. In such cases, the possibility of phaeohyphomycosis can be easily missed clinically and through imaging. However, MRI can aid in narrowing down the differential diagnosis and raising suspicion.

Table 2 Summary of the histopathology-proven cases of Cladophialophora bantiana cerebral phaeohyphomycosis (CBCP) in renal transplant patients

Year (ref. no)	Age/sex	Renal failure cause	Immunosuppressant	The time between transplant & CBCP onset	Presenting symptoms	Site of lesion	Imaging described in the study	Other infections before or at the time of diagnosis of CBCP	Intervention	Anti-fungal	Follow up done at	Follow up findings	Management	Status
1997 [18]	35y/M	NA	NA	9 months	HA, GTCS, vomiting	Right parietal	CT-ring enhancing lesions	No	Biopsy	Amphotericin B	NA	NA	NA	NA
1997 [19]	36y/F	Microscopic angiitis/ crescentic nephritis	A, C, P	20 months	HA, left arm weakness	Right fronto-parietal	CT-ring enhancing lesions	Toxoplasmosis	Biopsy	Amphotericin B, flucytosine, itraconazole	12 months	Regression	No	Survived
1999 [20]	51y/M	Hypertension	A, P	10 years	HA, GTCS, vomiting	Left parietal	T1FS C+—ring enhancing lesion	No	Excision	Amphotericin B	3 weeks	No change	No	Survived
2003 [21]	61y/M	Adeno-Carcinoma of the kidney	A, C, P	7 years	Right arm weakness	Left parietal	CT-hypodense mass	Escherichia coli	Excision	Fluconazole, dexamethasone	1 month	Recurrence	Resection	Death
2016 [22]	49y/F	Crescentic glomerulone-phritis	T, M	3 years	HA, weakness, frequent falls	Left frontal	CT-hypodense mass	No	Excision	Posaconazole	6 months	Resolution	No	Survived
2018 [23]	40y/M	NA	NA	NA	HA, altered sensorium	Left frontal	CT-ring enhancing lesions	Toxoplasmosis	Biopsy	Amphotericin B, Flucytosine, Voriconazole	12th day	Massive bleed	No	Death
2020 [24]	65y/M	NA	NA	4 years	HA, visual loss	Left parieto-occipital	T1FS C+—ring enhancing lesion	No	Excision	Amphotericin B, Flucytosine,	NA	Recurrence	Resection	Survived
2021 (current)	36y/M	Diabetes, hypertension	T, P	8 years	Fever, imbalance while walking, focal seizures	Left parietal right frontal	Detail MRI with spectroscopy and long-term follow-up imaging	Covid-19, cytomegalovirus	Excision	Voriconazole	3rd month, 7th month, 8th month	Recurrence, progression, cerebral infarcts	Resection	Death

HA Headache, *GTCS* Generalized tonic–clonic seizures, *NA* Not available, *A* Azathioprine, *C* Cyclosporine, *P* Prednisolone, *T* Tacrolimus, *M* Mycophenolate mofetil, *CT* Computed tomography, *MRI* Magnetic resonance imaging, *T1FS C+* Fat suppressed T1 weighted post-contrast image

Table 3 MRI features of the typical fungal abscess, *C. bantiana* cerebral abscess, pyogenic abscess and the tubercular abscess [17]

	Fungal abscess	Cerebral phaeohyphomycosis	Pyogenic abscess	Tubercular abscess
DWI	Peripheral restricted diffusion	Peripheral restricted diffusion	Central restricted diffusion	Central restricted diffusion
SWI	Blooming artifacts may be present	Blooming artifacts may be present	No	No
Wall	Usually, crenated and lobulated	Crenated and lobulated	Usually smooth or lobulated	Usually smooth or lobulated
T1FS C+	Ring enhancement	Ring enhancement	Ring enhancement	Ring enhancement
T2W hypointense projections	Present	Present	Absent	Absent
T2W	–	Concentric target sign	–	–
T1W	Hypointense or hyperintense	Hypointense or *Hyperintense* (due to the rich melanin pigment and/or blood products)	Hypointense	Hypointense
MRS	Trehalose → 3.6 ppm Lipid-Lactate → 1.3 ppm	Trehalose → 3.6 ppm Succinate → 2.4 ppm Choline → 3.2 ppm Lipid-Lactate → 1.3 ppm	Amino acid → 0.9 ppm Succinate → 2.4 ppm Acetate → 1.9 ppm Lactate → 1.3 ppm Lipid-Lactate → 1.3 ppm	Lipid → 1.3 ppm

DWI Diffusion weighted image, *SWI* Susceptibility weighted image, *T1FS C+* T1W fat suppressed post-contrast image, *MRS* MR spectroscopy, *ppm* parts per million

Therefore, it is of utmost importance to correlate suspicious cases with histopathology and culture reports to promptly initiate targeted therapy and avoid fatal outcomes. When encountering the concentric target sign in an immunodeficient patient, it is essential to consider this fungal abscess as a critical differential diagnosis, in addition to the more common and typical neurotoxoplasmosis. Management of these patients involves complete excision of the abscess and antifungal agents, such as Voriconazole and Posaconazole, as the mainstay of treatment.

Abbreviations

MRI	Magnetic Resonance Imaging
T2WI	T2 weighted image
T1WI	T1 weighted images
T1FS C+	T1W fat suppressed post-contrast image,
ADC	Apparent diffusion co-efficient
SWI	Susceptibility weighted images
MRS	MR spectroscopy
1H-MRS	Proton MR spectroscopy
ppm	Parts per million
NAA	*N*-acetyl aspartate
PCR	Polymerase chain reaction
CNS	Central nervous system

Acknowledgements
The authors would like to thank Dr. Kala Kiruthiga for providing the histopathology image and Dr. Shama Shaikh for her assistance in writing.

Author contributions
All authors read and approved the final manuscript. PP: Conceptualization, writing original draft, methodology, formal analysis and investigation, reviewing and editing, data curation, visualization. RC: Supervision, validation, visualization, methodology, and data curation. SB: Resources, writing—reviewing and editing, data curation, writing the original draft.

Funding
No funding was received for conducting this study.

Availability of data and materials
The dataset used and/or analyzed during the current study is available from the corresponding author on a reasonable request.

Declarations

Ethics approval and consent to participate
Institutional Review Board approval was not required since this was a retrospective observational study. All measures to not disclose the identity of the patient were taken. Only limited sections of the images showing relevant findings were taken, hiding other imaging details.

Consent for publication
Written informed consent was obtained from the patient's relatives.

Competing interests
The authors declare that they have no competing interests.

Author details
[1]Department of Radiology, King Edward Memorial Hospital, Pune, Maharashtra, India. [2]Anushka MRI & CT Scan Center, King Edward Memorial Hospital, Pune, Maharashtra, India. [3]Department of Radiodiagnosis, Healthway Hospital, Old Goa, Goa 403 110, India.

Received: 19 September 2023 Accepted: 11 March 2024
Published: 25 March 2024

References

1. Levin TP, Baty DE, Fekete T, Truant AL, Suh B (2004) Cladophialophora bantiana brain abscess in a solid-organ transplant recipient: case report and review of the literature. J Clin Microbiol 42(9):4374–4378
2. Revankar SG et al (2004) Primary central nervous system phaeohyphomycosis: a review of 101 cases. J Trop Med Hyg. 38(1):206–222
3. Ja BT (2012) Micología Médica Básica, 4th edn. McGraw Hill
4. Lyons MK, Blair JE, Leslie KO (2005) Successful treatment with voriconazole of fungal cerebral abscess due to *Cladophialophora bantiana*. Clin Neurol Neurosurg 107:532–534
5. Jacobson ES (2000) Pathogenic roles for fungal melanins. Clin Microbiol Rev 13:708–717
6. Mathur M, Johnson CE, Sze G (2012) Fungal infections of the central nervous system. Neuroimaging Clin N Am 22:609–632

7. Luthra G, Parihar A, Nath K, Jaiswal S, Prasad KN, Husain N et al (2007) Comparative evaluation of fungal, tubercular, and pyogenic brain abscesses with conventional and diffusion MR imaging and proton MR spectroscopy. AJNR Am J Neuroradiol 28:1332–1338
8. Antulov R, Dolic K, Fruehwald-Pallamar J, Miletic D, Thurnher MM (2014) Differentiation of pyogenic and fungal brain abscesses with susceptibility-weighted MR sequences. Neuroradiology 56:937–945
9. Gasparetto EL, Cabral RF, da Cruz LC Jr, Domingues RC (2011) Diffusion imaging in brain infections. Neuroimaging Clin N Am 21:89–113
10. Gaviani P, Mullins ME, Braga TA, Hedley-Whyte ET, Halpern EF et al (2006) Improved detection of metastatic melanoma by T2*-weighted imaging. Am J Neuroradiol 27(3):605
11. Straub S, Laun FB, Freitag MT, Kölsche C et al (2020) Assessment of melanin content and its influence on susceptibility contrast in melanoma metastases. Clin Neuroradiol 30(3):607. https://doi.org/10.1007/s00062-019-00816-x
12. Enochs WS, Petherick P, Bogdanova A et al (1997) Paramagnetic metal scavenging by melanin: MR imaging. Radiology 204:417–423
13. Gramsch C, Göricke SL, Behrens F, Zimmer L et al (2013) Isolated cerebral susceptibility artefacts in patients with malignant melanoma: Metastasis or not? Eur Radiol 23(9):2622–2627. https://doi.org/10.1007/s00330-013-2857-3
14. Mahadevan A, Ramalingaiah AH, Parthasarathy S et al (2013) Neuropathological correlate of the "concentric target sign" in MRI of HIV-associated cerebral toxoplasmosis. J Magn Reson Imaging 38(2):488–495. https://doi.org/10.1002/jmri.24036
15. Singh LWN, Huprikar S, Burdette SD, Morris MI, Blair JE (2012) Donor-derived fungal infections in organ transplant recipients: guidelines of the American society of transplantation, infectious diseases community of Practice. Am J Transplant. https://doi.org/10.1111/j.1600-6143.2012.04100.x
16. Cornely UOA, Cuenca-Estrella M, Meis JF (2014) European society of clinical microbiology and infectious diseases (ESCMID) fungal infection study group (EFISG) and European confederation of medical mycology (ECMM) 2013 joint guidelines on diagnosis and management of rare and emerging fungal diseases. Clin Microbiol Infect 20:1–4
17. Luthra G, Parihar A, Nath K, Jaiswal S et al (2007) Comparative evaluation of fungal, tubercular, and pyogenic brain abscesses with conventional and diffusion MR imaging and proton MR spectroscopy. Am J Neuroradiol 28(7):1332–1338. https://doi.org/10.3174/ajnr.A0548
18. Gupta SK, Manjunath-Prasad KS, Sharma BS et al (1997) Brain abscess in renal transplant recipients: report of three cases. Surg Neurol 48:284–287
19. Salama AD, Rogers T, Lord GM, Lechler RI et al (1997) Multiple *Cladosporium* brain abscesses in a renal transplant patient: aggressive management improves outcome. Transplantation 63:160–162
20. Arunkumar MJ, Rajshekhar V, Chandy MJ et al (2000) Management and outcome of brain abscess in renal transplant recipients. Postgrad Med J 76:207–221
21. Silveira ER, Resende MA, Mariano VS et al (2003) Brain abscess caused by *Cladophialophora (Xylohypha) bantiana* in a renal transplant patient. Transplant Infect Dis 5:104–107
22. Ray U, Dutta S, Chakravarty C (2016) *Cladophialophora* brain abscess in a renal transplant recipient. Southeast Asian J Trop Med Public Health 47(5):1026–1031
23. Sood V, Pattanashetti N, Gupta S, Shivprakash M et al (2019) Multiple cerebral abscesses in a renal transplant recipient: two swords in one scabbard. Med Mycol Case Rep 23:50–52
24. Adekolu O, Noory M (2020) An unusual case of brain abscess: cerebral phaeohyphomycosis. AmJ Respir Crit Care Med 201:A6906

Publisher's Note