

RESEARCH

Open Access



Diagnostic efficiency of PET/CT in patients with cancer of unknown primary with brain metastasis as initial manifestation and its impact on overall survival

Dina Moghazy Mohamed* and Hanaa Ahmed Kamel

Abstract

Background: Carcinoma of unknown primary (CUP) is a diagnostic and therapeutic challenge; correct diagnostic approach results in better outcomes in patients with brain metastasis. Whole body 18 F-FDG PET/CT is a helpful modality to detect the origin of primary tumor and assess metastasis in the rest of the body. We assessed the value of PET/CT in detection of unknown primary in 39 patients with brain metastases as initial presentation and detected its impact on their overall survival.

Results: PET/CT could correctly detected the primary tumor in 49% of patients which occurred mainly in the lung, 63% of patients had additional extracerebral metastatic sites mostly in lymph nodes. Specificity, sensitivity, and accuracy of PET/CT in CUP patients were 95%, 79%, and 87%, respectively. No significant difference was noticed in estimated overall survival time between patients with an identified primary tumor and patients with unidentified primary tumor.

Conclusion: PET–CT was a helpful non-invasive imaging modality in detecting primary in CUP patients with metastatic brain lesion. It helped in the diagnosis of unexpected extracerebral metastatic lesions. However, the identification of the primary tumor by PET/CT has no significant prognostic effect on patient overall survival.

Keywords: PET/CT, Brain metastasis, Unknown primary, Overall survival

Background

Cancer of unknown primary tumors (CUP) is determined as known metastatic involvement of an organ without definite primary site in spite of detailed clinical investigation. CUP is considered a diagnostic and therapeutic challenge and true diagnostic approach results in favorable outcomes in these patients [1].

Brain metastases (BM) are frequent and devastating complications that occur in 10–30% of patients with advanced cancer. Most patients experience brain metastasis late during their clinical course [2].

Many reports stated that the detection rate of primary tumor in patients with extracranial metastases as first presentation was 40% and the availability of such information for patients with BM-CUPS is still unclear [3].

Therefore, diagnostic work up in CUP patients gained importance for therapeutic management. PET/CT has been proven to be more accurate than contrast-enhanced CT or MRI alone in the identification of the primary tumor site, tumor extent, local-regional, and distant metastases. This helps in selection of a more suitable and site-specific therapy and follow-up associated with a better overall survival and improved treatment outcome [4].

Chest/abdomen CT has been considered as the most valuable diagnostic procedure in patients with BM-

* Correspondence: dinamogh@hotmail.com

Faculty of Medicine, Tanta University, El-Gash Street, Tanta, El-Gharbia Governorate, Egypt

CUPS and helps in detecting the primary malignancy in more than 80% of patients [5].

The advantage of PET/CT over the other imaging techniques is its ability to reveal abnormal metabolic activity in normal body structures. Also, primary tumor in CUP patients may be located anywhere through the body. Besides, CUP is often associated with unpredictable metastatic lesion so PET/CT is considered the less sophisticated imaging modality in whole body imaging in comparison to other imaging tools [6].

The main disadvantage of PET/CT in brain scanning is the normal high gray matter uptake of 18F-FDG due to high tissue utilization of glucose that may exceed the expected uptake of many malignant tumors and as a result, the diagnosis of brain malignancy will be difficult. Several techniques have been suggested to avoid this problem, like dual time point imaging or glucose loading. However, these new techniques are time-consuming because they require specific dedicated brain protocols which are difficult to utilize in routine PET scans [7].

The aim of this study was to assess the diagnostic efficiency of PET/CT in detection of the unknown primary tumors in patients with confirmed brain metastases as first manifestation and detect its impact on their overall survive (OS).

Methods

Materials

This prospective study included 39 patients with brain metastasis confirmed by histopathological results and/or other imaging modalities. There was no information regarding the primary tumors. The study lasted during the period from March 2017 to June 2020.

Patients were selected in our study after fulfilling the following criteria: age greater than 18 years with normal cardiac functions, adequate liver, and kidney functions without comorbidity.

Exclusion criteria were the following: (1) previously diagnosed primary tumor, (2) previous history of chemotherapy or radiotherapy prior to initial PET/CT scan, (3) patients with incomplete medical records or follow-up, and (4) patients did not undergo surgical management for definite confirmation of site of primary tumor.

All patients gave written informed consent according to ethics committee guidelines.

PET/CT protocol

All patients were scanned with a dedicated PET-CT scanner (Philips, Gemini TF). All patients were fasted for at least 6 h before FDG injection. Fasting blood glucose level of less than 150 mg/dl was a requirement in all patients. The scan started 60 min after intravenous administration of 2.516 MBq (0.068 mCi/kg) FDG and the patient was instructed to rest without talking. CT

was performed from the skull base to pelvis by performing a scout view followed by a spiral CT with 80 mA and 140 kVp. No oral contrast was given and water only was used to delineate bowel. Intravenous 130 ml of iohexol (omnipaque 300 mg iodine/ml) was administered. 2D PET emission data on completion of CT (4 min per bed position covering an axial FOV of 15.7 cm with a 3-slice overlap) were obtained. The total scanning time varied between 25 and 30 min for every patient. The CT, PET, and PET/CT images were reconstructed in trans-axial, coronal, and sagittal planes.

Image interpretation of PET/CT scan

Any focal active lesion was detected in brain by PET/CT scan that exceeded the activity of normal surrounding gray matter or has a corresponding lesion in CT scan indicating metastasis. Any abnormal FDG uptake in any tissue or organ rather than the uptake in physiologic sites (e.g. bowel, myocardium) without a specific standardized uptake value (SUV) cut-off was suspected as the primary tumor site. The diagnosis of other extracerebral metastasis was done when intensity of uptake paralleled that in the site of primary tumor [7].

Standard of reference

The site of the primary tumor was confirmed by histopathological analysis of a surgical biopsy or resection specimen of the tumor (a lesion suspicious of primary tumor that matching histology of BM) and by clinical follow-up, at least for 3 months including repeated physical examination and other imaging methods. A new appearance of a lesion or lesion enlargement on subsequent radiological imaging procedures was another point of confirmation.

Statistical analysis

Fisher's exact test was used to assess the significant differences between the pathological and clinical characteristics of included patients. The overall survival (OS) was measured from the time of resection until death or last follow-up. The survival rates were calculated using the Kaplan–Meier method. Using surgery and histopathological results as gold standard, the sensitivity, specificity, and accuracy of the PET/CT in the diagnosis of primary tumor were assessed. The analyses were performed using SAS version 20 (SAS Inc., Cary, NC).

Results

Demographic and clinical characteristics of included patients

Thirty-nine patients (25 men and 14 women; mean age, 54.45 ± 12.16 years) with diagnostic metastatic brain lesions were included in this study. There was no significant difference between patients with PET/CT lesions regarding gender and age ($P = 0.362$, $P = 0.075$). Clinical

Table 1 Patient's clinico-pathologic characteristics

Parameter	Patients (n = 39)	N	%
Sex	Male	25	64
	Female	14	36
Age of patient/years (mean \pm SD)	54.45 \pm 12.16		
Site of the metastatic brain tumor	Frontal	4	21
	Parietal	2	10.5
	Occipital	1	5.3
	Temporal	1	5.3
	Multiple	11	57.9
	Lymph nodes	3	15.7
The localizations of metastatic sites other than brain region	Liver	2	10.5
	Spleen	3	15.7
	Lung	1	5.3
	Peritoneal	1	5.3
	Bone	2	10.5
	Lung	6	31.6
The site of the primary tumor in the study group	Lymphoma	5	26.3
	Gastric	4	21
	Pancreas	2	10.5
	Cecum	1	5.3
	Nasopharynx	1	5.3

data and pathologic characteristics of patients are illustrated in Table 1.

The results of PET/CT were truly positive in 19 patients confirmed by histopathological examination; these 19 patients were selected for statistical analysis (Fig. 1).

Multiple metastatic lesion was detected by PET/CT in 11/19 patients (57.9%) and 4/19 patients (21%) showed metastatic brain lesions in frontal lobe.

Twelve patients (63%) had different additional extra-cerebral metastatic sites mostly lymph nodes metastasis

Site of Primary tumour in 19 patients

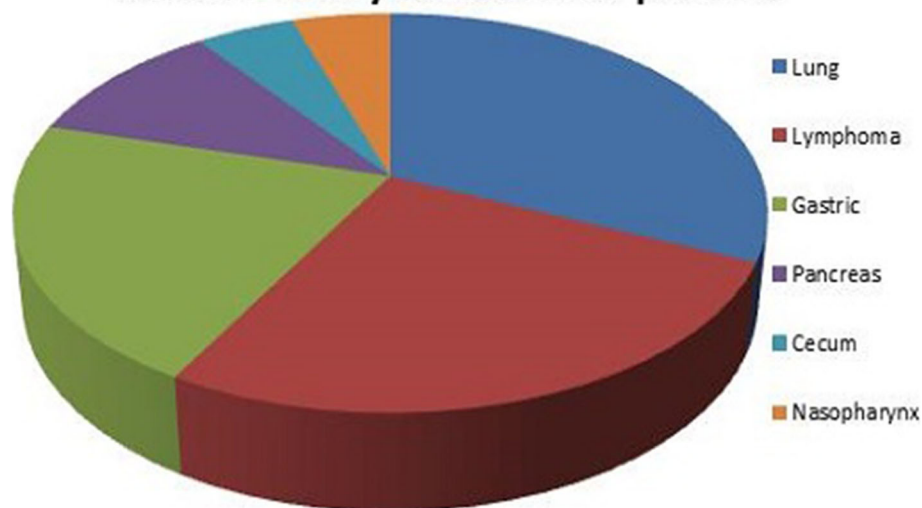


Fig. 1 Pie chart presenting the primary tumor sites in 19 patients with brain metastasis

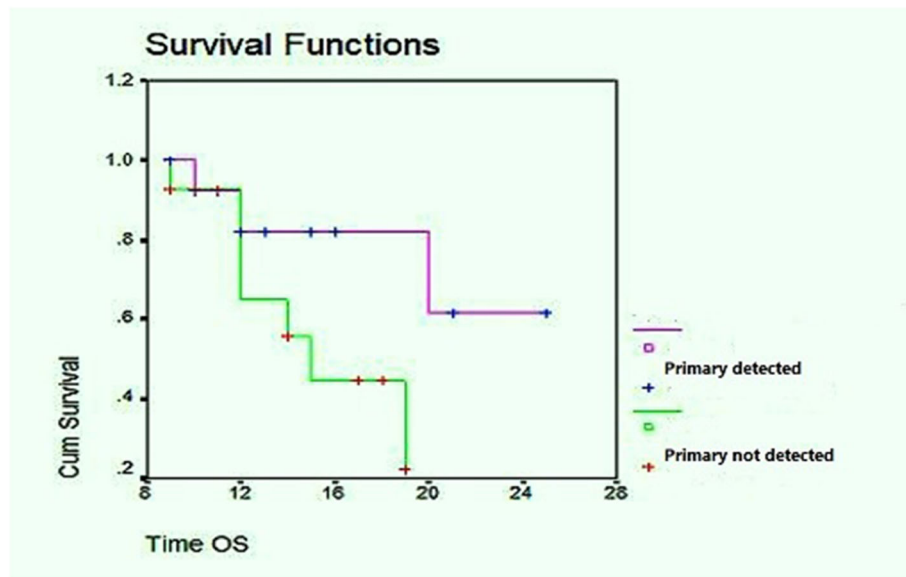


Fig. 2 Kaplan–Meier analysis in 19 patients in whom the primary tumor was detected and 20 patients with unidentified tumor. OS, overall survival

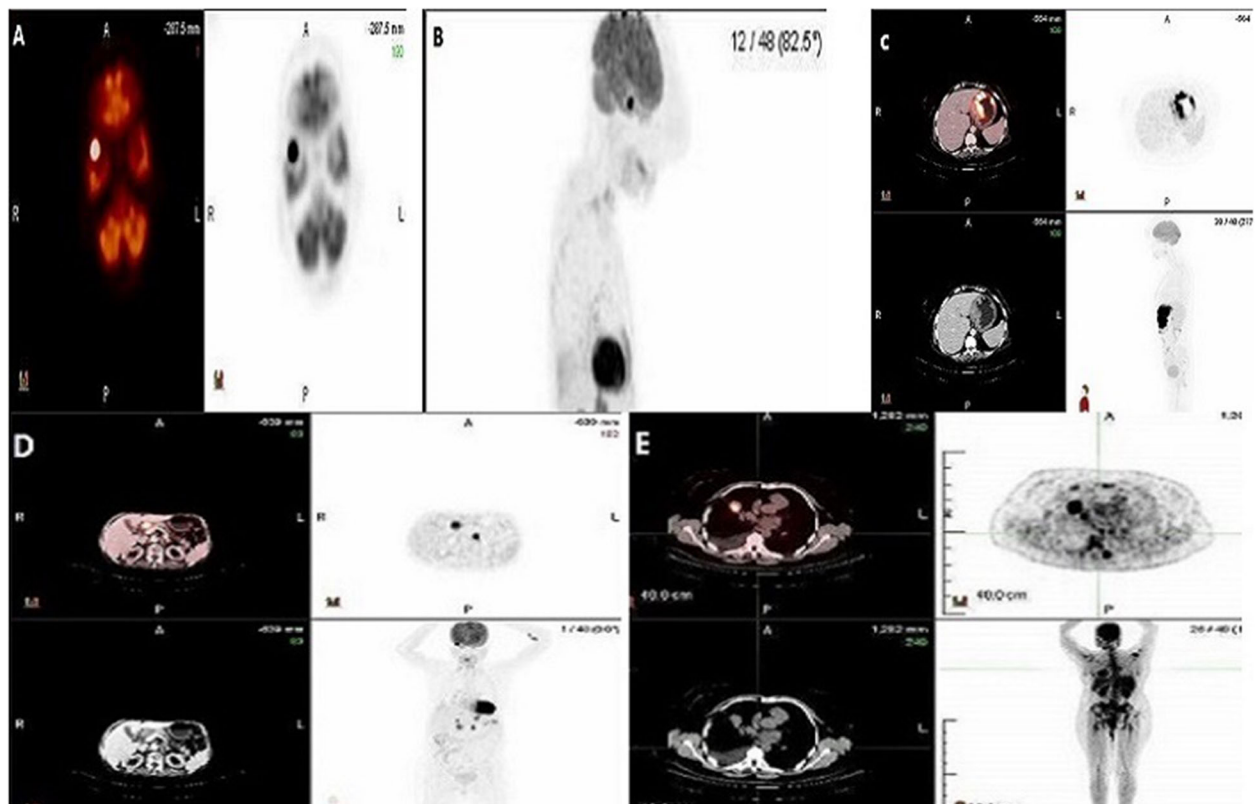


Fig. 3 Right temporal lesion incidentally detected in a female patient aged 57 years by CT scan. **a, b** Axial fused PET/CT and axial and sagittal PET scan showed a single metastatic mass lesion in the right temporal lobe with active FDG uptake. **c** Axial fused PET/CT and CT scan showed nodular gastric wall thickness seen mainly in the body with active FDG uptake proved by gastroscopic biopsy to be gastric adenocarcinoma and considered the primary tumor. **d** Axial fused PET/CT and CT scan showed active porta hepatis and left retrocaval metastatic lymph nodes. **e** Axial fused PET/CT and CT scan showed another active metastatic mass in the right lung field

[$n = 3$], liver [$n = 2$], spleen [$n = 3$], bone [$n = 2$], peritoneal [$n = 1$], and lung [$n = 1$].

The primary tumor was correctly detected by PET/CT in 19/39 patients (49%), mostly in lung 31.6% [$n = 6$], lymphoma 26.3% [$n = 5$], gastric 21% [$n = 4$], pancreas 10.5% [$n = 2$], cecum 5.3% [$n = 1$], and nasopharynx 5.3% [$n = 1$].

Diagnostic performance of PET/CT in the detection of primary tumor

In this study, we found that PET/CT showed specificity, sensitivity, and accuracy PET/CT in detection of primary tumor as 95%, 79%, and 87%, respectively.

Correlation of PET-CT and overall survival status

During the follow-up period which ranged between 6 and 25 months with a median of 12 months, median OS in patients with identified primary tumor were 12 months versus 13 months in patients with no identified primary tumor with no significant difference ($P = 0.217$) (Fig. 2).

Figures 3, 4, 5 and 6 demonstrated samples of selected cases of our study, each figure represented one case.

Discussion

Early determination of primary tumor site, extent of metastatic lesions, and best location for biopsy are critical issues for patients with BM-CUPS [8]. There is only one retrospective study of 16 patients that showed a high capability of PET/CT to localize the primary lesion in patients presented with brain metastasis [9].

This study included 39 patients with brain metastasis confirmed by histopathological analysis and/or imaging modalities with unknown primary tumor. The aim of this study was to assess the diagnostic efficiency of PET/CT in detection of the unknown primary tumors in patients presented with brain metastases as first manifestation and its impact on survival.

There was no significant difference between patients and PET/CT lesions regarding gender and age ($P = 0.362$, $P = 0.075$); the same result was seen in the result of Bakhshayeshkaram et al. who stated that mean age

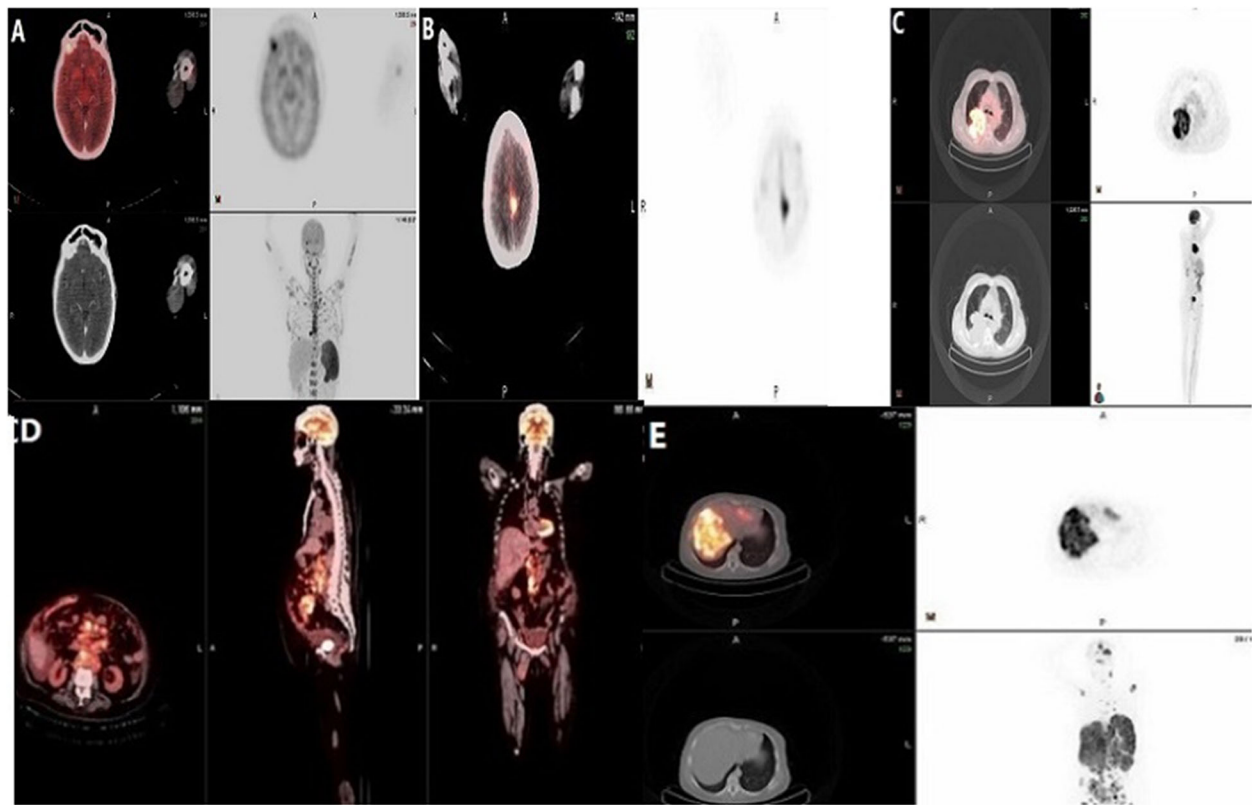


Fig. 4 A 49-year-old male with brain metastasis in the right frontal lobe and left parasagittal region from an unknown primary. **a, b** Axial fused PET/CT and CT scan showed two active metastatic lesions seen in the right frontal lobe and another one in the left parasagittal region. **c** Multiplanar fused PET/CT and PET scan showed a large mass in the right lung with active uptake proved by bronchoscopic biopsy to be bronchogenic carcinoma. **d** Multiplanar fused PET/CT scan showed multiple metastatic para-aortic lymph nodes. **e** Multiplanar fused PET/CT and PET scan showed multiple metastatic active lesions in the liver

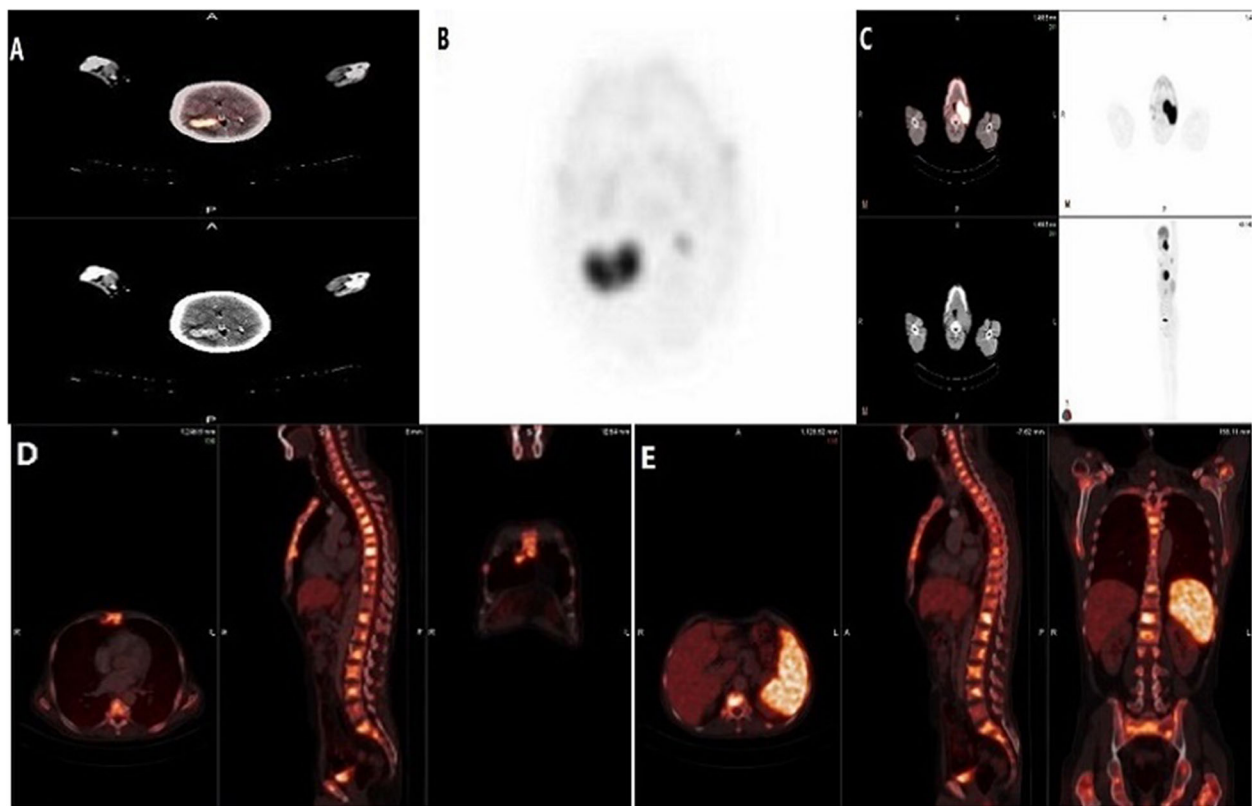


Fig. 5 A 58-year-old male with two metastatic mass lesions in the right parietal lobe. **a, b** Axial fused PET/CT and multiplanar PET scan showed two metastatic lesions in the right parietal lobe with active FDG uptake. **c** Axial fused PET/CT and CT scan showed an active mass in the left nasopharynx proved by nasopharyngoscopic biopsy to be nasopharyngeal carcinoma. **d, e** Multiplanar fused PET/CT scan showed cervical, dorsal, and lumbar vertebral bodies with increased metabolic activity indicating metastatic lesions; also, metastasis were seen in the spleen and in the sternum

did not show significant difference between male (61.10 ± 10.91 years) and female (57.84 ± 13.10) ($P = 0.36$) [10].

Some reports have stated that in spite of complete diagnostic work up, PET/CT may not add any significant benefits in either detection of occult primary tumor or help in patient's management and the additional value of PET/CT in CUP patients may be overestimated [11]. However, identification of primary tumor is not the only problem in CUP patients. Determination of the lesion extent is not helpful in recognition of the small population of CUP patients with favorable outcome but may also help in optimizing treatment planning including field of radiation therapy and also evaluation of response to treatment [12].

Wolpert et al. investigated the diagnostic value of PET/CT in 64 patients with BM of unknown primary and detected additional lesions suspicious of extracerebral metastases in 27 of 64 patients (42%) mainly in lymph nodes and concluded that PET/CT improves the accuracy of tumor staging by detecting more metastases that resulted in adjustment of the therapeutic strategy [13].

In another retrospective study by Koc et al. which included 31 patients with brain metastasis according to histopathology and/or MRI, they showed that PET/CT detected additionally 13 patients with additional metastatic sites mainly in the lung. They concluded that although the lung was the most frequent primary tumor in patients with BM, there may be unexpected metastatic tumors all over the body [14].

In Bakhshayeshkaram et al.'s study which included sixty-two CUP patients, PET/CT revealed additional metastasis in 56.4% (35/62) patients. The most frequent sites were mediastinal, hilar, and retroperitoneal lymph nodes [15].

Our results agreed with Wolpert and Bakhshayeshkaram et al. as PET/CT detected additional extracerebral metastatic sites in 12/19 patients (63%) mainly in lymph nodes.

In the same study of Bakhshayeshkaram et al., they found that the lung was the most frequent primary source of brain metastasis in 4.93% patients [15]. The same result was detected by Kung et al. in their study which included 40 patients with BM; they found that

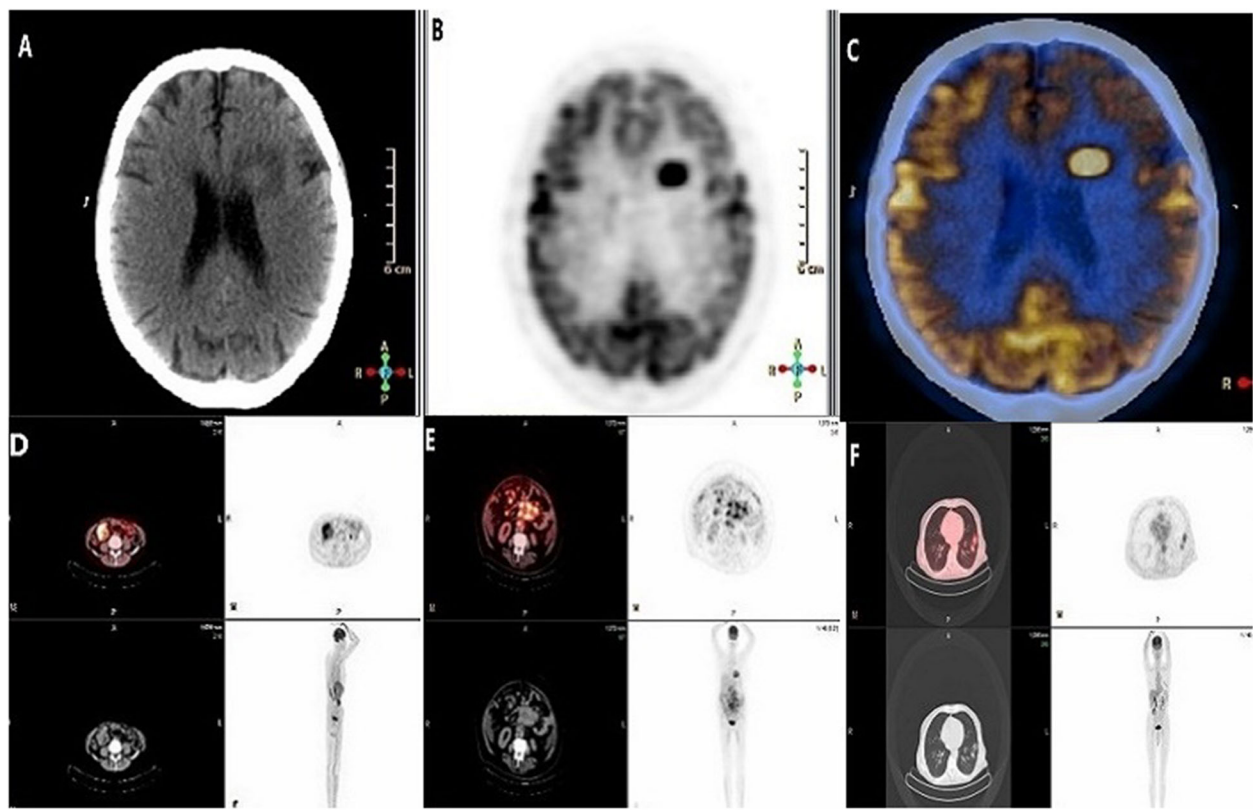


Fig. 6 A 64-year-old patient with single metastatic mass lesion in left posterior frontal lobe. **a–c** Axial CT, PET, and fused PET/CT scan showed active solitary metastatic lesion seen in the left posterior frontal lobe. **d** Multiplanar fused PET/CT and PET scan showed a cecal mass with active uptake proved by colonoscopic biopsy to be adenocarcinoma of caecum. **e** Multiplanar fused PET/CT and PET scan showed multiple active retroperitoneal lymph nodes. **f** Multiplanar fused PET/CT and PET scan showed two metastatic active mass lesions in the left lung

bronchogenic carcinoma was common primary source in 62.5% (25/40) patients [16]. Our results matched with both studies as the primary tumor was correctly detected by PET/CT in 31.6% (6/19) patients, mostly from the lung.

A study by Gutzeit et al. has shown that CT alone can detect the primary tumor in 8/45 patients (18%), while this percent was 33% (15/45 patients) when used PET/CT [17].

Roh et al. showed the sensitivity of PET/CT (87.5%) was significantly higher than that of CT (43.7%) in detection of the primary tumor in patients with brain metastases [18].

Han et al. in their study which included 162 CUP patients presented mainly with brain metastases concluded that sensitivity, specificity, and accuracy of ^{18}F -FDG PET/CT was 91.5%, 85.2%, and 88.3%, respectively [19].

In another study by Riaz et al. which included 100 patients, the sensitivity, specificity, and accuracy of ^{18}F -FDG PET/CT in detection of primary tumor were reported as 80%, 74%, and 78% [20].

In our study, the primary tumor could not be detected in (41%) 16/39 patients. Fifteen patients showed true-

negative results and one patient was a false-negative result; the tumor was detected by histopathological analysis to be cancer pancreas and showed low uptake of FDG. Four patients showed false-positive results, two of them were diagnosed falsely by PET/CT to be pulmonary carcinoma but one of them was pulmonary hamartoma and the other one was pulmonary inflammatory pseudotumor. The remaining 2 patients were diagnosed by PET/CT to be cancer colon but by colonoscopic biopsy, one patient was diagnosed as polyp and other one was sigmoid diverticulosis. As a result, we found that PET/CT had specificity, sensitivity, and accuracy in detection of primary tumor as 95%, 79%, and 87%, respectively.

During the follow-up period which ranged between 6 and 25 months with a median of 12 months, median OS in patients with identified primary tumor were (12 months) versus (13 months) in patients with no identified primary tumor with no significant difference ($P = 0.217$)

In a study cohort by Reinert et al. which included 155 patients to detect the effect of PET/CT on clinical

management in CUP patients, he concluded that there was no significant differences in estimated overall survival time could be noticed between patients with an identified primary tumor and patients with unidentified primary tumor [2]. This result is in concordance with other studies; their explanation was that for many patients with identified primary tumor, no management can be provided that improves their overall survival [21].

Conclusion

From our study, we found that PET/CT was a helpful imaging modality in detecting the localization of primary lesion in majority of the CUP patients with metastatic brain lesion as first manifestation. Most of the patients with unknown primary site was from lung cancer but there were unexpected other extra cerebral metastatic lesions mostly lymph nodes metastasis. However, the identification of the primary tumor by PET/CT has no significant prognostic effect on patient overall survival.

Abbreviations

CUP: Carcinoma of unknown primary; BM: Brain metastasis; 18 F-FDG PET/CT: 18F-Fluorodesoxyglucose position emission tomography

Acknowledgements

Not applicable.

Authors' contributions

D.M. collected data in all stage of manuscript, correlated the study concept and design, and implies responsibility and accountability for published manuscript. H.K. had data for analysis and supervised the study with significant contribution to design the methodology. All authors discussed the results and contributed to the final manuscript. All authors had read and approved the manuscript.

Funding

We did not receive any funding for this work from any organization.

Availability of data and materials

The authors confirm that all data supporting the finding of the study are available within the article and the raw data and data supporting the findings were generated and available at the corresponding author on request.

Ethics approval and consent to participate

This study was approved by the ethics committee of Tanta University Hospital, Faculty of Medicine, with approval number 2365-2020. A written informed consent was received from all patients participate in this study.

Consent for publication

Authors accepted to publish the paper.

Competing interests

The authors declare no competing interests.

Received: 26 October 2020 Accepted: 7 February 2021

Published online: 22 February 2021

References

1. Kim DW, Jung SA, Kim CG (2010) The efficacy of dual time point 18F-FDG PET imaging for grading of brain tumors. *Clin Nucl Med* 35(6):400–403
2. Reinert CP, Sekler J, Fougère CH (2020) Impact of PET/CT on clinical management in patients with cancer of unknown primary—a PET/CT registry study. *Eur Radiol* 30:1325–1333. <https://doi.org/10.1007/s00330-019-06518-9>
3. Burglin SA, Hess S, Hoiland-Carlsen PF (2017) 18F-FDG PET/CT for detection of the primary tumor in adults with extracervical metastases from cancer of unknown primary: a systematic review and meta-analysis. *Medicine (Baltim)* 96(16):e6713
4. Johansen J, Petersen H, Godballe C, Loft A, Grau C (2011) FDG-PET/CT for detection of the unknown primary head and neck tumor. *Q J Nucl Med Mol Imaging* 55:500–508
5. Fischer B, Lassen U, Mortensen J (2009) Preoperative staging of lung cancer with combined PET-CT. *N Engl J Med* 361(1):32e9
6. Pavlidis N, Khaled H, Gaafar R (2015) Mini review on cancer of unknown primary site: a clinical puzzle for the oncologists. *J Adv Res* 6:375–382
7. Hofman SM, Hicks RJ (2016) How we read oncologic FDG PET/CT. *Hofman Hicks Cancer Imaging* 16:35
8. Krajewski M, Jagannathan JP (2013) Cancer of unknown primary sites: what radiologists need to know and what oncologists want to know. *AJR Am J Roentgenol* 200(3):484–492
9. Klee B, Law I, Hojgaard L (2002) Detection of unknown primary tumours in patients with cerebral metastases using whole-body 18F-fluorodeoxyglucose positron emission tomography. *Eur J Neurol* 9(6): 657e62
10. Bakhshayeshkaram KM, Tavakoli F, Hassanzad M (2018) Brain-included 18F-FDG PET/CT acquisition protocol: cancer-specified clinical impact of newly-diagnosed brain metastasis in extra-cerebral cancer patients. *Novelty Biomed* 6(1):21–28
11. Varadhachary R, Martin N (2014) Cancer of unknown primary site. *N Engl J Med* 371(8):757–765
12. Lee JR, Kim JS, Roh JL (2014) Detection of occult primary tumors in patients with cervical metastases of unknown primary tumors: comparison of 18F-F-18 FDG PET/CT with contrast-enhanced CT or CT/MR imaging—prospective study. *Radiology* 274(3):764–771
13. Wolpert F, Weller M, Berghoff AS (2018) Diagnostic value of 18F-fluorodesoxyglucose positron emission tomography for patients with brain metastasis from unknown primary site. *Eur J Cancer* 96:64–72
14. Koc ZP, Kara PO, Dağtekin A (2018) Detection of unknown primary tumor in patients presented with brain metastasis by F-18 fluorodeoxyglucose positron emission tomography/computed tomography. *CNS Oncol* 2:CNS12
15. Bakhshayeshkaram KM, Ghobadi M, Hassanzad M (2018) Diagnostic performance of F-18 FDG PET/CT in patients with cancer of unknown primary: additional benefit over CT-based conventional work up. *Mol Imaging Radionucl Ther* 27(3):126–132
16. Kung BT, Auyong TK, Tong CM (2014) Prevalence of detecting unknown cerebral metastases in fluorodeoxyglucose positron emission tomography/computed tomography and its potential clinical impact. *World J Nucl Med* 13(2):108–111
17. Gutzeit A, Antoch G, Kuhl H (2005) Unknown primary tumors: detection with dual-modality PET/CT—initial experience. *Radiology* 234:227–234. <https://doi.org/10.1148/radiol.2341031554>
18. Roh JL, Kim JS, Lee JH (2009) Utility of combined (18)F-fluorodeoxyglucose-positron emission tomography and computed tomography in patients with cervical metastases from unknown primary tumors. *Oral Oncol* 45:218–224
19. Han A, Xue J, Hu M et al (2012) Clinical value of 18 F-FDG PET-CT in detecting primary tumor for patients with carcinoma of unknown primary. *Cancer Epidemiol* 36(5):470–475
20. Riaz S, Nawaz MK, Faruqi ZS (2016) Diagnostic accuracy of 18F-fluorodeoxyglucose positron emission tomography-computed tomography in the evaluation of carcinoma of unknown primary. *Mol Imaging Radionucl Ther* 25:11–18
21. Breuer N, Behrendt FF, Heinzel A (2014) Prognostic relevance of (18)F-FDG PET/CT in carcinoma of unknown primary. *Clin Nucl Med* 39:131–135

Publisher's Note

Springer Nature remains neutral with regard to jurisdictional claims in published maps and institutional affiliations.