

CASE REPORT

Open Access

Intracranial calcification in venous congestion



Hairuddin Achmad Sankala^{1*} and Hilwati Hashim²

Abstract

Background: Intracranial calcification is a common finding on brain imaging which can be non-specific. The calcification can be physiological or pathological. Likewise, subcortical calcification is a non-specific finding on non-contrast-enhanced computed tomography. This could be secondary to multiple underlying diseases such as Sturge-Weber syndrome, tuberous sclerosis, Fahr disease, post-chemoradiotherapy change, and metabolic disorders secondary to parathyroid or thyroid gland abnormalities. On the other hand, subcortical calcification secondary to arteriovenous malformation and dural venous fistula are uncommon findings. We report two cases with subcortical calcification secondary to these vascular malformations. We aim to highlight the importance of recognising subcortical calcification as one of the possible imaging appearances of dural venous fistula and arteriovenous malformation.

Case presentation: We report two cases, whom were a 45-year-old lady and a 20-year-old man, with subcortical calcification on non-contrast-enhanced computed tomography, which were later confirmed to be secondary to chronic venous congestion as the results of dural venous fistula and arteriovenous malformation, respectively. Both patients underwent magnetic resonance imaging of the brain and digital subtraction angiography to confirm the diagnosis. Subsequently, both patients were offered embolisation with the 45-year-old lady opting for conservative management and the 20-year-old man waiting for the procedure, at the time of writing.

Conclusion: Venous congestion secondary to intracranial vascular malformation is an important differential diagnosis for extensive subcortical and basal ganglia calcification. Knowledge on the possibility of vascular malformation to present with subcortical calcification is crucial to avoid misdiagnosis and mismanagement of the patients.

Keywords: Venous congestion, Arteriovenous malformation, Dural arteriovenous fistula, Calcification

Background

Intracranial calcification is common intracranial findings and the underlying causes could be either benign physiological or variety of pathological processes. Conventional radiography had been replaced by computed tomography (CT) as the ideal modality due to its high sensitivity. Likewise, magnetic resonance imaging (MRI) is a useful modality for detection of calcification [1]. Subcortical calcification is also a non-specific finding. However,

subcortical calcification secondary to arteriovenous malformation and dural venous fistula are uncommon findings [2]. We report two cases with subcortical calcification secondary to these vascular malformations. This is to highlight the importance of recognising subcortical calcification as one of the possible imaging appearances of dural venous fistula and arteriovenous malformation.

Case presentation 1

A 45-year-old lady presented with a first episode of generalised tonic-clonic seizure, which progressed to status epilepticus. She was previously well with no known

* Correspondence: hairuddinachmads@gmail.com

¹Department of Radiology, Hospital Kuala Lumpur, 23, Jalan Pahang, 50586 Kuala Lumpur, Malaysia

Full list of author information is available at the end of the article

medical illness. She had a non-contrast-enhanced CT (NCECT) brain which showed extensive, fairly symmetrical subcortical calcification at bilateral cerebral and cerebellar hemispheres with calcification of bilateral basal ganglia (Fig. 1a, b). White matter hypodensities were also noted at bilateral cerebral hemispheres. Subsequent MRI of the brain showed multiple serpiginous dilated cortical veins in the left cerebral hemisphere and posterior fossa with absence of nidus, consistent with dural arteriovenous fistula (AVF). There were also bilateral cerebral white matter hyperintensities on T2-weighted (T2W) and fluid attenuation inversion recovery (FLAIR) images (Fig. 1c). She later underwent digital subtraction angiography (DSA) which showed dural AVF involving communication between the right superior temporal artery and superior sagittal sinus, left anterior choroidal artery and left sigmoid sinus, left posterior auricular artery and left sigmoid sinus, and left posterior inferior cerebellar artery and left transverse sinus (Fig. 1d). She was offered embolisation but opted for conservative management. Her seizure was well-controlled upon discharge and she is currently waiting for her next follow-up.

Case presentation 2

A 20-year-old male presented with a first episode of generalised tonic-clonic seizure. Prior to the seizure, he complained of right eye redness and pain. NCECT brain showed extensive, fairly symmetrical subcortical calcification at bilateral cerebral and cerebellar hemispheres with calcification of both basal ganglia. White matter hypodensities were noted at bilateral cerebral and cerebellar hemispheres. Hyperdense serpiginous structures were also noted in the posterior fossa, suggestive of dilated vessels. In addition, bilateral lateral and third ventricles were dilated with preserved fourth ventricle, suggestive of obstructive hydrocephalus (Fig. 2a, b). Subsequent MRI brain showed multiple dilated serpiginous flow voids in the periventricular region, consistent with a nidus, with large draining veins into the internal cerebral veins, in keeping with arteriovenous malformation (AVM). T2W images showed subcortical white matter hypointensities which correlated with area of calcification noted on CT (Fig. 2c). DSA showed pericallosal AVM with the right anterior cerebral artery supplying the nidus and drainage via internal cerebral veins. He is scheduled for embolisation later. His seizure is currently well-controlled with medication.

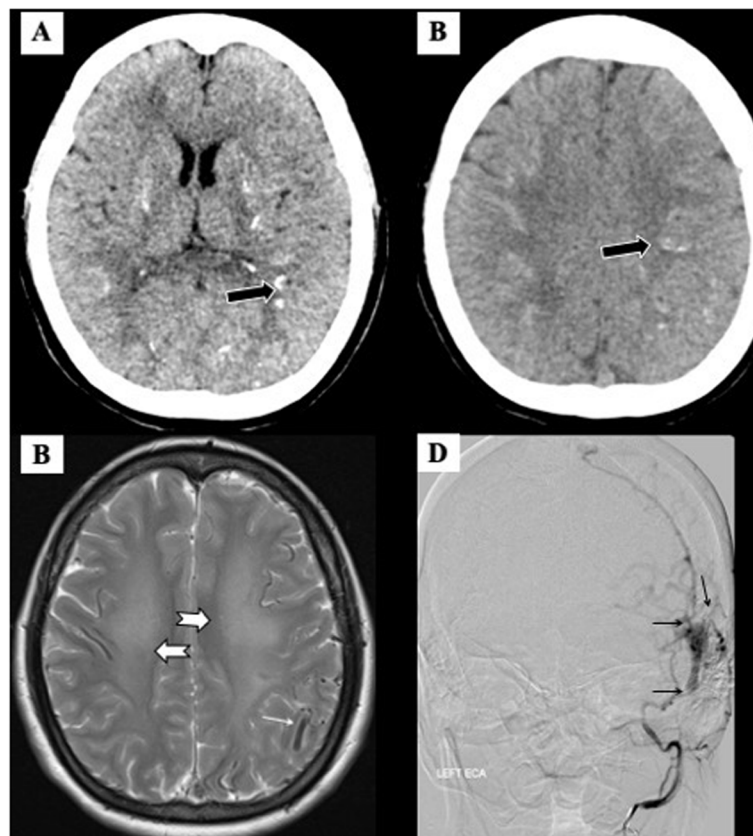


Fig. 1 a, b Axial NCECT brain shows subcortical calcification (black arrows). c Axial T2W MRI brain shows white matter hyperintensity (large white arrows) and dilated veins (small white arrow). d DSA of left ECA image in coronal view shows multiple abnormal communication between ECA branches and left sigmoid sinus dural AVF (small black arrows)

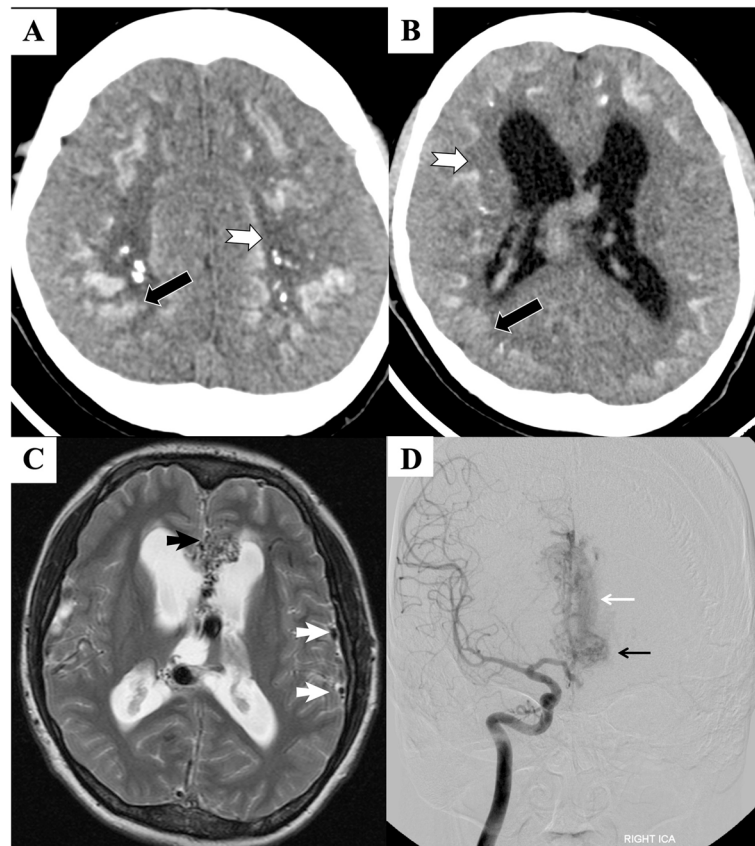


Fig. 2 a, b Axial NCECT brain shows subcortical calcification (black arrow) and white matter hypodensity (white arrow). c Axial T2W MRI brain shows dilated veins (white arrowhead) and nidus of AVM (black arrowhead). d DSA of right ICA shows nidus of AVM (small black arrow) and large draining vein (small white arrow). Note dilated ventricles on NCECT (b) and MRI (c)

Discussion

AVMs are abnormal communication between the arteries and veins with the absence of intervening capillary bed. It is reported that 0.1% of the population harbours an AVM and the prevalence is estimated to be 10–18 per 100,000 population [3]. Dural AVFs are abnormal arteriovenous channel within the dura mater, involving a dural sinus and/or cortical vein, which constitute 10–15% of all intracranial arteriovenous shunts [2, 3]. Calcification of the abnormal vessels with or without oedema and intracranial haemorrhages are common imaging findings of AVMs [4]. The main CT finding of dural AVF is haemorrhage or focal oedema [5]. Calcification associated with arteriovenous malformation is also not uncommon. However, calcification of the brain parenchyma, separate from the malformation, is less commonly encountered. In the case of dural AVF, bilateral subcortical and basal ganglia calcifications are rarely reported [2].

In our patients, both had almost similar CT findings which are extensive, fairly symmetrical subcortical calcification involving the cerebrum, cerebellum, and basal

ganglia. These were associated with white matter hypodensities in both of the cases. Almost similar findings were reported by Yang et al. [6], Sayani et al. [2], Metoki et al. [5], and Saade et al. [7]. Subcortical calcifications are not a disease-specific finding. It is also seen in other diseases such as Sturge-Weber syndrome, tuberous sclerosis, Fahr disease, post-chemoradiotherapy change, and metabolic disorders secondary to parathyroid or thyroid gland abnormalities. Corpus striatum and dentate nuclei calcification is also commonly seen in these diseases [1, 2, 6, 7]. The exact mechanism of the calcification remains unknown and poorly understood. It is important to note that, in our cases, the underlying pathology for the aforementioned CT findings were of two different entities, dural AVF and AVM, respectively. Interestingly, both cases manifested with almost similar CT appearances.

AVF and AVM are known to cause venous congestion in the brain. Hence, we postulate that the calcification is attributed to the persistent venous congestion, caused by the arteriovenous abnormal communication, resulting in venous hypertension. This is further supported by the

development of white matter hypodensity, suggestive of white matter oedema, and dilated veins. This hypothesis is in concordance with Lai et al. [8]. Together with Metoki et al. [5], Chen et al. [9], and Yu et al. [10], they also postulated that these findings could also be secondary to 'steal' phenomenon.

Venous congestion or 'steal' phenomenon is believed to cause calcification at the hypoperfused brain parenchyma or secondary to dystrophic mural changes of the congested veins [6]. This is true in our cases as the areas of subcortical calcification did follow the areas of white matter hypodensities, indicating areas of venous congestion. The subcortical white matter is located at the watershed area, which renders it prone to hypoxic or ischaemic insult. Basal ganglia are likewise prone to similar insult due to its high metabolic rate [9]. Therefore, this could explain the presence of basal ganglia calcification in both of our cases.

Conclusions

We deduce that although uncommon, subcortical and basal ganglia calcification is an important radiological finding in patients with venous hypertension or congestion. With this knowledge, identifying subcortical calcification should alert the reporting radiologist to look for evidence of venous hypertension, and subsequently to the cause of venous hypertension or congestion such as vascular malformation.

Abbreviations

AVM: Arteriovenous malformation; AVF: Arteriovenous fistula; DSA: Digital subtraction angiography; FLAIR: Fluid attenuation inversion recovery; MRI: Magnetic resonance imaging; NCECT: Non-contrast-enhanced computed tomography; T2W: T2-weighted

Acknowledgements

The authors would like to thank Dr. Fariyah Abd. Ghani and Dr. Subbashini Subramaniam of Department of Radiology, Hospital Sungai Buloh and Hospital Kuala Lumpur, Malaysia. The authors would also like to thank the Director of Health Malaysia for permission to publish this paper.

Availability of data and material

The datasets used and/or analysed in this case report are available from the corresponding author on reasonable request.

Authors' contributions

HAS was involved in the conception, acquisition and interpretation of images, and drafting the article and involved in the final version submitted. HAS was a major contributor in writing the manuscript. HH was involved in the conception, acquisition and interpretation of images, and editing the article and involved in the final version submitted. The authors read and approved the final manuscript.

Funding

Not applicable

Declarations

Ethics approval and consent to participate

Not applicable

Consent for publication

All patients included in this research gave informed consent to publish the data contained within this study.

Competing interests

The authors declare that they have no competing interests

Author details

¹Department of Radiology, Hospital Kuala Lumpur, 23, Jalan Pahang, 50586 Kuala Lumpur, Malaysia. ²Department of Radiology, Faculty of Medicine, Jalan Hospital, Universiti Teknologi Mara, 47000 Sungai Buloh, Shah Alam, Selangor, Malaysia.

Received: 30 January 2021 Accepted: 16 July 2021

Published online: 26 July 2021

References

1. Taborda KNN, Wilches C, Manrique A (2017) A diagnostic algorithm for patients with intracranial calcifications. *Rev. Colomb. Radiol.* 28:4732–4739
2. Sayani R, Khan ZA, Tanveer-ul-Haq, Hamid RS, Azeemuddin M (2012) Rare co-occurrence of dural arteriovenous fistula and arteriovenous malformation with bilateral subcortical and basal ganglia calcification. *J Pak Med Assoc* 62(6):605–607
3. Ajiboye N, Chalouhi N, Starke RM, Zanaty M, Bell R (2014) Cerebral arteriovenous malformations: evaluation and management. *Scientific World Journal* 2014:1–6. <https://doi.org/10.1155/2014/649036>
4. Willinsky R, Terbrugge K, Montanera W, Mikulis D, Wallace MC (1994) Venous congestion: an MR finding in dural arteriovenous malformations with cortical venous drainage. *AJNR AM J Neuroradiol* 15(8):1501–1507
5. Metoki T, Mugikura HS, Ezura M, Matsumoto Y et al (2006) Subcortical calcification on CT in dural arteriovenous fistula with cortical venous reflux. *AJNR AM J Neuroradiol* 27(5):1076–1078
6. Yang M-S, Chen CC-C, Cheng Y-Y, Yeh D-M, Lee S-K, Tyan Y-S (2005) Unilateral subcortical calcification: a manifestation of dural arteriovenous fistula. *AJNR AM J Neuroradiol* 26(5):1149–1151
7. Saade C, Najem E, Asmar K, Salman R, Achkar BE, Naffaa L (2019) Intracranial calcifications on CT: an updated review. *Radiology Case* 13(8):1–18. <https://doi.org/10.3941/jrcr.v13i8.3633>
8. Lai PH, Chang MH, Liang HL, Pan HB, Yang CF (2000) Unusual signs for dural arteriovenous fistulas with diffuse basal ganglia and cerebral calcification. *Taipei* 63:329–333
9. Chen Z, Feng H, Zhu G, Wu N, Lin J (2007) Anomalous intracranial venous drainage associated with basal ganglia calcification. *AJNR AM J Neuroradiol* 28(1):22–24
10. Yu YL, Chiu EKW, Woo E, Chan FL, Lain WK et al (1987) Dystrophic intracranial calcification: CT evidence of 'cerebral steal' from arteriovenous malformation. *Neuroradiology* 29(6):519–522. <https://doi.org/10.1007/BF00350433>

Publisher's Note

Springer Nature remains neutral with regard to jurisdictional claims in published maps and institutional affiliations.

Submit your manuscript to a SpringerOpen® journal and benefit from:

- Convenient online submission
- Rigorous peer review
- Open access: articles freely available online
- High visibility within the field
- Retaining the copyright to your article

Submit your next manuscript at ► [springeropen.com](https://www.springeropen.com)