

RESEARCH

Open Access



# Three-dimensional tomosynthesis versus two-dimensional mammography in detection and characterization of different breast lesions

Samia Aboelnour Abdeltwab Abdelattef<sup>1\*</sup>, Suzan Farouk Ibrahim<sup>2</sup>, Wafaa Raft Abdelhamid<sup>2</sup> and Fatten Mohamed Mahmoud<sup>2</sup>

## Abstract

**Background:** Breast cancer is considered the most serious lesion among different breast lesions. Mammography is the corner stone for screening for detection of breast cancer. It has been modified to digital mammography (DM) and then to digital breast tomosynthesis (DBT). Tomosynthesis is an emerging technique for diagnosis and screening of breast lesions.

The aim of this study is to interrogate whether the addition of DBT to DM helps in better detection and characterization of different breast lesions.

**Methods:** This is a prospective study carried on 38 female patients according to our inclusion criteria. All patients were evaluated by using DM alone and thereafter with the addition of DBT to DM. Recall rate was calculated, and the imaging findings of each case were correlated with the final diagnosis and follow-up.

**Results:** DM identified 32 lesions while DBT with DM identified 37 lesions. On DM alone, 17 lesions were characterized as masses, 5 as focal asymmetry, 2 as architectural distortion, 7 as microcalcification and 1 as macrocalcification. With the addition of DBT, 27 lesions were characterized as masses, 1 as focal asymmetry, 1 as architectural distortion, 7 as microcalcification and 1 as macrocalcification. So, there were better detection and characterization of lesions with the addition of DBT than DM alone. The sensitivity, specificity, AUC, positive and negative predictive values were significantly higher with the addition of DBT to DM (100%, 90.5%, 0.952, 90% and 100%, respectively) than with DM (77.8%, 80.9%, 0.794, 77.8% and 80.9%, respectively) for all breast lesions.

**Conclusions:** The addition of DBT to DM helps in better detection and characterization of different breast lesions. This leads to early detection of breast cancer, improvement of the performance of radiologists and saving time by reduction of recall rate.

**Keywords:** Breast lesions, Digital mammography, Digital tomosynthesis

## Background

Most of the lesions that occur in the breast are benign. Much concern is given to malignant lesions of the breast because breast cancer is the most common malignancy in women; however, benign lesions of the breast are far more frequent than malignant ones [6].

\*Correspondence: samyaabdelateef@hotmail.com;

SamiaAbdelattef@med.asu.edu.eg

<sup>1</sup> Egypt Ministry of Health and Population, 94 Abdelaziz Fahmy, Santfatema Square, Heliopolis, Egypt

Full list of author information is available at the end of the article

Breast cancer is the most common cancer and the primary cause of mortality from cancer among females around the world. Its survival rate in developing countries is generally poorer than in developed countries, primarily as a result of delayed diagnosis of cases. Enhancing breast cancer outcome and survival by early detection remains the foundation of breast cancer regulations [1] (Fig. 1).

In the 1970s, mammography gained widespread acceptance as a breast screening tool for cancer detection. It was shown to reduce mortality rate. From that time, technological advancements have driven the evolution from analog film mammography to full-field digital mammography (FFDM) and DBT [27] (Fig. 2).

DBT is a modified mammographic technique, which involves acquired multiple and low-dose projection images of the breast through a limited range of angles less than 60°. For the projections acquisition, the X-ray tube rotates around the static and compressed breast. The images are reconstructed into a stack of focal planes according to the height above the detector, typically at 1-mm intervals, to create a three-dimensional (3D) volume of thin sectional data. This algorithm uses the different locations in the projections of the same tissue to compute their vertical position that viewed sequentially as a stack in orientation (craniocaudal (CC) and

mediolateral oblique (MLO)), so estimating the 3D distribution of the tissue [11] (Fig. 3).

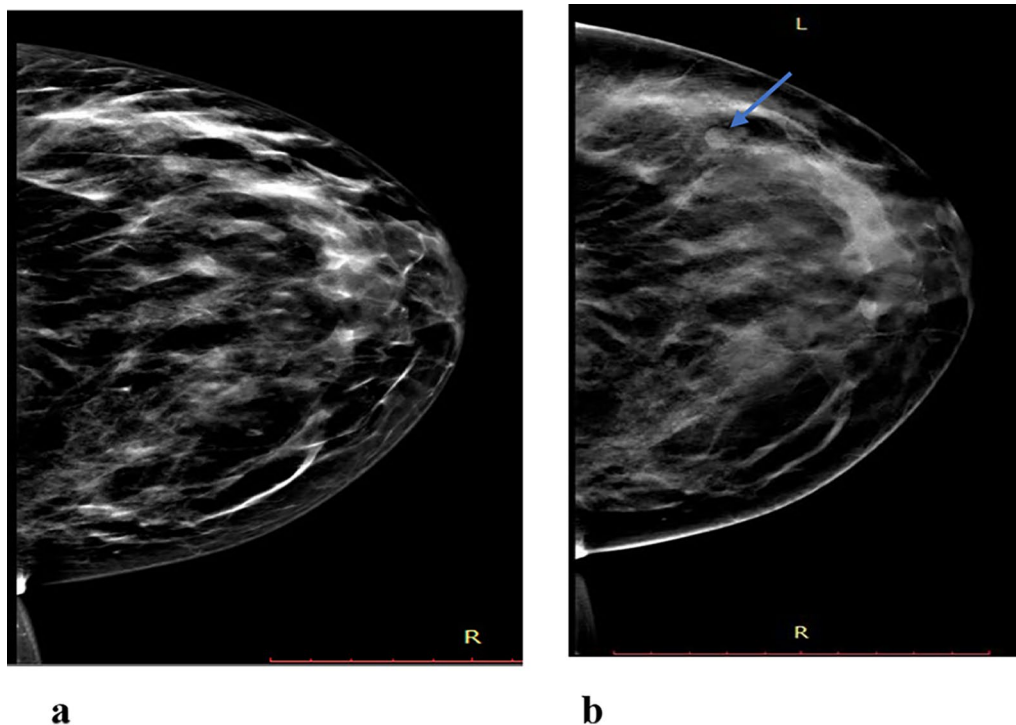
3D tomosynthesis offers a potential advantage for detection of masses, architectural distortion and asymmetries compared with conventional two-dimensional digital mammography (2DDM) images [14].

The aim of this study is to interrogate whether the addition of DBT to DM helps in better detection and characterization of different breast lesions.

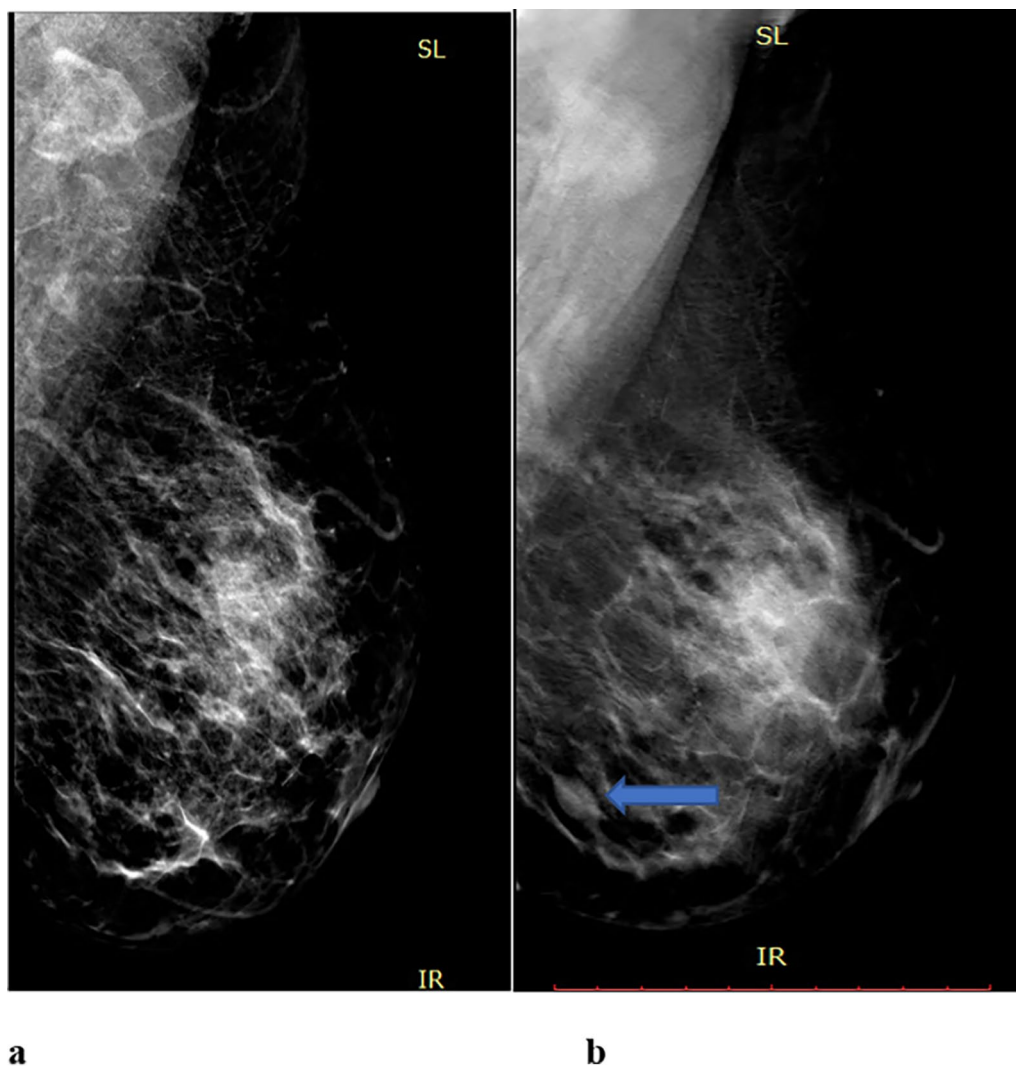
## Methods

### Patients

This is a prospective study conducted at our institute during the period from December 2018 to December 2020 as follow-up was needed in some cases. A total of 38 female patients were included in this study. Their ages ranged from 31 to 65 years with a median of 41.5 years. They were provided with a signed informed consent, and the study was conducted after institutional review board approval by Radiology Department Scientific Board as well as fulfilling the ethical guidelines of the institute (Fig. 4). All patients were evaluated by DM alone and then after adding DBT. Recall rate was calculated and the imaging findings of each case were correlated with the final diagnosis, which was made based upon



**Fig. 1** A 39-year-old female complained of mastalgia in left breast with positive family history (first degree relatives) for breast cancer. **a** CC view of 2DDM of left breast shows heterogeneously dense breast (ACR c) with no abnormality detected. **b** CC view of DBT of left breast shows well-defined bilobed isodense mass in outer quadrant (BIRADS 3), proved by histopathology to be fibro-adenoma



**Fig. 2** A 48-year-old female complained of mastalgia in left breast. **a** MLO view of 2DDM of left breast shows heterogeneously dense breast (ACR c) with no abnormality detected. **b** MLO view of DBT of left breast shows circumscribed oval isodense mass in lower quadrant (BIRADS 3), proved by histopathology to be fibro-adenoma

histopathological assessment either by biopsy samples or by fine needle aspiration cytology, and 3 follow-up studies every 6 months for some cases.

**Inclusion criteria**

Women included in this study who were referred from breast clinic for either screening or follow-up of already present lesion or for diagnoses of complains such as palpable lump, nipple discharge or breast pain (Fig. 5).

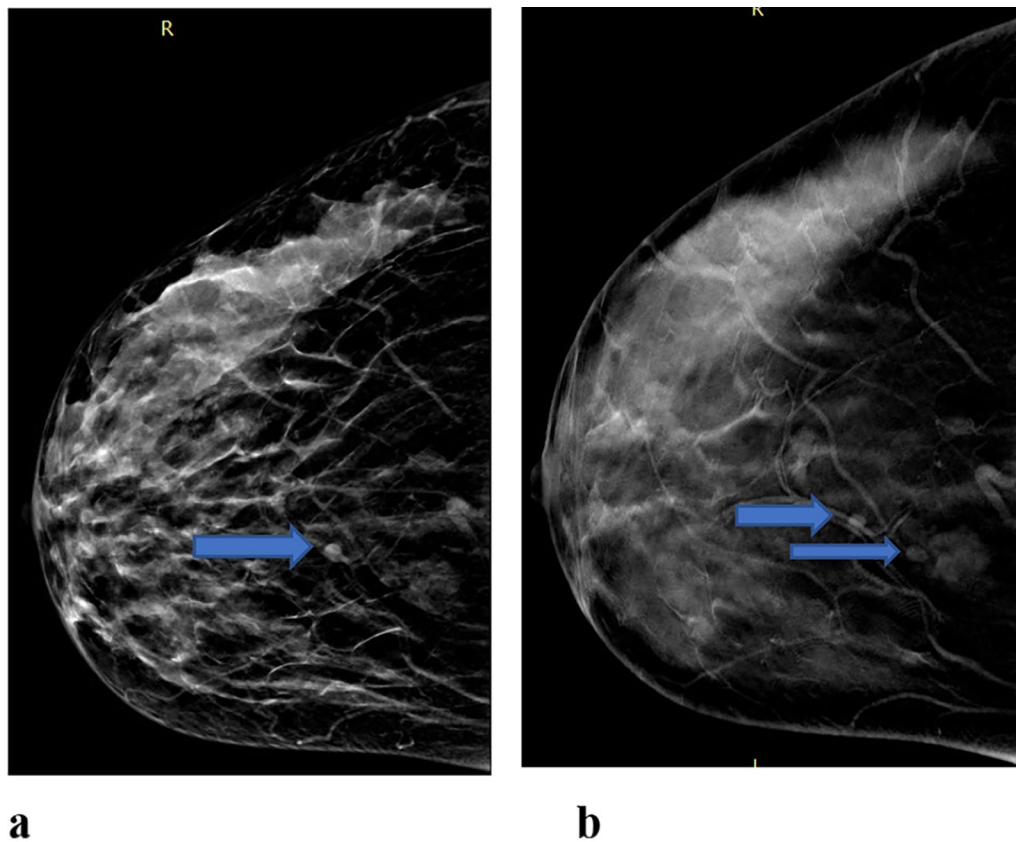
**Exclusion criteria**

Pregnant and lactating females.

Females with open breast wounds (Fig. 6).

**The technique of DM and DBT**

Both examinations were done on Senographe Pristina, GE healthcare FFDM machine with 3D digital tomosynthesis option which enables the machine to generate both 2D and 3D images. For the projections acquisition, the X-ray tube rotates around the static and compressed breast between 15° (narrow range) and 60° (wide range) in a plane aligned with the chest wall allowing for 11 to 15 low-dose projection images (2D) acquired for the tomosynthesis images. The images were reconstructed into a stack of focal planes according to the height above the detector, typically at 1-mm intervals, to create a 3D volume of thin sectional data from the low-dose projection 2D images used to reconstruct 1 mm thick sections



**Fig. 3** A 49-year-old female came for follow-up after left breast lumpectomy followed by Chemotherapy and Radiotherapy. **a** CC view of 2DDM of right breast shows heterogeneously dense breast (ACR c), circumscribed oval dense mass in inner quadrant. **b** CC view DBT of right breast shows circumscribed oval dense mass in inner quadrant as seen in mammography but there is another circumscribed oval isodense mass in the same quadrant which is hardly detected in mammography. (BIRADS 3), proved by histopathology to be fibro-adenoma

separated by 1 mm space. Images were obtained in the same standard projections (CC and MLO) in the form of a series of images through the entire breast. Images were assessed on the workstation (Fig. 7).

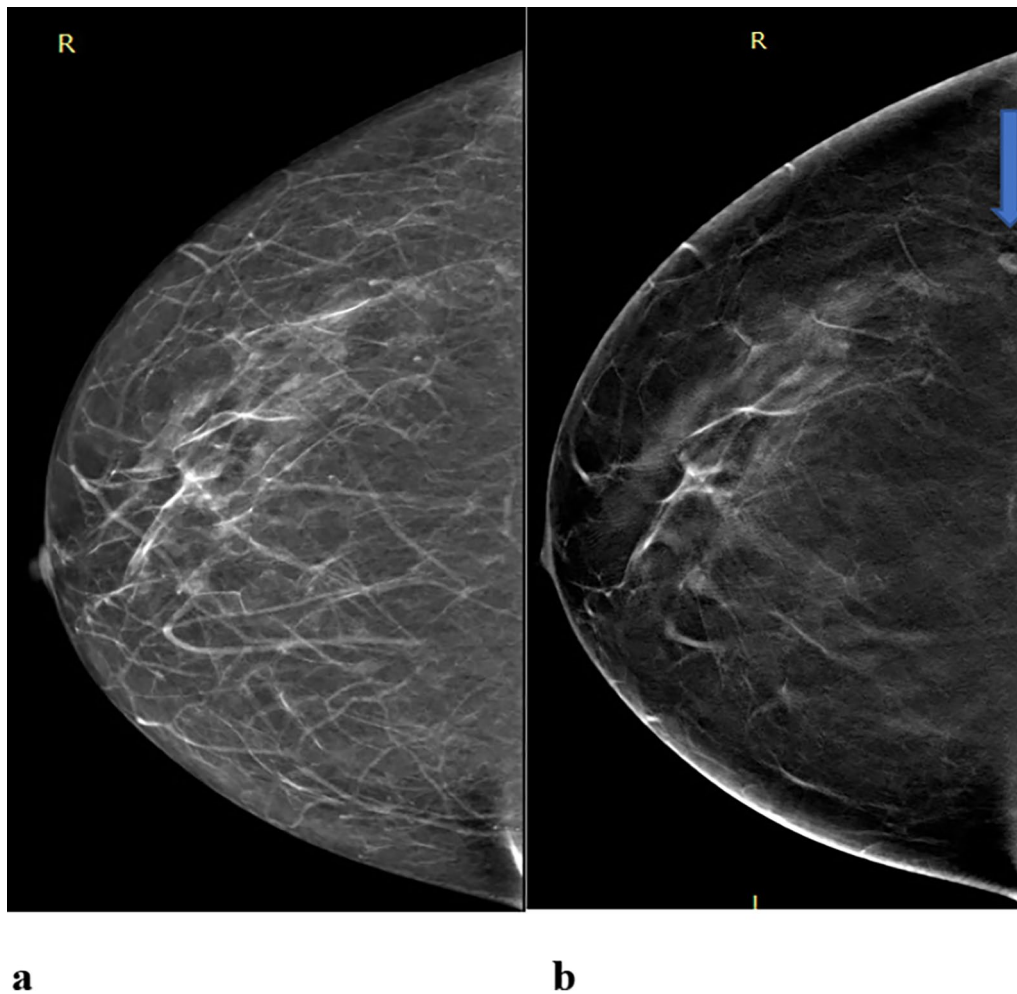
#### Image analysis and interpretation

In each case, bilateral scans were jointly reviewed by two experienced radiologists in breast imaging. All cases were categorized by age and breast density according to American College of Radiology ACR guidelines edition 2013. Each breast was evaluated about the presence of lesions or not, location, morphological type (mass, architectural distortion, focal asymmetry, macrocalcifications and microcalcifications) and for mass lesion; number, shape, density and margins were recorded using DM alone and then after adding DBT. Any founded lesion was classified according to the BIRADS lexicon 2013 classification. The obtained data were correlated with the final diagnosis

obtained by histopathological examination and close follow-up (3 follow-up studies every 6 months) (Fig. 8).

#### Statistical analysis

Results were performed using MedCalc statistical software for windows (MedCalc software, Mariakerke and Belgium). Data for continuous variables were expressed as either median, interquartile range, range of mean ( $\pm$  standard deviation) or both number and percentage for categorical data. Receiver operator characteristic (ROC) curve analysis was performed to determine the diagnostic accuracy of the various variables in distinguishing the different groups. The diagnostic accuracy of all variables was evaluated in terms of sensitivity, specificity, positive predictive value (PPV), negative predictive value (NPV) and area under the ROC curve (AUC). CHI-squared test was used for comparison of categorical data. For all tests, all *P* values were two-tailed and a *P*-value  $< 0.05$  was considered significant (Fig. 9).



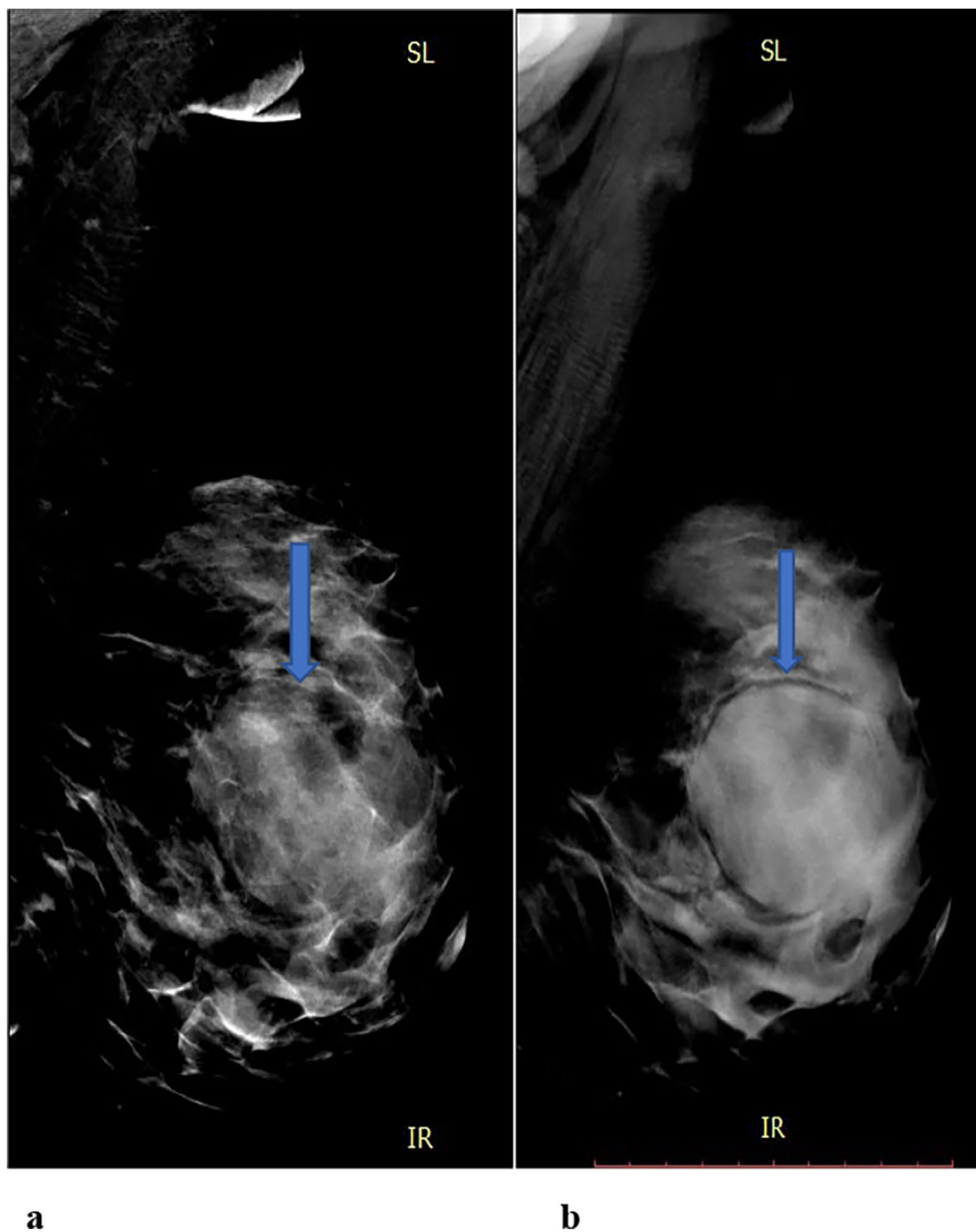
**Fig. 4** A 65-year-old female came for follow-up after left breast MRM followed by Chemotherapy and Radiotherapy. **a** CC view 2DDM of the right breast shows predominantly fatty breast (ACR a) with hardly detected lesion in outer quadrant. **b** CC view DBT of the right breast shows circumscribed oval dense mass in outer quadrant with hypo attenuated fat content. BIRADS 2, proved by histopathology to be intramammary lymph node

## Results

The current study included 38 females with 39 imaging findings. Their ages ranged from 31 to 65 years with a median of 41.5 years, an IQR of 39–49 years and a mean ( $\pm$  standard deviation) of 44 years ( $\pm$  8.91 years). Of the 38 women, predominantly fatty (ACR a), scattered fibro-glandular (ACR b), heterogeneously dense (ACR c) and extremely dense (ACR d) breasts were found in 3 (7.9%), 19 (50%), 14 (36.8%) and 2 (5.3%) women, respectively. The final diagnosis by histopathological evaluation and follow-up revealed 2 (5.1%) normal cases, 19 (48.7%) benign lesions and 18 (46.2%) malignant lesions (Fig. 10).

The distribution of the lesions according to the BIRADS score on DM and after adding DBT can be

seen in Table 1. In correlation with the final diagnosis according to the BIRADS score, the sensitivity, specificity, PPV, NPV, accuracy and AUC of DBT plus DM were 100%, 90.5%, 90%, 100%, 94.9% and 0.952, respectively, and of DM were 77.8%, 80.9%, 77.8%, 80.9%, 79.5% and 0.794, respectively. As regards TP, TN, FP and FN with the addition of DBT were 18, 19, 2 and 0, respectively, and with DM were 14, 17, 4 and 4, respectively. Moreover, adding DBT shows better overall efficacy reaching 94.9% as compared to 79.5% for DM. Pairwise comparison of AUC of both modalities revealed that the AUC with the addition of DBT was significantly larger than the AUC with DM ( $P=0.039$ ) indicating that addition of DBT was significantly more accurate than DM in



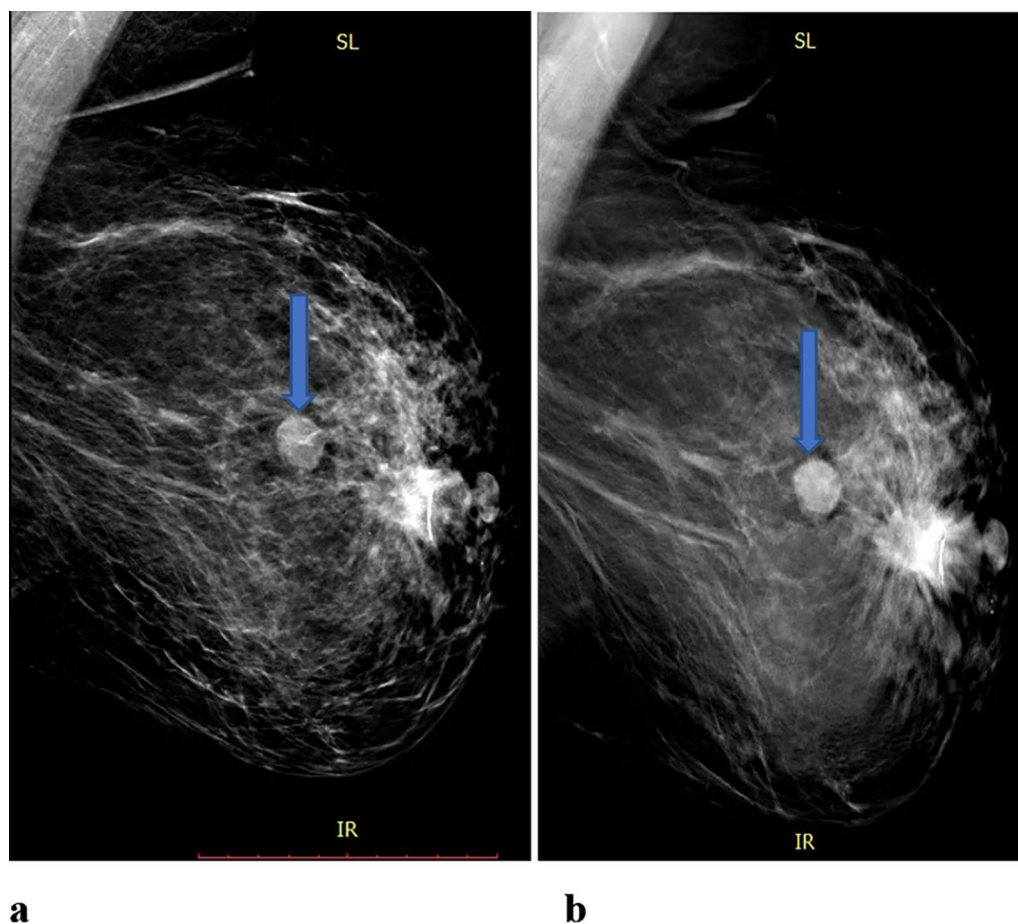
**Fig. 5** A 35-year-old female complained of left breast lump. **a** MLO view of 2DDM of left breast shows heterogeneously dense breast (ACR c), retro areolar isodense mass with indistinct borders. **b** MLO view of DBT of left breast shows circumscribed rounded dense mass in retro areolar area. BIRADS 3, proved by histopathology to be fibro-adenoma

detection and characterization of malignant and benign breast lesions according to the BIRADS score.

Out of 39 imaging findings, seven lesions were missed on DM but appeared as masses on the addition of DBT. One lesion appeared as focal asymmetry on DM but as a mass on DBT. Two lesions appeared as architectural distortion on DM but as masses on DBT. Two lesions

appeared as focal asymmetry on DM but were undetectable on the addition of DBT. One lesion appeared as focal asymmetry on DM but as architectural distortion on DBT. Otherwise the presentation of the remaining lesions was the same. This is shown in Table 2.

Regarding the performance of DBT and DM in the characterization of breast masses according to shape,



**Fig. 6** A 36-year-old female patient with known invasive ductal carcinoma of left breast subjected to new adjuvant Chemotherapy came for follow-up, **a** MLO view of 2DDM of the left breast shows Scattered fibro-glandular densities (ACR b). **b** MLO view of DBT of left breast, both modalities show the index carcinoma at areolar and peri areola position with evidence of malignancy with localizing seen in it, BIRADS 6. Another mass is detected in retroareolar area which is dense rounded with partially well-defined margins by 2DDM and which is dense irregular with partially speculated margins by DBT. BIRADS 4, proved by histopathology to be invasive ductal carcinoma so the diagnosis changed to be multifocal invasive ductal carcinoma and the decision of treatment will be changed

margins and density (Tables 3 and 4, respectively), DBT was more accurate than DM in differentiation of malignant and benign breast masses according to shape, margins and density.

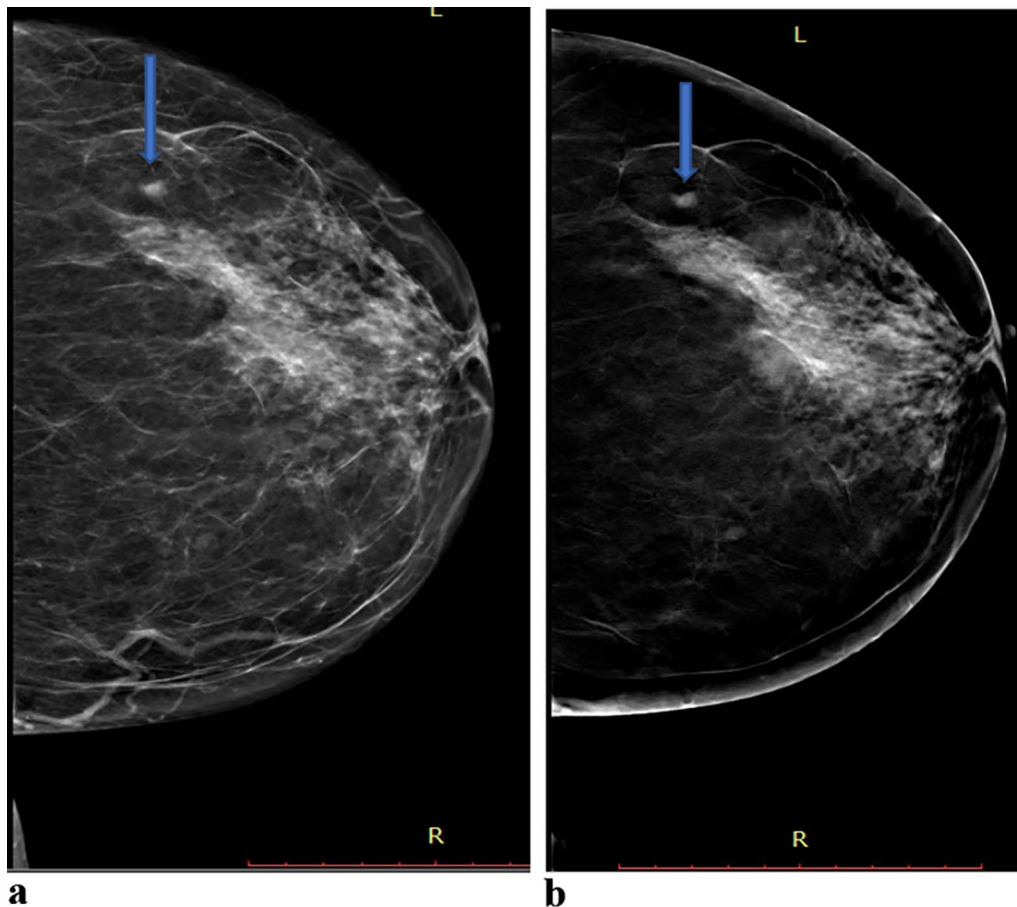
### Discussion

Despite of using FFDM in screening, it has a limitation in detection of different breast lesions as fibro-glandular tissue overlapping which is part of the nature of the imaging method makes it very difficult to distinguish abnormalities from normal anatomical structures [20]. So DBT is a modified 3D mammographic technique that overcome this limitation [14].

In our study, we compare the performance of 2DDM alone and with the addition of DBT in detection and characterization of different breast lesions in different

breast densities at different ages in females. We find out that the performance of addition of DBT is better than 2DDM alone in correlation with the final diagnosis. Out of the included 39 lesions, the sensitivity, specificity, PPV, NPV and AUC are significantly higher with the addition of DBT (100%, 90.5%, 90%, 100% and 0.952, respectively) than that with DM (77.8%, 80.9%, 77.8%, 80.9% and 0.794, respectively). TP and TN are significantly higher with the addition of DBT (18 and 19, respectively) than with DM (14 and 17, respectively). FP and FN are lower with the addition of DBT (2 and 0, respectively) than with DM (4 and 4, respectively). Moreover, adding DBT shows better overall efficacy reaching 94.9% as compared to 79.5% for DM.

The findings of our study lie in concordance with previous studies. Mall et al. [15] evaluated 144 women aged



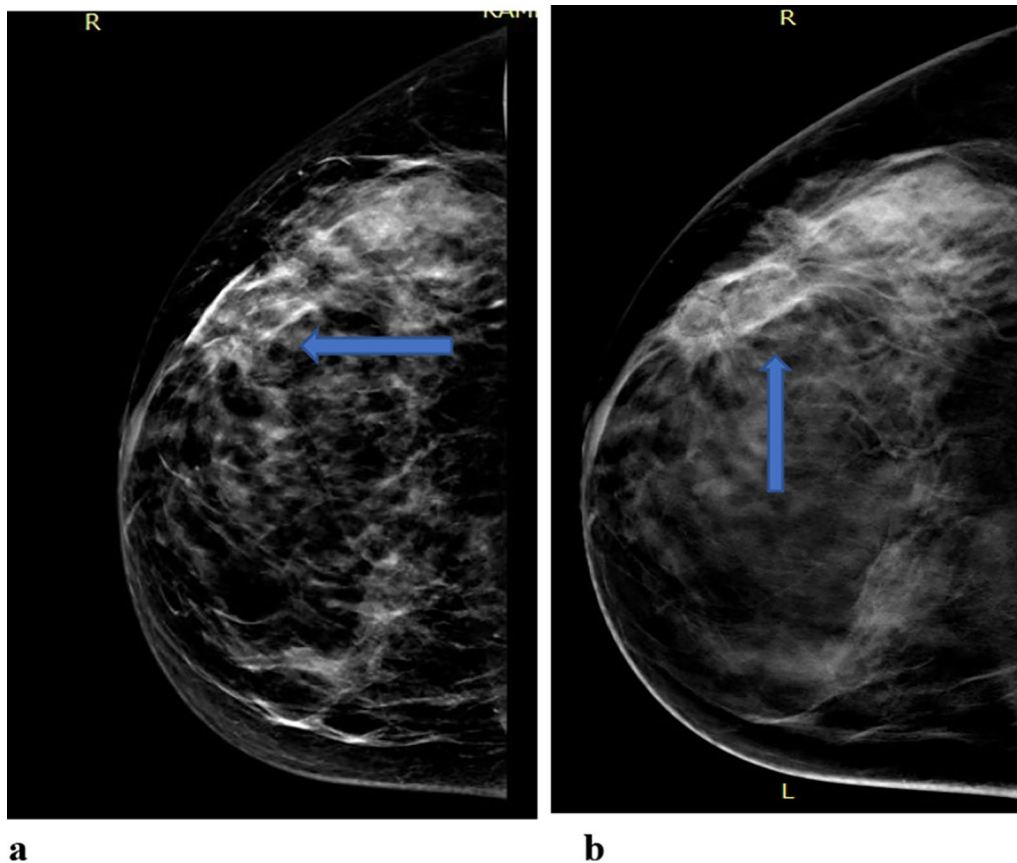
**Fig. 7** A 52-year-old female complained of left axillary mass. **a** CC view of 2DDM of the left breast shows Scattered fibro-glandular densities (ACR b). **b** CC view of DBT of the left breast. Left breast shows small irregular shaped dense mass in outer quadrant with speculated margin best appreciated in DBT. BIRADS 4, proved by histopathology to be invasive ductal carcinoma

more than 40 years in Australia and found that the sensitivity, specificity, PPV, NPV and AUC were significantly higher with the addition of DBT (93%, 75%, 64%, 96% and 0.927, respectively) than that with DM (90%, 56%, 0.49%, 92% and 0.872, respectively), TP and TN were significantly higher with the addition of DBT (226 and 375, respectively) than with DM (218 and 283, respectively) and FP and FN were lower with the addition of DBT (126 and 16, respectively) than with DM (222 and 24, respectively). Singla et al. [24] evaluated 100 women and found that the sensitivity and specificity were significantly higher with the addition of DBT (100% and 76.4%, respectively) than with DM (83.6% and 38.78%, respectively). Tucker et al. [28] evaluated 7060 women and found that the sensitivity and specificity were significantly higher with the addition of DBT (91% and 68%, respectively) than with DM (86% and 56%, respectively). Alakhras et al. [2] evaluated 50 women and found that the sensitivity, specificity and AUC were significantly

higher with the addition of DBT (70.4%, 78.3% and 0.788, respectively) than with DM (63%, 65.2% and 0.681, respectively). Gillbert et al. [10] evaluated 7060 women and found that the sensitivity, specificity and AUC were significantly higher with the addition of DBT (89%, 69% and 0.89, respectively) than with DM (87%, 58% and 0.84, respectively). Michell et al. [16] evaluated 738 women and found that the sensitivity and specificity were significantly higher with the addition of DBT (100% and 76.4%, respectively) than with DM (83.6% and 38.78%, respectively).

In contrast, Ohashi et al. [19] evaluated 628 women and found that there is no significant difference for AUC with the addition of DBT (0.9376) and DM (0.9160), also a statistically significant difference for specificity with the addition of DBT (98.9%) over DM (99.1%) but the sensitivity was significantly higher with the addition of DBT (83%) than with DM (61%). Yi et al. [31] evaluated 265 women in Korea and found that the sensitivity, specificity,





**Fig. 8** A 31-year-old female came follow-up after right breast lumpectomy. **a** CC view of 2DDM of the right breast shows Scattered fibro-glandular densities (ACR b). **b** CC view of DBT of the right breast. Right breast shows irregular dense mass in outer quadrant in relation to radial scar with speculated margins best seen in DBT. BIRADS 5, proved by histopathology to be postoperative recurrent invasive ductal carcinoma

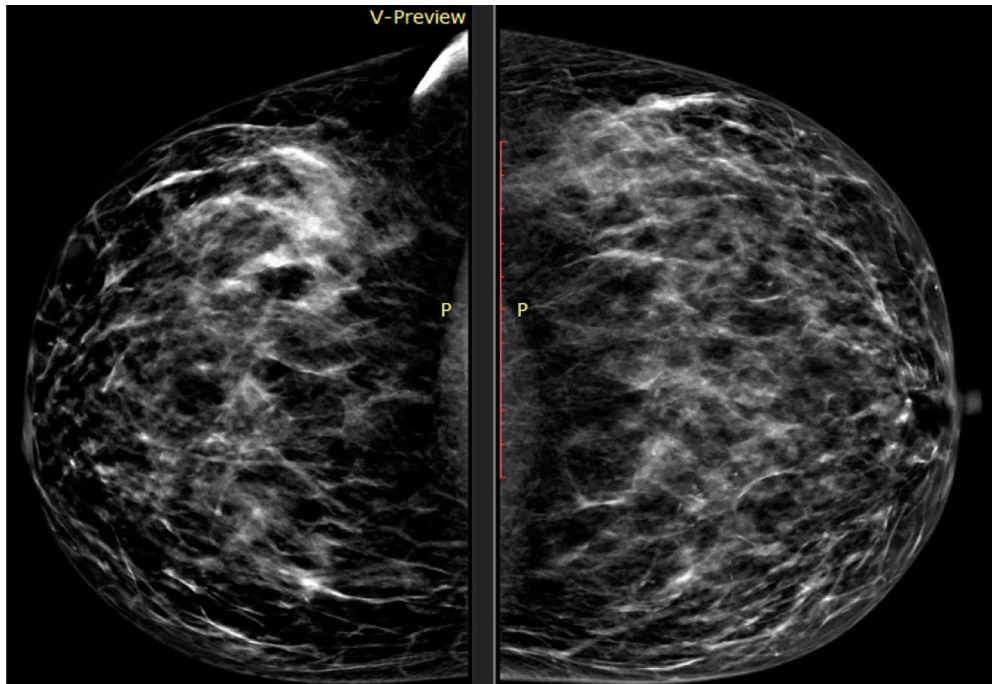
PPV and NPV were non-statistically significant with the addition of DBT in 55 women with extremely dense breast (63.6%, 84.8%, 79.2% and 90.3%, respectively) than with DM (59.1%, 75.8%, 61.9% and 73.5%, respectively), but in 210 women with other breast density they found that specificity and PPV were significantly higher with the addition of DBT (98.4% and 97.6%, respectively) than DM (90.5% and 76.8%, respectively).

In our study, the mass detection rate is higher with the addition of DBT (69.2%) than with DM (43.6%) and there is accurate detection of mass margins with the addition of DBT in comparison with DM (92.6% vs. 76.5%). This agrees with Mohindra et al. [17], Yang et al. [30], Mun et al. [18], Hakim et al. [12], Andersson et al. [4] and Poplack et al. [21] studies. Mohindra et al. [17] evaluated 164 women and found that there was statistically significant with the addition of DBT in detection of masses comparing to DM (97.6% vs. 87.6%). Also, there was statistically significant with the addition of DBT in detection of speculated margins in comparison with DM (56.5% vs. 34.7%).

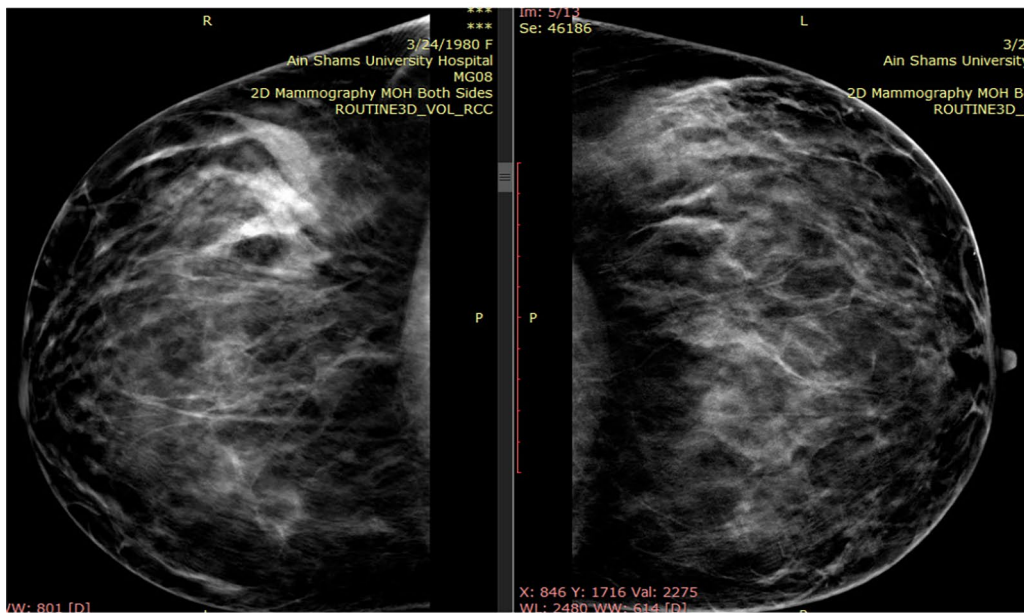
Regarding focal asymmetry in our study, one lesion appeared as focal asymmetry on DM but was detected as a mass on DBT. Two lesions appeared as focal asymmetry on DM but were undetectable on DBT (normal cases on follow-up). Our study goes with Skaane et al. [25] study, where 7 cases were categorized as normal as their lesions were obscured and 2 another normal case were categorized as focal asymmetry on DM. However, upon interrogating the DBT slices, the lesions were clearly seen, and focal asymmetry faded away.

In this study, detection and characterization of calcifications were similar with using DM or DBT. This agrees with Li et al. [13] and Chu et al. [7] in which they found that calcifications can be diagnosed using DM and DBT with similar sensitivity.

Regarding the architectural distortion in our study, two lesions appeared as architectural distortion on DM but appeared as masses on DBT. one lesion appeared as focal asymmetry on DM but presented as architectural distortion on DBT. Thus, our study agrees with Dibble et al. [9], in their study mentioned that the sensitivity

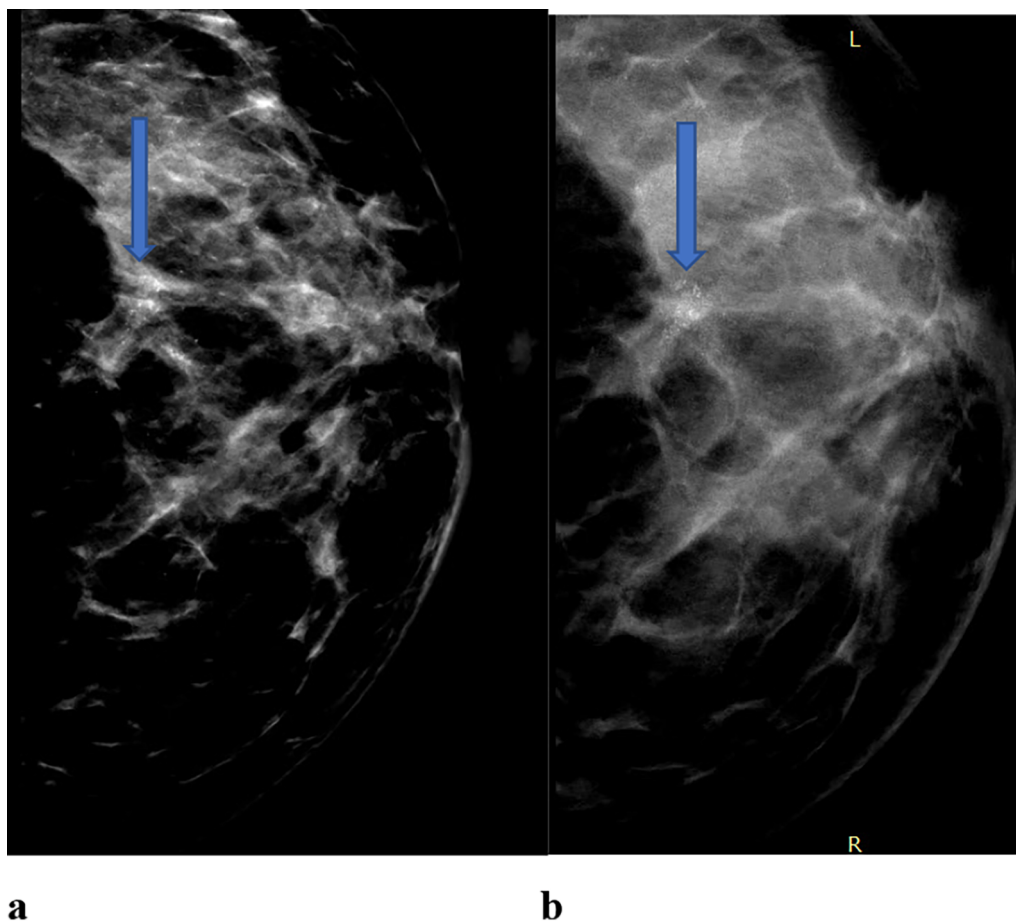


**a**



**B**

**Fig. 9** A 34-year-old female came for screening. **a** CC view of 2DDM of both breasts shows Scattered fibro-glandular densities (ACR b). **b** CC view of DBT of both breasts. Right breast shows outer quadrant focal asymmetry in 2DDM which is noted in DBT as architectural distortion. BIRADS 4, proved by histopathology to be invasive lobular carcinoma



**Fig. 10** A 34-year-old female came for screening with positive family history (first degree relatives) for breast cancer. **a** CC view of 2DDM of the left breast shows Scattered fibro-glandular densities (ACR b). **b** CC view of DBT of the left breast. The left breast shows group of fine pleomorphic microcalcification in the outer quadrant which is noted the same in both modalities. BIRADS 4, proved by histopathology to be ductal carcinoma in situ

**Table 1** Distribution of all lesions according to their BIRADS score on DM and after adding DBT

BIRADS score	DM		DBT plus DM	
	Number of lesions	Percentage	Number of lesions	Percentage
1 (normal)	7	17.9%	2	5.1%
2 (benign)	4	10.3%	9	23.1%
3 (probably benign)	10	25.6%	8	20.5%
4 (suspicious)	12	30.8%	10	25.6%
5 (highly suspicious)	6	15.4%	10	25.6%
Total	39	100%	39	100%

**Table 2** Comparison between DM and addition of DBT in detection and characterization of breast lesions

	DM		DBT	
	No	Percentage	No	Percentage
Mass	17	43.6%	27	69.2%
Focal asymmetry	5	12.8%	1	2.6%
Architectural distortion	2	5.1%	1	2.6%
Microcalcification	7	17.9%	7	17.9%
Macrocalcification	1	2.6%	1	2.6%
Normal	7	17.9%	2	5.1%
Total	39	100%	39	100%

**Table 3** Diagnostic performance of DBT in characterization of breast masses according to shape, margins and density

Mass on DBT	Pathology		Total	Sensitivity	Specificity	PPV	NPV	Accuracy	AUC
	Benign	Malignant							
<b>Shape</b>									
Irregular	3 (FP)	9 (TP)	12 (44.4%)	90%	82.4%	75%	93.3%	85.2%	0.862
Regular	14 (TN)	1 (FN)	15 (55.6%)						
<b>Margins</b>									
Speculated	2 (FP)	10 (TP)	12 (44.4%)	100%	88.2%	83.3%	100%	92.6%	0.941
Well defined	15 (TN)	0(FN)	15 (55.6%)						
<b>Density</b>									
Isodense	7(TN)	0(FN)	7 (25.9%)	100%	52.9%	55.6%	100%	70.4%	0.765
Fat density	2(TN)	0(FN)	2 (7.4%)						
Hyper-dense	8 (FP)	10 (TP)	18 (66.7%)						
Total	17 (63%)	10 (37%)	27						

**Table 4** Diagnostic performance of DM in characterization of breast masses according to shape, margins and density

Mass on DM	Pathology		Total	Sensitivity	Specificity	PPV	NPV	Accuracy	AUC
	benign	malignant							
<b>Shape</b>									
Irregular	3 (FP)	5 (TP)	8 (47.1%)	62.5%	66.7%	62.5%	66.7%	64.7%	0.646
Regular	6 (TN)	3(FN)	9 (52.9%)						
<b>Margins</b>									
Ill defined	1 (FP)	2 (TP)	3 (17.6%)						
Speculated	1 (FP)	4 (TP)	5 (29.4%)	75%	77.8%	75%	77.8%	76.5%	0.764
Well defined	7 (TN)	2 (FN)	9 (52.9%)						
<b>Density</b>									
Isodense	4 (TN)	0 (FN)	4 (23.5%)	100%	44.4%	61.5%	100%	70.6%	0.722
Hyper-dense	5 (FP)	8 (TP)	13 (76.5%)						
Total	9 (52.9%)	8 (47.1%)	17						

of detection of architectural distortion with DBT was found to outperform DM, but specificity was found to be similar between DM and DBT.

Regarding BIRADS score in our study, the addition of DBT allowed more confident up or down grading of the BIRADS score of a lesion. For example, three lesions were upgraded from BIRADS 1 to 2, three lesions were upgraded from BIRADS 1 to 3, one lesion was upgraded from BIRADS 1 to 4, two lesions were upgraded from BIRADS 3 to 4, two lesions were upgraded from BIRADS 3 to 5 and one lesion was upgraded from BIRADS 4 to 5. On the other hand, two lesions were downgraded from BIRADS 3 to 2, one lesion was downgraded from BIRADS 4 to 3 and two lesions were downgraded from BIRADS 4 to 1. This goes with Bahrs et al. [5] whom evaluated 87 patients and found that 4.6% lesions were upgraded to BIRADS 4 and 57.1% lesions were downgraded from BIRADS 3 to 1 or 2 by the addition of DBT.

Regarding recall rate in our study, there is a decrease in recall rate with the addition of DBT 5% versus 13% with DM alone. Many studies were done to compare recall rate with DM alone versus with the addition of DBT, Cohen et al. [8] evaluated 103,070 women and found significantly decrease in the recall rate with the addition of DBT 6.1% versus 7.9% with DM. Rose and Shisler [23] evaluated 59,921 women and found significantly decrease in the recall rate with the addition of DBT 10.9% versus 11.7% with DM. Alsheik et al. [3] evaluated 325,729 women and found significantly decrease in the recall rate with the addition of DBT 8.83% versus 10.98% with DM. Skaane et al. [26] evaluated 84,178 women and found significantly decrease in the recall rate with the addition of DBT 3.6% versus 6.7% with DM. Upadhyay et al. [29] evaluated 880 women and found significantly decrease in the recall rate with the addition of DBT 11.4% versus 17.4% with DM. Powell et al. [22] evaluated 12,781 women and

found significantly decrease in the recall rate with the addition of DBT 14% versus 16% with DM. In contrast, Pattacini et al. [32] evaluated 19,560 women and found that no significant decrease in the recall rate with the addition of DBT, it was the same 3.5%.

There is a limitation in our study which is a relatively small number of cases.

## Conclusions

Addition of DBT to DM helps in better detection and characterization of different breast lesions. This leads to early detection of breast cancer, improvement of the performance of radiologists and saving time by reduction of recall rate.

## Abbreviations

2DDM: Two-dimensional digital mammography; 3DDT: Three-dimensional digital tomosynthesis; ACR: American College of Radiology; AUC: Area under curve; BIRADS: Breast imaging reporting and data system; CC: Craniocaudal; DBT: Digital breast tomosynthesis; DM: Digital mammography; FFDM: Full-field digital mammography; FN: False negative; FP: False positive; MLO: Mediolateral oblique; NPV: Negative predictive value; PPV: Positive predictive value; TN: True negative; TP: True positive.

## Acknowledgements

The authors thank all the study participants for their patience and support.

## Authors' contributions

A.S (corresponding author) researched the study conception, participated in practical part, edited and revised the paper, interpreted the data, did statistical preparation, collected the references, approved the submitted version and agreed to be personally accountable for the author's own contributions.

A.M and A.E.S interpreted the data, revised the work and paper editing, approved the submitted version and agreed to be personally accountable for the author's own contributions. All authors read and approved the final manuscript.

## Funding

This study had no funding from any resource.

## Availability of data and materials

The datasets used and/or analyzed during the current study are available from the corresponding author on reasonable request.

## Declarations

### Ethics Approval and Consent to Participate:

This study was approved by the Research Ethics Committee of the Faculty of Medicine, Ain Shams University in Egypt on 26/06/2018; Reference Number of approval: FWA000017585. FMASU M.D161/2018. An informed consent was obtained from each patient.

### Consent for publication

A written informed consent was obtained from all patients included in this study for their participation.

### Competing interests

We have no competing interests to declare.

### Author details

<sup>1</sup>Egypt Ministry of Health and Population, 94 Abdelaziz Fahmy, Santfatema Square, Heliopolis, Egypt. <sup>2</sup>Radiology Department, Faculty of Medicine, Ain Shams University, Cairo, Egypt.

Received: 22 August 2021 Accepted: 30 October 2021

Published online: 09 November 2021

## References

1. Akram M, Iqbal M, Daniyal M, Khan A (2017) Awareness and current knowledge of breast Cancer. *Biol Res* 50:33
2. Alakhras M, Mello-Thoms C, Rickard M, Bourne R, Brennan P. Efficacy of digital breast tomosynthesis for breast cancer diagnosis. *Proc SPIE 9037, Medical Imaging 2014: Image Perception, Observer Performance, and Technology Assessment*, 90370V (March 11, 2014).
3. Alsheik N, Dabbous F, Pohlman S et al (2018) Comparison of resource utilization and clinical outcomes following screening with digital breast tomosynthesis versus digital mammography: findings from a learning health system. *Acad Radiol* 60068:1–9
4. Andersson I, Ikeda D, Zackrisson S, Ruschin M, Svahn T, Timberg P et al (2008) Breast tomosynthesis and digital mammography: a comparison of breast cancer visibility and BIRADS classification in a population of cancers with subtle mammographic findings. *Eur Radiol* 18:2817–2825
5. Bahrs SD, Otto V, Hattermann V et al (2018) Breast tomosynthesis for the clarification of mammographic BI-RADS 3 lesions can decrease follow-up examinations and enables immediate cancer diagnosis. *Acta Radiol* 59(10):1176–1183
6. Caleffi M, Filho D, Borghetti K et al (2004) Cryoablation of benign breast tumors: evolution of technique and technology. *Breast* 13:397–407
7. Chu A, Cho N, Chang J, Kim W et al (2017) 3D computer-aided detection for digital breast tomosynthesis: comparison with 2D computer-aided detection for digital mammography in the detection of calcifications. *J Korean Soc Radiol* 77(2):105–112
8. Cohen E, Tso H, Mayo R, Leung J (2018) Screening mammography findings from one standard projection only in the era of fullfield digital mammography and digital breast tomosynthesis. *Women's Imaging* 211(2):445–451
9. Dibble E, Lourenco A, Baird G, Ward R, Maynard A, Mainiero M (2017) Comparison of digital mammography and digital breast tomosynthesis in the detection of architectural distortion. *Eur Radiol* 28(1):3–10
10. Gillbert F, Tucker L, Gillan M et al (2015) The TOMMY trial: a comparison of tomosynthesis with digital Mammography in the UK NHS Breast Screening Programmed multicenter retrospective reading study comparing the diagnostic performance of digital breast tomosynthesis and digital mammography with di. *HealthTechnol Assess (Rockv)* 19(4):1–136
11. Hadjipanteli A, Kontos M, Constantinidou A (2019) The role of digital breast tomosynthesis in breast cancer screening: a manufacturer- and metrics-specific analysis. *Cancer Manag Res* 11:9277–9296
12. Hakim C, Chough D, Ganott M, Sumkin J, Zuley M, Gur D (2010) Digital breast tomosynthesis in the diagnostic environment: a subjective side-by-side review. *AJR Am J Roentgenol* 195:W172–W176
13. Li J, Zhang H, Jiang H et al (2018) Diagnostic performance of digital breast tomosynthesis for breast suspicious calcifications from various populations: a comparison with full-field digital mammography. *Comput Struct Biotechnol J* 17:82–89
14. Li X, Qin G, He Q, Sun L, Zeng H, He Z, Chen W, Zhen X, Zhou L (2020) Digital breast tomosynthesis versus digital mammography: integration of image modalities enhances deep learning-based breast mass classification. *Eur Radiol* 30:778–788
15. Mall S, Noakes J, Kossoff M et al (2018) Can digital breast tomosynthesis perform better than standard digital mammography work-up in breast cancer assessment clinic? *Eur Radiol* 28:5182–5194
16. Michell M, Iqbal A, Wasan R et al (2012) A comparison of the accuracy of film-screen mammography, full-field digital mammography, and digital breast tomosynthesis. *Clin Radiol* 67(10):976–981
17. Mohindra N, Neyaz Z, Agrawal V, Agarwal G, Mishra P (2018) Impact of addition of digital breast tomosynthesis to digital mammography in lesion characterization in breast cancer patients. *Int J App Basic Med Res* 8:33–37
18. Mun H, Kim H, Shin H, Cha J, Ruppel P, Oh H et al (2013) Assessment of extent of breast cancer: comparison between digital breast tomosynthesis and full-field digital mammography. *Clin Radiol* 68:1254–1259
19. Ohashi R, Nagao M, Nakamura I, Okamoto T, Sakai S (2018) Improvement in diagnostic performance of breast cancer: comparison between

- conventional digital mammography alone and conventional mammography plus digital breast tomosynthesis. *Breast Cancer* 25(5):590–596
20. Ortenzia O, Bertolini M, Nitrosi A et al (2018) Physical characterisation of four different commercial digital breast tomosynthesis systems. *Radiat Prot Dosim* 181:1–13
  21. Poplack S, Tosteson T, Kogel C, Nagy H (2007) Digital breast tomosynthesis: initial experience in 98 women with abnormal digital screening mammography. *AJR Am J Roentgenol* 189:616–623
  22. Powell J, Hawley J, Lipari A, Yildiz V, Erdal B, Carkaci S (2017) Impact of the addition of Digital Breast Tomosynthesis (DBT) to Standard 2D digital screening mammography on the rates of patient recall, cancer detection, and recommendations for short-term follow-up. *Acad Radiol* 24(3):302–307
  23. Rose S, Shisler J (2018) Tomosynthesis impact on breast cancer screening in patients younger than 50 years old. *Am J Roentgenol* 210(6):1401–1404
  24. Singla D, Chaturvedi A, Aggarwal A, Rao S, Hazarika D (2018) Comparing the diagnostic efficacy of full field digital mammography with digital breast tomosynthesis using BIRADS score in a tertiary cancer care hospital. *Indian J Radiol Imaging* 28(1):115–122
  25. Skaane P, Bandos AL, Niklason LT et al (2019) Digital mammography versus digital mammography plus tomosynthesis in breast cancer screening: the Oslo tomosynthesis screening trial. *Radiology* 291(1):23–30
  26. Skaane P, Sebuødegård S, Bandos A et al (2018) Performance of breast cancer screening using digital breast tomosynthesis: results from the prospective population-based Oslo tomosynthesis screening trial. *Breast Cancer Res Treat* 169(3):489–496
  27. Tirada M, Li G, Dreizin D, Robinson L, Khorjekar G, Dromi S, Ernst T (2019) Digital breast tomosynthesis: physics, artifacts, and quality control considerations. *Radiographics* 39:413–426
  28. Tucker L, Gilbert FJ, Astley SM et al (2017) Does reader performance with digital breast tomosynthesis vary according to experience with two-dimensional mammography? *Radiology* 283(2):371–380
  29. Upadhyay N, Soneji N, Stewart V, Ralleigh G (2018) The effect of the addition of tomosynthesis to digital mammography on reader recall rate and reader confidence in the UK prevalent screening round. *Clin Radiol* 73(8):744–749
  30. Yang T, Liang H, Chou C, Huang J, Pan H (2013) The adjunctive digital breast tomosynthesis in diagnosis of breast cancer. *Biomed Res Int* 2013:597
  31. Yi A, Chang J, Shin S et al (2018) Detection of noncalcified breast cancer in patients with extremely dense breasts using digital breast tomosynthesis compared with full-field digital mammography. *Br J Radiol*. <https://doi.org/10.1259/brj.20180101>
  32. Pattacini P, Nitrosi A, Giorgi Rossi P et al (2018) Digital mammography versus digital mammography plus tomosynthesis for breast cancer screening: the Reggio Emilia tomosynthesis randomized trial. *Radiology* 288(2):375–385

### Publisher's Note

Springer Nature remains neutral with regard to jurisdictional claims in published maps and institutional affiliations.

Submit your manuscript to a SpringerOpen<sup>®</sup> journal and benefit from:

- Convenient online submission
- Rigorous peer review
- Open access: articles freely available online
- High visibility within the field
- Retaining the copyright to your article

---

Submit your next manuscript at ► [springeropen.com](https://www.springeropen.com)

---