Algizawy *et al. Egypt J Radiol Nucl Med* (2022) 53:200
https://doi.org/10.1186/s43055-022-00888-9

Egyptian Journal of Radiology and Nuclear Medicine

RESEARCH

Open Access

Value and imaging findings of the magnetic resonance in the posterolateral corner complex injuries of the knee

Ahmed Abd El-Wahab Mahmoud Algizawy[1*], Hossam Moussa Sakr[2], Mohamed Amin Nassif[2] and Ahmed Mohamed Bassiouny[2]

Abstract

Background: MRI is considered the key tool for evaluation of knee injuries, notably the posterolateral corner, due to its complexity and multi-ligament involvement. This prospective study was conducted from September 2020 to September 2021 aiming to clarify the value and possible MRI findings in assessing the posterolateral corner (PLC) knee injuries which can subsequently result in an improvement in the management of these cases, preventing devastating consequences.

Results: The current study was conducted on 30 patients (11 females and 19 males) whose mean age was 42 years. Imaging by a closed magnet (1.5 T) MRI was applied to 30 patients with traumatic history to the knee using: axial, sagittal, coronal T1WI, T2WI, and proton density fat sat sequences. The lateral collateral ligament (LCL) was the most commonly affected ligament. Grade I injuries were the most common form of injuries. Twenty-four (80%) patients suffered from LCL injury, popliteal complex injuries were in 21 (70%) patients, 10 (33.3%) patients had biceps femoris tendon injury, while injury to the popliteofibular ligament was seen in 8 (26%) patients. The arcuate ligament was poorly defined in 6 (20%) patients, indicating that it had torn, lateral head of gastrocnemius injury was seen in 5 (16.7%) patients and 4 (13.3%) patients showed injury to the iliotibial band. Correlation with arthroscopic findings was considered the gold standard of the results whenever available. That was applied to 16 cases who had clinically significant knee injuries and arthroscopy was requested.

Conclusions: MRI is a key tool for determining a correct pre-surgical evaluation and diagnosis. It is critical to have a thorough understanding of the radiological PLC anatomy, as well as the presence of various pathologies on MRI. It allows the determination of whether the tendons and ligaments are partially or completely torn, besides any related injuries preventing possible poor consequences after the restoration of the cruciate ligaments.

Keywords: Posterolateral corner (PLC), Magnetic resonance imaging (MRI), Knee

Background

MRI has become a mainstay of clinical practice and the ideal imaging approach for diagnosing severe knee injuries, particularly those affecting the ligaments, menisci, tendons, or even muscles [1].

The PLC injuries might be difficult to diagnose initially, especially if it is part of a multi-ligamentous injury as it usually occurs in association with an anterior cruciate ligament (ACL) tear. Lack of awareness of PLC injury might delay ACL repair and modify knee biomechanics, resulting in pathologic degenerative changes [2].

The initial restriction for varus forces of the knee, along with the posterolateral rotation of the tibia in relation to the femur, is provided mainly by structures of PLC. In addition, the PLC is a crucial secondary stabilizer along

*Correspondence: a.gizawy2016@yahoo.com

[1] Ministry of Health, Cairo, Egypt
Full list of author information is available at the end of the article

with the cruciate ligaments that restrict either anterior or posterior translocation during the initial stage of flexion [3].

Static and dynamic stabilizers have been used to differentiate the PLC's supporting structures. Popliteofibular ligament (PFL), LCL, arcuate ligament, fabellofibular ligament, and posterolateral capsule are considered static stabilizers, while the iliotibial band (ITB), biceps femoris, popliteus complex, and gastrocnemius are known as dynamic stabilizers [4].

The most important anatomically supporting structure of the PLC was the LCL, popliteus tendon, and PFL [4].

Two mechanisms are accountable for PLC injury of the knee, either by tibial external rotation or by a direct hit on the tibial anteromedial aspect in a knee that is fully extended [5].

With complex multi-tendon or multi-ligament injuries, MR imaging is often used to figure out which of the PLC structures is harmed and to what extent it also can specify the injury grade or extend plus identify if there is a surgical lesion [6].

MRI can classify injuries as follows:

- First, strains that mainly involve preserved ligament or tendon fibers with nearby edema.
- Second, partial tears of hyperintensity and instability of the muscle portions, tendons, or ligaments.
- Third, complete rupture.

These findings often correlate with the clinical features of grade I, II, and III injuries [7].

Our study aimed to highlight the potential role and possible findings of MRI of patients with PLC injuries of the knee and subsequently better post-management results.

Methods

This study was conducted prospectively from September 2020 to September 2021 aiming for evaluating the role of imaging by MR in the assessment of the PLC injuries of the knee. This study was approved by our University ethics committee, and signed informed consents were obtained from all the patients (before being enrolled in the study), and the study was performed on 30 patients who were susceptible to knee trauma and referred from the orthopedic department to exclude suspected PLC injuries.

Inclusion criteria

Patients suffering from recent knee trauma either by direct force applied to the knee or twisting knee injury.

Exclusion criteria

Patients with age less than 18 years old, history of surgical intervention of the knee or non-traumatic knee pain.

All MRI examinations were conducted through Philips Achieva using a 1.5 T closed magnet. Patients were examined in a supine position with foot first entry. The patient's knees were adequately positioned in the extremity coil and supported by foam pads to avoid mal-alignment.

Correlation with arthroscopic findings was considered the gold standard of the results whenever available. That was applied to 16 cases only who had clinically significant knee injuries and arthroscopy was requested. MRI was considered the gold standard of the remaining cases.

MR imaging protocol

The MR imaging protocol as well as its parameters (Table 1) is made up of three scout planes: sagittal (T1WI, T2WI, and proton density with fat suppression), axial (T2WI and proton density with fat suppression), and coronal proton density with fat suppression.

MRI interpretation and systematic reporting

MR images were evaluated by two experienced radiologists with 8 and 12 years of experience in musculoskeletal imaging. Image reporting was done independently with inter-observer agreement from 92 to 95%. Images were analyzed using a dedicated workstation (Philips IntelliSpace) and post-processing software.

Evaluation of the presence of injury of different PLC structures includes the following:

- Lateral collateral ligament.
- Popliteus muscle complex.
- Conjoined tendon.
- Biceps femoris tendon.
- Lateral head of the gastrocnemius.

Table 1 MR imaging parameters used in the study

Pulse sequences	T1WI	T2WI	PDFS
TR	500 ms	3000 ms	1000 ms
TE	20 ms	100 ms	15–25 ms
Slice thickness	4 mm	4 mm	4 mm
Interslice gap	0.3 mm	0.3 mm	0.3 mm
FOV	200 mm	200 mm	200 mm

TR repetition time, *TE* echo time, *FOV* field of view, *PDFS* proton density with fat suppression

- Popliteofibular ligament.
- Iliotibial band.

The injury of the main PLC structures including the lateral collateral ligament, popliteus muscle complex, and conjoined tendon was graded into I, II, and III according to the severity of the injury. Evaluation of the different associated bony and soft tissue injuries on MRI sequences including the cruciate ligaments as well as collateral ligaments and menisci was also carried out.

Statistics analysis

Data were analyzed using IBM SPSS Corp. Released 2013. IBM SPSS Statistics for Windows, Version 22.0. Armonk, NY: IBM Corp. Statistical data analysis was accomplished using the mean, and standard deviation using the chi-square test. A p value of 0.05 or less was used for statistical significance description.

Results

This prospective study was conducted on 30 patients (11 females, 19 males) whose age ranged from 18 to 60 years (with a mean age of 42.63 years). Trauma history was positive in all patients.

Non-contact external rotation was the most frequent mechanism of injury targeting the PLC, which was detected in 20 (66.7%) patients, while 10 (33.3%) patients were exposed to the other mechanism by direct hit or forces to the tibial anteromedial aspect in a fully extended knee.

As demonstrated in Fig. 1, 20 (66.66%) patients showed multiple injured structures of the posterolateral corner at the same incident, while 10 (33.33%) patients had only one injured structure of the PLC structures at a time including either the lateral collateral ligament (80%) or the popliteus musculotendinous complex (20%).

In this study, the most affected structure of the PLC by trauma was the LCL which was injured in 80% of the patients, followed by popliteus myotendinous complex and biceps femoris tendon in 70% and 33.3% of the patients, respectively (Table 2) (Fig. 2).

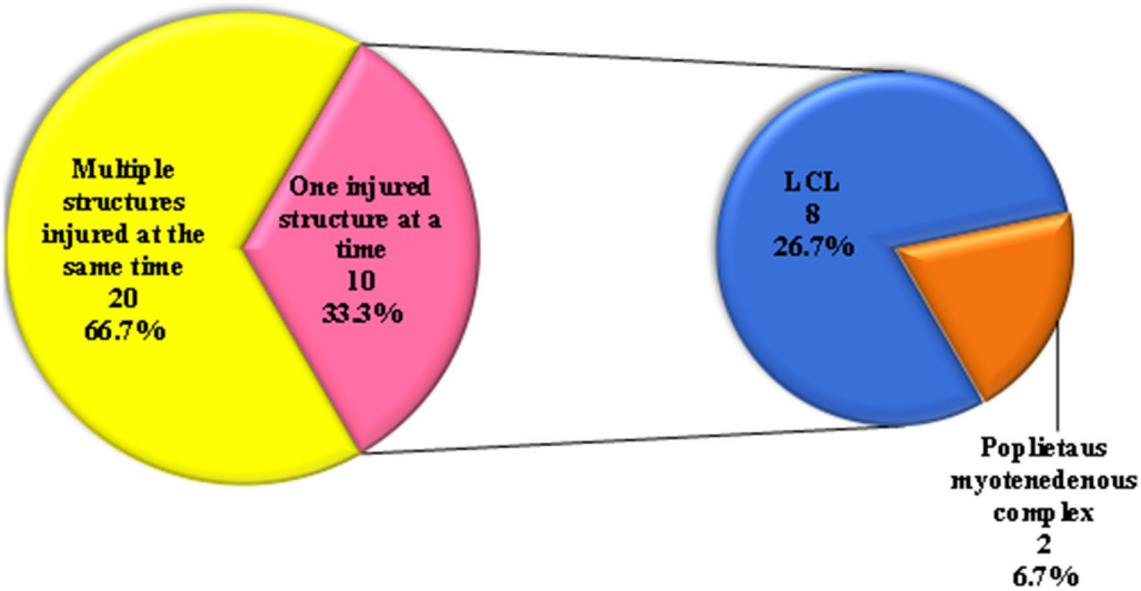

Fig. 1 Incidence of different single and multiple PLC corner structures injured in our studied cases

Table 2 Incidence of different PLC structures affected in all PLC-injured studied cases

Injured structure	Lateral collateral ligament (LCL)	Popliteus myotendinous complex	Biceps femoris tendon	Popliteofibular ligament	Arcuate ligament	Lateral head of gastrocnemius muscle	Iliotibial band
NO	24	21	10	8	6	5	4
%	80	70	33.3	26	20	16.7	13.3

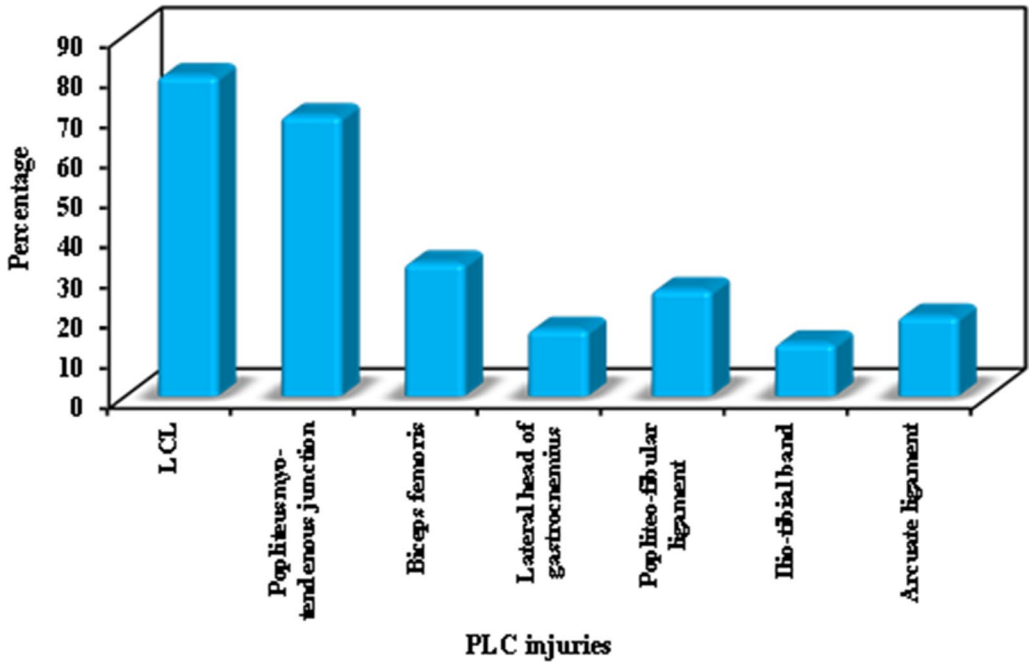

Fig. 2 Incidence of different PLC structures affected in all PLC-injured studied cases

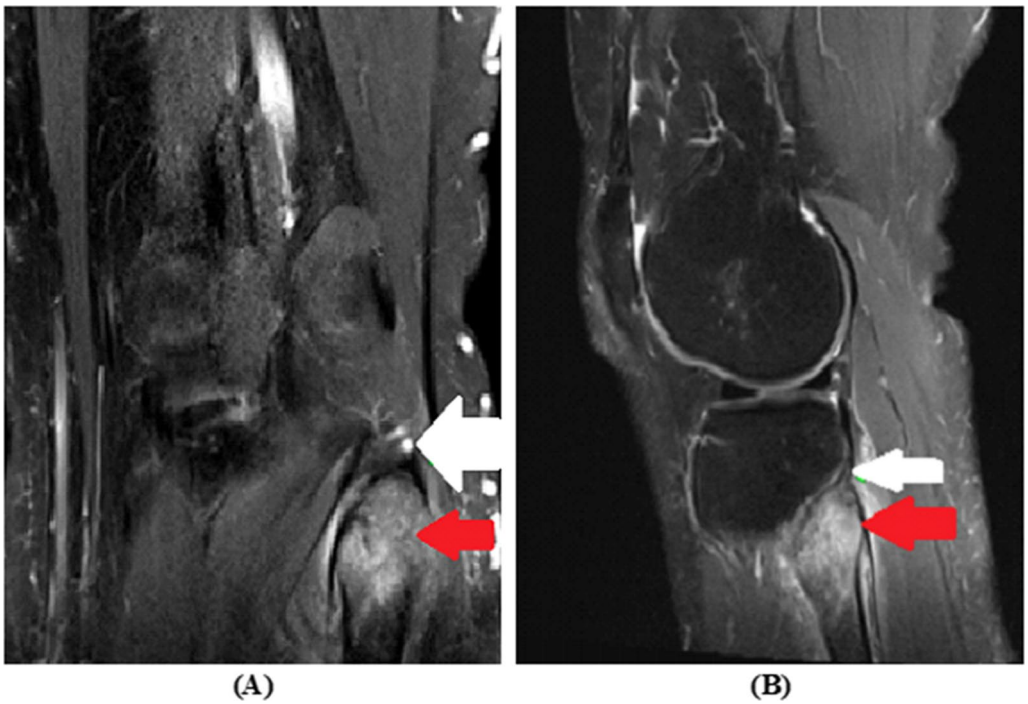

Fig. 3 A 43-year-old female patient suffering from instability and pain of the left knee following recent trauma by direct force applied to the knee. Sagittal and coronal PDFS images (**A**, **B**) showing marrow contusions of the fibular head suggestive of arcuate fracture (red arrow) with partial tear of the popliteofibular ligament (white arrow)

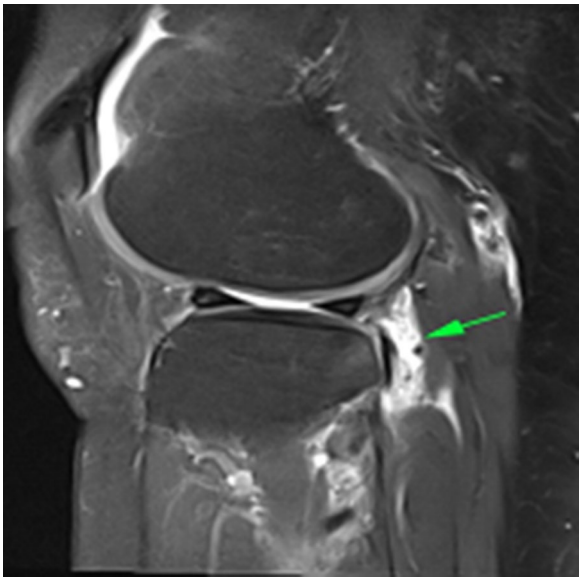

Fig. 4 A 56-year-old female patient suffering from instability and pain of the left knee following a recent twisting injury. Sagittal PDFS image revealing an absence of well-defined arcuate ligament right behind the popliteus tendon, indicating possible tear

Table 3 Incidence of different PLC structures affected in relation to mechanism of trauma

	Rotational injury	Direct force	Total
LCL			24
Partial tear	14	4	14
Complete tear	1	3	4
Avulsion	1	1	2
Popliteus			21
Partial tear	14	3	17
Complete tear	0	2	2
Avulsion	1	1	2
Biceps femoris tendon			10
Partial tear	7	1	
Complete tear	0	2	
Popliteofibular ligament	6	2	8
Arcuate ligament	4	2	6
Lateral head of gastrocnemius muscle	3	2	5
Iliotibial band	2	2	4
Total	53	25	

* More than one patient had complex injury (more than one structure involved)

- Eight (26%) patients had PFL injury shown as an intermediate signal in PDFS (Fig. 3),
- Six (20%) patients showed ill-definition of the arcuate ligament (Fig. 4) suggesting its tear.
- Five (16.7%) patients showed injury in the lateral head of gastrocnemius muscle, and lastly only 4 (13.3) patients had injury to the iliotibial band.

It was found that non-contact external rotation mechanism is related to grade I and II injuries (partial tear), while most of the severe cases (complete tear) are commonly seen in cases prone to direct force applied to the knee mechanism (Table 3).

Regarding the incidence of different patterns of LCL injuries, 75% of LCL injuries showed intra-substance tear or sprain (Fig. 5), 16.6% showed a complete tear and discontinuity of the lateral collateral ligament fibers (Fig. 6), and 8.3% showed avulsion from the femoral condyle (Fig. 7) (Table 4).

Regarding the incidence of different patterns of popliteus myotendinous complex injuries, 80.9% of the popliteus myotendinous complex injuries showed intra-substance MRI signal denoting strain (Fig. 5). 9.5% showed a complete tear and discontinuity of the popliteus myotendinous complex fibers (Fig. 6), and a similar number showed avulsion from the femoral attachment (Fig. 7) (Table 4).

Regarding biceps femoris tendon injuries, 80% of the biceps femoris injured patients showed a partial tear and intra-substance strain in the biceps femoris tendon (Fig. 8), a complete tendinous tear was encountered in only 20% of the patients with biceps femoris tendon injury (Fig. 6), while avulsion of the tendinous insertion was not encountered in our study (Table 4).

In the 16 cases who underwent arthroscopy, the main PLC structures were assessed, and it was found that the endoscopic findings were matching with MRI findings in the cases of a complete tear, while MRI was superior in the detection of structures with grade I and II injuries (partial tear) (Tables 5, 6, and 7).

Discussion

Because of the excellent soft tissue evaluation of MRI in detecting various meniscal and ligamentous abnormalities, it is considered the first line of diagnosis of injuries of the knee with an emphasis on post-traumatic sequel (instability). Radiologists have to be familiar with the various characteristic MRI appearances of the various structures forming the PCL of the knee to be able to diagnose their injuries in favor of better management and functional outcomes in particular if the injury was not clinically suspected, especially those with concomitant ACL or PCL injuries that require reconstruction [6].

Regarding the mechanisms of injury targeting the PCL of the knee, we found that 20 (66.7%) patients were subjected to non-contact external rotation, and 10 (33.3%)

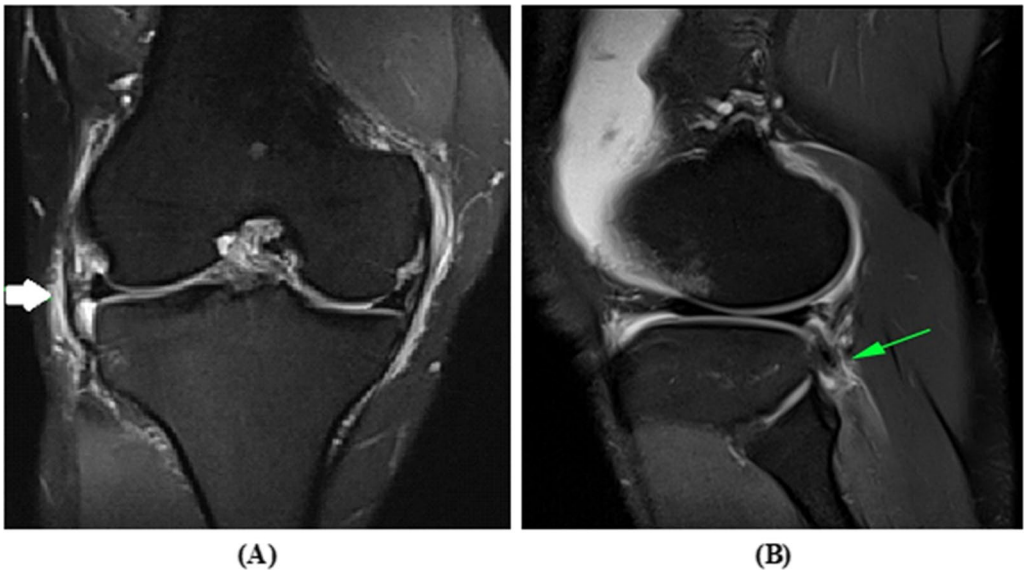

Fig. 5 A 31-year-old male patient suffering from instability and pain of the right knee following a twisting injury. Coronal PDFS (**A**) showing grade II injury of the LCL. Sagittal PDFS (**B**) showing partial tear of the popliteo-tendinous complex

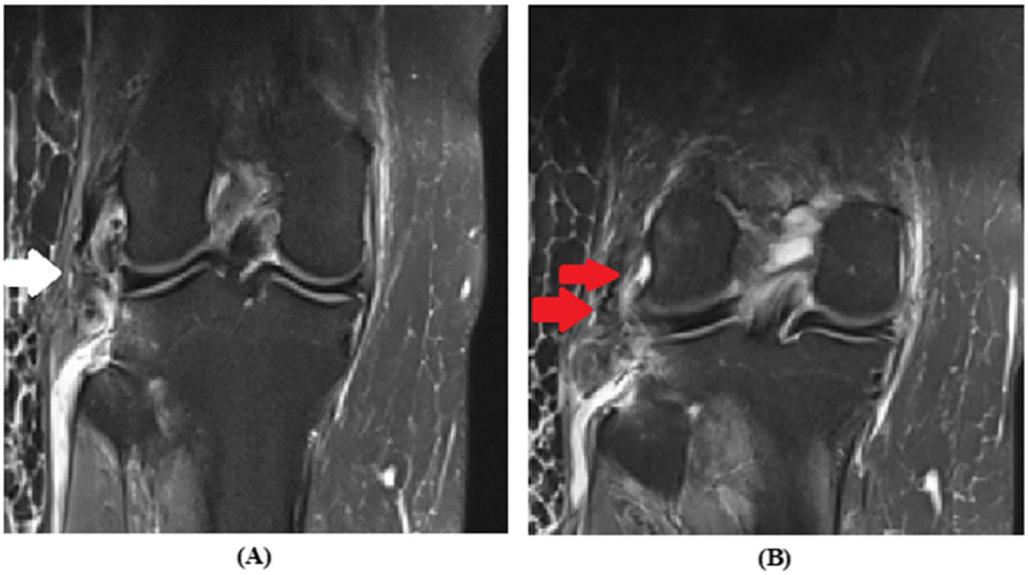

Fig. 6 A 28-year-old male patient suffering from instability and pain of the left knee following a twisting injury. Coronal PDFS image (**A**) and (**B**) showing complete tear of the LCL, biceps femoris tendon, as well as the popliteus tendon near its fibular insertion

patients were exposed to direct hit applied on the tibial anteromedial aspect in a fully extended knee.

These results agreed with Rosas et al. [7] who proposed that these injuries are caused either as a result of direct impacts applied to the tibial anteromedial aspect in a hyperextended knee or by non-contact hyperextension of the knee with external rotation.

Regarding the incidence of either different single or multiple PCL structures injured in our study, 66.66% of the patients showed multiple injured structures of the PCL at the same incident, while only 33.33% of the patients had only one injured structure of the PLC structures at a time including either the LCL or the popliteus musculotendinous complex.

Fig. 7 A 43-year-old male patient suffered instability and swelling, and pain of the right knee following a road traffic accident. Coronal PDFS image showing avulsion fracture of the lateral femoral condyle at the site of attachment of the LCL and popliteal tendon

These findings agreed with Essilfie et al. [8] who stated that the PLC is rarely injured in isolation and commonly seen in association with multi-ligamentous injury of the knee.

Close results were also found by Laprade et al. [9] who stated that injuries of the PLC were combined injuries of the ligaments and tendons in 72–87%.

Our study depicted that the LCL in addition to the popliteus musculotendinous complex and biceps femoris tendon forms the essential stabilizing structures for the integrity of the PLC of the knee; and also, the most common structures to be injured constitute about 80%, 70%, and 33.33%, respectively.

These results agreed with Aga M et al. [10] who found that injuries of the LCL are the most common injured structure of the PLC representing (22.3%) of the patients, followed by the iliotibial band (11.3%), biceps tendon (5.9%), and popliteus muscle (5.3%).

These results were also agreed with Theodorous et al. [11] who found LCL injury in all (100%) of the patients in their study, followed by biceps femoris tendon injuries representing 79% of the patients and popliteus musculotendinous complex injury in 36% of the patients.

Collins et al. [12] also found that 100% of the patients in their study had injury to the LCL, followed by injuries to the popliteus muscle and tendon in 95% of the patients, while 77.3% of the patients had injury to the biceps femoris tendon.

Regarding the incidence of different patterns of LCL injuries, 18 (75:00%) of the LCL injured patients in our study showed intra-substance tear or sprain, 4 (16.6%) showed a complete tear and discontinuity of the LCL fibers, and 2 (8.3%) patients showed avulsion from the femoral condyle.

Compared to Kohan et al. [13], our findings were quite different regarding the LCL injuries as their study showed avulsion injury to the LCL either from the fibula or from the femur in 85% of their cases, while sprain of the LCL was only found in 15%.

Colins et al. [12] also found different results, 86.4% of the LCL injuries showed complete tear, while 13.6% showed sprain injury partial tear, 50% of the biceps femoris injuries showed complete tear, while 27.3% showed sprain injury partial tear.

These differences with their higher numbers of avulsion injuries may be attributed to their selection bias including only patients who underwent surgical intervention.

Conclusions

MRI is becoming the first line in traumatic knee injuries directing diagnosis and evaluation of pre-surgical PLC management determining a correct pre-surgical evaluation and diagnosis of PLC injuries.

It allows the determination of whether the tendons and ligaments are partially or completely torn, besides any related injuries preventing possible poor consequences after the restoration of the cruciate ligaments. Proton density with fat suppression (PDFS) is the sequence of choice in detecting PLC injuries of the knee even in minor ligament insults. Cruciate ligament

Table 4 Correlation between different patterns of injury of the commonly encountered PLC structures

Type of structure injured	Fibular (lateral) collateral ligament injury		Popliteus myotendinous complex		Biceps femoris tendon injury	
Patterns of injury	**No.**	**%**	**No.**	**%**	**No.**	**%**
1. Sprain/intra-substance tear	18	75	17	80.9	8	80
2. Complete tear	4	16.6	2	9.5	2	20
3. Avulsion	2	8.3	2	9.5	0	0
Total number of injuries	24	100	21	100	10	100

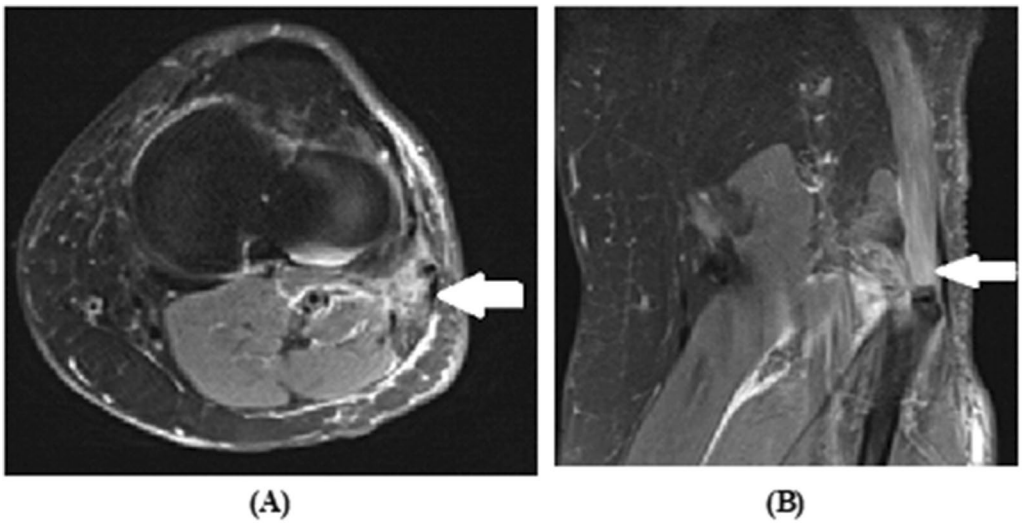

Fig. 8 A 56-year-old female patient suffering from instability and pain of the left knee following a recent twisting injury. Axial and sagittal PDFS images (**A**, **B**) showing hyperintense signal within the biceps femoris muscle and tendon denoting grade I–II injury

Table 5 Agreement (sensitivity, specificity, and accuracy) for LCL ($n = 16$)

LCL	Surgical				Sensitivity	Specificity	PPV	NPV	Accuracy
	Negative ($n = 10$)		Positive ($n = 6$)						
	No.	%	No.	%					
MRI									
Negative	0	0.0	0	0.0	100.0	0.0	37.50	–	37.50
Positive	10	100.0	6	100.0					
χ^2 (p)	–								

χ^2 chi-square test, *p p* value for association between different categories, *PPV* positive predictive value *NPV* negative predictive value

Table 6 Agreement (sensitivity, specificity, and accuracy) for popliteus tendon ($n = 16$)

Popliteus tendon	Surgical				Sensitivity	Specificity	PPV	NPV	Accuracy
	Negative ($n = 12$)		Positive ($n = 4$)						
	No.	%	No.	%					
MRI									
Negative	7	58.3	0	0.0	100.0	58.33	44.44	100.0	68.75
Positive	5	41.7	4	100.0					
χ^2 (^{FE}p)	$\chi^2 = 4.148$ ($^{FE}p = 0.088$)								

χ^2 chi-square test, *FE* Fisher's exact, *p p* value for association between different categories, *PPV* positive predictive value, *PV* negative predictive value

and meniscus injuries should be highly suspected if PLC injury was detected. LCL in addition to the popliteus musculotendinous complex and biceps femoris tendon is the most common structure to be injured.

Recommendations

The main limitation of this study is the short duration and relatively limited number of patients, so we recommend more studies to be conducted upon a larger

Table 7 Agreement (sensitivity, specificity, and accuracy) for biceps femoris tendon ($n = 16$)

Biceps femoris tendon	Surgical				Sensitivity	Specificity	PPV	NPV	Accuracy
	Negative ($n = 14$)		Positive ($n = 2$)						
	No.	%	No.	%					
MRI									
Negative	9	64.3	0	0.0	100.0	64.29	28.57	100.0	68.75
Positive	5	35.7	2	100.0					
χ^2 (^{FE}p)	$\chi^2 = 2.939$ ($^{FE}p = 0.175$)								

χ^2 chi-square test, *FE* Fisher's exact, *p p* value for association between different categories, *PPV* positive predictive value *NPV* negative predictive value

number of patients, aiming to increase the accuracy of the MRI, pushing it to become the sole gold standard in the evaluation of traumatic knee injuries as a noninvasive tool.

Abbreviations
ACL: Anterior cruciate ligament; LCL: Lateral collateral ligament; PFL: Popliteofibular ligament; PLC: Posterolateral corner; MR: Magnetic resonance; MRI: Magnetic resonance imaging; PDFS: Proton density fat suppression; PCL: Posterior cruciate ligament; ITB: Iliotibial band.

Acknowledgements
Not applicable.

Author contributions
AA designed the study and performed data collection and analysis. MN, HS, and AB supervised all procedures and data interpretation. AA wrote the manuscript. All authors read and approved the final manuscript.

Funding
No funding disclosures or support to make with regards to this study.

Availability of data and materials
The data that support the findings of this study are available from the Radiology Department of Ain Shams University but restrictions apply to the availability of these data, which were used under license for the current study, and so are not publicly available. Data are, however, available from the authors upon reasonable request and with permission of the Radiology Department of Ain Shams University.

Declarations

Ethics approval and consent to participate
Ain Shams University Review Board and Ethical Committee approved the current work. Patients received a thorough explanation of the study design and aims, and informed written consents were obtained from them before any intervention.

Consent for publication
Not applicable.

Competing interests
No competing interests exist.

Author details
[1]Ministry of Health, Cairo, Egypt. [2]Ain Shams University, Cairo, Egypt.

Received: 16 February 2022 Accepted: 29 August 2022
Published online: 05 September 2022

References

1. Marconi GF, Simão MN, Fogagnolo F, Nogueira-Barbosa MH (2021) Magnetic resonance imaging evaluation of common peroneal nerve injury in acute and subacute posterolateral corner lesion: a retrospective study. Radiol Bras 54:303–310
2. Lee SY, Choi YJ, Park HJ et al (2019) Types of posterolateral corner injury associated with both bundle and selective-bundle ACL tears. Acta Radiol 60(12):1629–1635
3. Chahla J, Moatshe G, Dean CS, LaPrade RF (2016) Posterolateral corner of the knee: current concepts. Arch Bone Jt Surg 4(2):97
4. Shon O-J, Park J-W, Kim B-J (2017) Current concepts of posterolateral corner injuries of the knee. Knee Surg Relat Res 29(4):256
5. Geiger D, Chang EY, Pathria MN, Chung CB (2014) Posterolateral and posteromedial corner injuries of the knee. Magn Reson Imaging Clin N Am 22(4):581–599
6. Vinson EN, Major NM, Helms CA (2008) The posterolateral corner of the knee. Am J Roentgenol 190(2):449–458
7. Rosas HG (2016) Unraveling the posterolateral corner of the knee. Radiographics 36(6):1776–1791
8. Essilfie AA, Alaia EF, Bloom DA et al (2022) Distal posterolateral corner injury in the setting of multiligament knee injury increases risk of common peroneal palsy. Knee Surg Sports Traumatol Arthrosc 30(1):239–245
9. LaPrade RF, Ly TV, Griffith C (2008) The external rotation recurvatum test revisited: reevaluation of the sagittal plane tibiofemoral relationship. Am J Sports Med 36(4):709–712
10. Agha M (2017) MRI of the posterolateral corner of the knee, please have a look. Alex JMed 53(3):261–270
11. Theodorou D, Theodorou S, Fithian D, Paxton L, Garelick D, Resnick D (2005) Posterolateral complex knee injuries: magnetic resonance imaging with surgical correlation. Acta Radiol 46(3):297–305
12. Collins MS, Bond JR, Crush AB, Stuart MJ, King AH, Levy BA (2015) MRI injury patterns in surgically confirmed and reconstructed posterolateral corner knee injuries. Knee Surg Sports Traumatol Arthrosc 23(10):2943–2949
13. Kahan JB, Li D, Schneble CA et al (2020) The pathoanatomy of posterolateral corner ligamentous disruption in multiligament knee injuries is predictive of peroneal nerve injury. Am J Sports Med 48(14):3541–3548

Publisher's Note