ElSayed *et al. Egypt J Radiol Nucl Med* (2022) 53:232
https://doi.org/10.1186/s43055-022-00907-9

Egyptian Journal of Radiology and Nuclear Medicine

RESEARCH

Open Access

MR imaging biomarkers for evaluation of adhesive capsulitis of the shoulder. Additive value of anterior capsule abnormality as a reliable criterion for diagnosis of adhesive capsulitis: a cross sectional analytic study

Mennatallah ElSayed[1*], Moustafa Raafat Mahmoud Hafez[2] and Heba Kamal[1]

Abstract

Background: Adhesive capsulitis of the shoulder is a pain syndrome of progressive nature, associated with reduced active and passive range of motion of the gleno-humeral joint. Previous studies suggested an underlying synovial inflammatory process, followed by capsular hypertrophy and reactive fibrosis. The aim of our study was to investigate the influence of anterior shoulder joint capsule abnormal thickening and abnormal signal intensity on MRI, as important imaging biomarkers, for the diagnosis of as adhesive capsulitis.

Results: This cross sectional analytic study involved 28 patients with adhesive capsulitis ((17 males, 11 females, age range:23–65 years, mean age: 45.61 years ± 11.95) and 28 controls (14 males, 14 females; age range, 39 to 61 years; mean age 52.82 years ± 6.45;). The patients and the controls were reviewed by two radiologists with experience of more than 10 years, blinded to each other's results. Adhesive capsulitis was diagnosed based on clinical criteria of significant restricted passive motion of shoulder joint. The thickness and abnormal signal intensity of anterior glenohumeral joint capsule were evaluated at its thickest portion, positioned underneath the subscapularis muscle. Additionally, the formerly known MR characteristics of adhesive capsulitis, involving the thickness of humeral and glenoid portions of axillary recess, maximal thickness of axillary capsule, and thickness of coracohumeral ligament, were assessed. The estimation of abnormal hyperintensity of humeral and glenoid capsule in axillary recess, subcoracoid fat triangle obliteration and abnormal hyperintensity were also included in our study. All magnetic resonance imaging (MRI) quantitative values showed significant difference between adhesive capsulitis group and control group. Regarding qualitative values, only abnormal high signal intensity of the anterior portion of joint capsule, of the axillary portion of joint capsule and of glenoid portion of axillary capsule showed statisticaly significant difference between cases and controls. In receiver operating characteristic (ROC) curve study, the anterior capsule thickness revealed a high diagnostic value with an area under the curve (AUC) of 1.0. An anterior capsule thickness cut off value of at 2.45 mm showed a very high diagnostic performance, revealing a sensitivity of and specificity of 100%.

*Correspondence: mennaelsayed22@yahoo.com

[1] Department of Diagnostic and Interventional Radiology, Faculty of Medicine, Cairo University Kasr Alainy, 8 Ahmed eElshediak Street, Ard Elgolf, Heliopolis, Cairo, Egypt
Full list of author information is available at the end of the article

Conclusions: The anterior glenohumeral joint capsule abnormal thickening, and abnormal hyperintensity have a high diagnostic performance, in addition to the previously known abnormal MRI findings, in the evaluation of adhesive capsulitis.

Keywords: Anterior joint capsule abnormal signal, Adhesive capsulitis of the shoulder, Passive range of motion, Anterior joint capsule increased thickness, Anterior joint capsule abnormal increased intensity

Background

Adhesive capsulitis, otherwise known as frozen shoulder, is known by the American Academy of Orthopaedic Surgeons to represent a disorder of variable severity, where the patient develops gradual global limitation of active and passive shoulder movements. The radiological findings usually are normal and only bony osteopenia can be seen. The limitation of passive shoulder motion is a key clinical finding to shaping a frozen shoulder diagnosis. In other shoulder pathologies, such as subacromial bursitis, calcific tendinitis and partial rotator cuff tears, there is usually severe pain and reduced active range of motion, however, passive range of motion is maintained, unless these conditions were complicated by secondary adhesive capsulitis. Adhesive capsulitis is associated with growing pain and inflammation, which leads to progressive edema and stiffness of the soft and connective tissues of the shoulder with the formation of fibrous adhesions that markedly limit the range of movement of the joint. If this condition is left without treatment, marked pain and functional disability can be the outcome [1].

MRI is frequently used as an investigation tool for evaluation of shoulder pathologies and for non-invasive characterization of abnormalities in the synovium and shoulder joint capsule, which are typical features of frozen shoulder [2]. MRI can also help to disregard other causes of shoulder pain and dysfunction that can simulate adhesive capsulitis [3]. Many studies revealed that MRI is dependable for investigating characteristic abnormal signs for adhesive capsulitis, including coracohumeral ligament thickening, capsular thickening, axillary recess enhancement, rotator interval enhancement, and subcoracoid fat triangle obliteration [4, 5].

From a pathophysiological point of view, of adhesive capsulitis includes synovium inflamation, fibrosis of the subsynovial structures, with fibrosis and thickening of the joint capsule, leading finally to contracture of glenohumeral joint [6, 7]. Previous arthroscopic examinations have revealed increased thickness of the anterior portion of the shoulder joint capsule, involving glenohumeral ligament [8]. In order to regain the range of movement, it is important to involve the anterior portion of joint capsule in the arthroscopic capsulotomy [9].

In literature, previous studies have shown abnormal magnetic resonance findings for coracohumeral ligament, superior glenohumeral ligament, and inferior glenohumeral ligament [10, 11]. The abnormal magnetic resonance findings of anterior joint capsule have not been thoroughly discussed in literature in cases of adhesive capsulitis, especially when including the middle glenohumeral ligament (MGHL) and spiral glenohumeral ligament (GHL), located deep to the subscapularis muscle and tendon in the reviewed abnormalities [5].

The aim of our study is to discuss the additive value of anterior joint capsule abnormal thickness and abnormal intensity, in addition to previously described magnetic resonance findings in literature, for the establishment of diagnosis of frozen shoulder, otherwise known as adhesive capsulitis.

Methods

Ethics committee approval was obtained for this cross sectional analytic study. Informed consent was also obtained from both patients and control groups.

Adhesive capsulitis patients group

We evaluated 28 patients (17 males, 11 females; age range: 23–65 years; mean age: 45.61 years ± 11.95 years). The demographic data of the patients, namely frequency and percentage according to age and sex in the study population were shown in Table 1. The patients were referred from orthopedic department of our institution between September 2021 to February 2022. Our study involved detailed history acquisition, clinical examination for signs of adhesive capsulitis and magnetic resonance imaging of the affected shoulder joint of all our patients.

Inclusion criteria

The involvement of patients was established depending on suggestive history and on clinical signs of adhesive capsulitis. The standard of reference for clinical signs of adhesive capsulitis was defined as the presence of four or more of the following signs reported by experienced orthopedic surgeons: (1) increasing shoulder pain, particularly at night; limitations in active and passive shoulder range of motion (ROM) including (2) reduced anterior flexion and (3) abduction (less than 90 degrees anterior flexion and abduction, respectively), (4) reduced external (ER) and (5) internal (IR) rotation (less than 50% ER and IR of the contralateral shoulder, respectively).

Table 1 Comparison between cases and controls

	Cases	Controls	Univariate *P* value
Sex			
Male	17 (60.7)	14 (50)	0.420
Female	11 (39.3)	14 (50)	
Age	45.61 ± 11.95	47.25 ± 8.97	0.431
Quantitative assessment			
Anterior capsule thickness	4.02 ± 0.92	1.72 ± 0.55	**0.000**
Maximal axillary capsule thickness	4.06 ± 0.96	2.79 ± 0.58	**0.000**
Humeral capsular thickness	3 ± 1.27	2.1 ± 0.47	**0.000**
Glenoid capsular thickness	3.94 ± 1.01	2.71 ± 0.62	**0.000**
Coracohumeral ligament thickness	3.16 ± 0.72	2.33 ± 0.6	**0.000**
Degree of external rotation	119.62 ± 18.05	152.25 ± 5.98	**0.000**
Qualitative assessment			
Anterior capsular abnormal hyperintensity	21 (75)	12 (42.9)	**0.014**
Axillary capsular abnormal hyperintensity	21 (75)	6 (21.4)	**0.000**
Humeral capsular abnormal hyperintensity	18 (64.3)	12 (42.9)	0.108
Glenoid capsular abnormal hyperintensity	16 (57.1)	3 (10.7)	**0.000**
Abnormal hyperintensity at subcoracoid fat triangle	19 (67.9)	14 (50)	0.174
Obliteration of the subcoracoid fat triangle	19 (67.9)	22 (78.6)	0.365

The statistically significant values were marked by bold

Clinical signs of the patients were documented by the treating physician on a standardized questionnaire. The duration of pain should be for at least 1 month but no more than 9 months duration with a mean of 4.86 ± 2.69 months and the radiographic evaluation being normal. The severity of shoulder pain was measured according to visual analog scale (VAS) based on a questionnaire managed on the same day as the physical examination. Pain was classified as pain at rest, pain at night, pain during motion, and worst pain; each patient was taught to rate the severity of each type of pain as a VAS score.

Exclusion criteria

The exclusion criteria involved patients with bilateral shoulder pain and restricted motion, patients who were previously treated for being diagnosed with adhesive capsulitis, patients with active infection, and patients with previous ipsilateral shoulder surgery related to the diagnosis of adhesive capsulitis. Also patients with contraindication to MRI e.g.: cardiac pacemakers, claustrophobic patients and patients with bad quality of MRI images (motion artifacts, hardware insertion) were excluded.

Control group

Our control patients involved 28 cases (14 males, 14 females; age range, 27 to 61 years; mean age 47.25 years ± 8.97). Between September 2021 and February 2022, the control cases were sent for MRI examination at our hospital, which was the same time frame in which frozen shoulder patients were subjected to examination. The control group cases were either healthy volunteers or patients sent for shoulder pathologies with no clinical criteria of adhesive capsulitis. These cases were sent for MRI examination in the setting of trauma, suspected shoulder impingement or rotator cuff tear, calcific tendinitis, bursitis, and symptomatic acromioclavicular joint osteoarthritis.

MR image protocol

Both patients and control groups were subjected to a similar MR imaging protocol using a 1.5-Tesla MR imaging machine "ACHIEVA" equipment (from PHILIPS Medical Systems, Best, the Netherlands).A dedicated shoulder coil was employed. Images acquisition was done with the patients and controls in the supine position with their arms in maximum external rotation. The acquired imaging parameters were summarized in Table 2.

MR image analysis

The MR measurements were independently evaluated by two musculoskeletal radiologists, both with the same years of experience (more than 10 years). Image analysis was done using a picture archiving and communication system (PACS) workstation.

Both musculoskeletal radiologists were blinded to the clinical data and to the results of each other. We

Table 2 MRI imaging parameters for evaluation of shoulder joint

	TR/TE	Echo-train length	Section thickness	Matrix	Field of view
Sagittal oblique T1 weighted images	530/20	3	4 mm	356 × 258	160 × 160 mm
Sagittal oblique T2 weighted images	3800/80	16	3 mm	356 × 256	160 × 160 mm
Coronal obliqueT1 weighted images	530/ 20	3	3 mm	358 × 258	160 × 160 mm
Coronal oblique fat-sat T2 weighted images	4700/80	10	3 mm	356 × 255	160 × 160 mm
Sagittal oblique fat-sat PD (VISTA) sequence with spectral attenuated inversion recovery (SPAIR) images	2000/18.6	140	1.2 mm	268 × 267	160 × 160 mm
Axial fat-sat PD images	2100/30	20	3 mm	356 × 240	160 × 160 mm

established certain MRI related quantitative and qualitative measurements for the diagnosis of adhesive capsulitis, that were inspired by a study done by park et al. [5]. Re-evaluation of the parameters measured independently by the two musculoskeletal radiologists was done in order to reach an agreement. Finally, the statistical analysis was performed according to these numbers.

Assessment of the anterior capsule of shoulder joint

The anterior joint capsule was evaluated as being the part of glenohumeral joint capsule located between 2- to 5-o'clock, noted deep to the subscapularis muscle and tendon.

Our evaluation of the anterior joint capsule included the middle glenohumeral ligament and the spiral glenohumeral ligament, which showed a low signal intensity line in comparison to the overlying subscapularis muscle. In our study, the superior glenohumeral ligament and the anterior band of inferior glenohumeral ligament were not involved in the assessment of the anterior joint capsule. Spiral glenohumeral ligament was considered as a distinct anterior joint capsule ligament. Spiral glenohumeral ligament is demonstrated as being a band of low signal intensity within the examined anterior joint capsule (Figs. 1 and 2). Deep to the subscapularis muscle and tendon, the spiral glenohumeral ligament has an origin arising from the lesser tubercle of the humerus, and then it runs downward towards its insertion in the infraglenoid tubercle having a spiral course in the superficial layer of the anterior joint capsule. In the mid-aspect of its path, spiral glenohumeral ligament is seen adjacent to the middle glenohumeral ligament, and then crosses and fuses with the inferior glenohumeral ligament [5]. The thickness and signal intensity of anterior shoulder joint capsule were assessed on the thickest aspects of the previously mentioned anatomical parts. These measurements of anterior joint capsule were evaluated on both the axial fat-sat proton density and oblique sagittal three

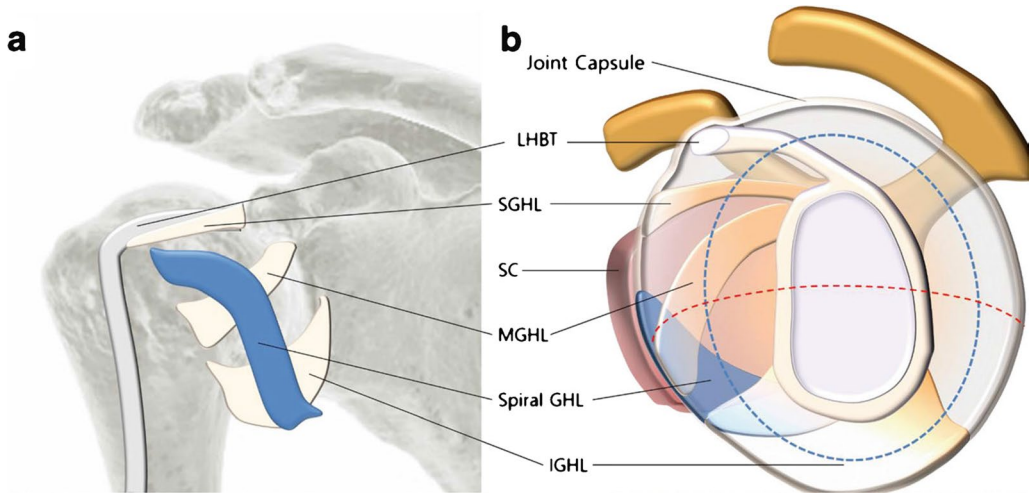

Fig. 1 Anatomy of the shoulder joint capsule structure and demonstrations of measurements of anterior joint capsule thickness on MRI. **a** Frontal illustration of outer side of glenohumeral ligament and **b** lateral view of inner aspect of shoulder joint capsule and glenohumeral ligament. The red dashed line demonstrates the axis of the axial MRI images and the blue dashed line demonstrates the axis of the sagittal MRI images. Quoted from Park et al. [5]

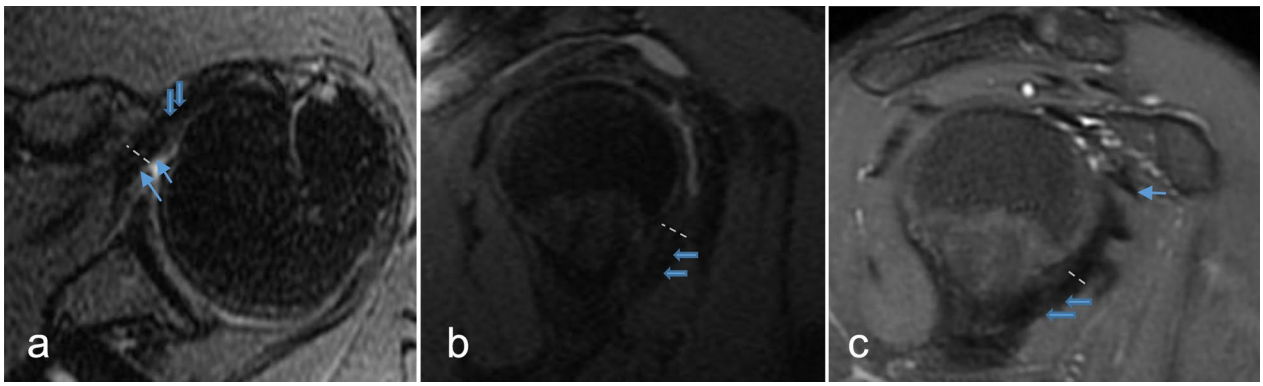

Fig. 2 Examples from a 30 year old normal male control case, illustrating the evaluation of anterior joint capsule thickness on MRI. **a** On axial fat-sat PD image, the dashed line represents the measurement of anterior capsule thickness at the level of the middle glenohumeral ligament (thin arrows), with the spiral glenohumeral ligament (thick arrows) crossing the superficial layer of the anterior joint capsule. **b** and **c** are Oblique sagittal PD VISTA SPAIR sequences illustrating the measurement of the thickest aspect of the anterior shoulder joint capsule (dashed line). The middle glenohumeral ligament (thin arrows) is seen continuous with the spiral glenohumeral ligament (thick arrows) in the inferior aspect of the joint

dimensional proton density VISTA SPAIR images (Fig. 2 a, b and c).

Quantitative measurements

The following quantitative measurements were analyzed on a four-times enlarged MRI image: anterior joint capsule thickness, thickness of the humeral and glenoid capsule in the axillary recess, maximum joint capsule thickness in axillary recess, thickness of coracohumeral ligament, and the degree of external rotation of humeral head. In the axillary aspect of joint capsule, the thickness of the humeral and the glenoid portions were evaluated at their thickest diameter on oblique coronal T2-weighted MR images. The maximum joint capsule thickness in axillary recess was then defined to be the higher number of the two measured values (humeral and glenoid capsule thickness) (Fig. 3a).

The maximum thickness of coracohumeral ligament thickness was evaluated on oblique sagittal T2 weighted images (Fig. 3b). The degree of external rotation of the humeral head on the axial magnetic resonance image was evaluated by measuring an angle noted between a line drawn from the humeral head center to the longitudinal axis of the scapular body, and another line drawn from the humeral head center to the bicipital groove of the humeral head (Fig. 3c).

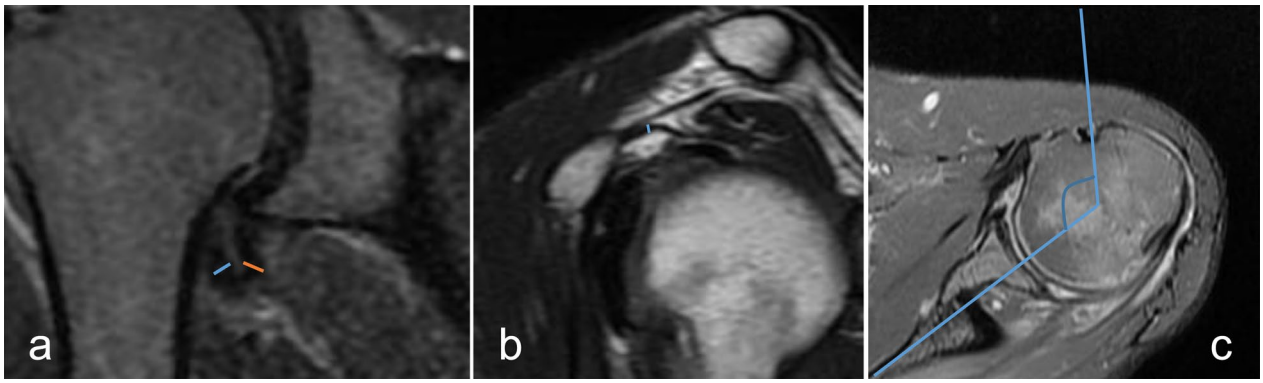

Fig. 3 Example illustrating quantitative measurements in MRI findings. **a** A 56-year-old woman with clinical diagnosis of adhesive capsulitis (shoulder pain and limitation of movement). Oblique coronal fat-sat T2-weighted image demonstrating measurement of the thickest part of axillary shoulder joint capsule in both humeral (blue line) and glenoid (red line)aspects. **b** A 59-year-old man among the control group cases. Oblique sagittal T2-weighted image demonstrating the thickness of the coracohumeral ligament (blue line). **c** A 56-year-old man among the control group cases. Axial fat-sat PD MR image noted at the level of the humeral head center illustrating the extent of shoulder external rotation. The extent of shoulder external rotation was measured in the form of an angle noted between two lines, one line extending between the center of humeral head and the longitudinal axis of scapula, and another line drawn between the center of the humeral head and the bicipital groove

Qualitative measurements

In our study, the presence or absence of multiple MR signal abnormalities was estimated. These MR signal abnormalities were as follows: abnormal hyperintense signal of anterior joint capsule, abnormal hyperintense signal of humeral and glenoid portions of axillary recess, subcoracoid fat triangle obliteration and abnormal high signal intensity. In cases where there was an abnormal hyperintense signal of the humeral or glenoid portions of joint capsule in the axillary recess, the axillary capsule abnormal hyperintense signal was considered to be present. The abnormal hyperintense signal of the joint capsule at axillary recess and at the subcoracoid fat triangle was estimated on oblique coronal fat-sat T2-weighted magnetic resonance images (Fig. 4a and b). We considered the subcoracoid fat triangle obliteration as the presence of discrete foci of homogenous low signal intensity on oblique sagittal T1-weighted images. The subcoracoid fat obliteration was evaluated subjectively as being absent or present. In both partial and complete obliteration of the fat, the obliteration of subcoracoid fat triangle was considered to be present (Fig. 4c).

Statistical analysis

The data was entered and statistically analyzed on the Statistical Package of Social Science Software program, version 25 (IBM SPSS Statistics for Windows, Version 25.0. Armonk, NY: IBM Corp.). Data was presented using mean and standard deviation for quantitative variables and frequency and percentage for qualitative ones. Comparison between groups for qualitative variables was performed using Chi-square or Fisher's exact tests while for quantitative variables the comparison was conducted using the Mann Whitney test. The validity of different measures was assessed using Receiver Operating Characteristics (ROC) analysis of MedCalc Statistical Software version 18.2.1 (MedCalc Software bvba, Ostend, Belgium; http://www.medcalc.org; 2018). Inter-rater

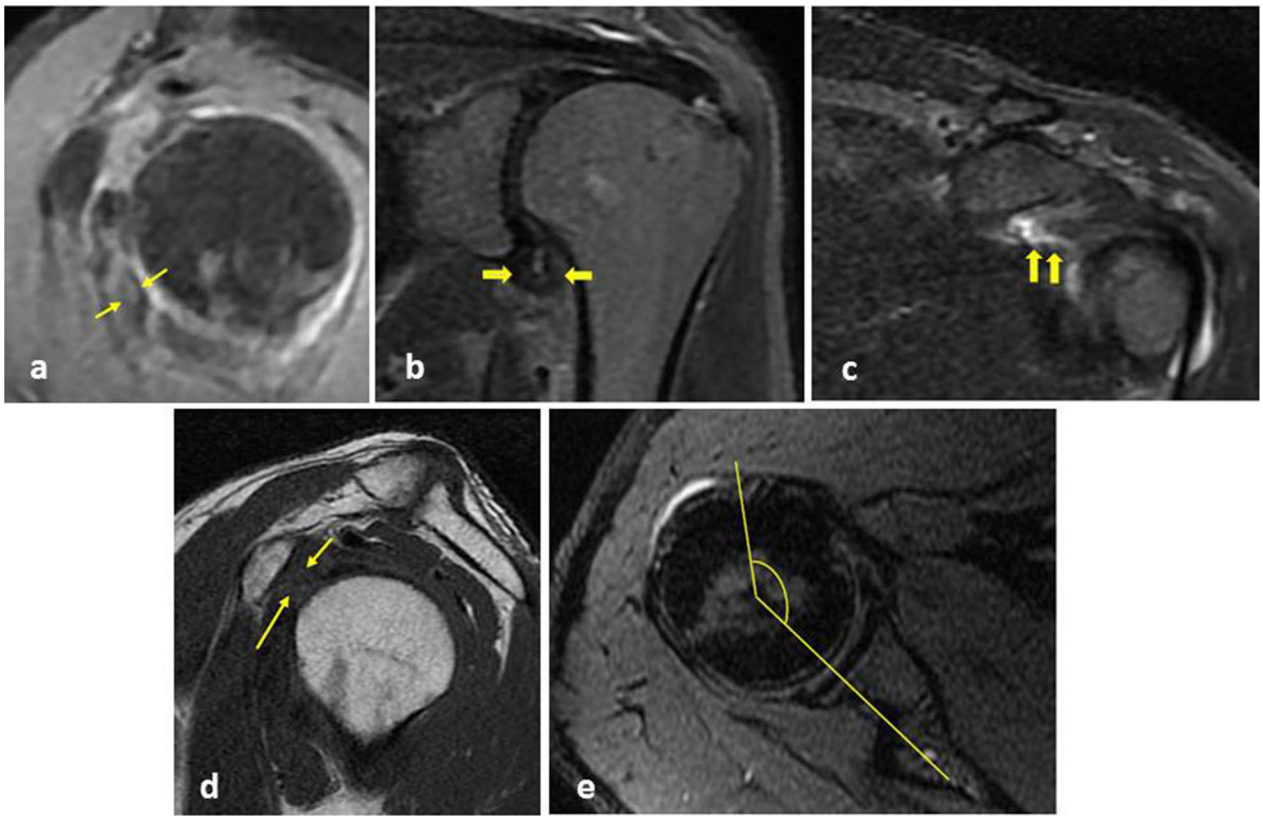

Fig. 4 Example illustrating the qualitative MR measurements. A 48-year-old woman with clinically suspected adhesive capsulitis (shoulder pain and limitation of movement). **a** Oblique 3D sagittal PD fat suppressed weighted images showing increased anterior capsule signal and thickness (yellow arrows). **b** Oblique coronal fat-sat T2-weighted image demonstrating axillary capsule thickening and abnormal increased signal intensity. There is increased thickness at the glenoid and humeral parts of the axillary joint capsule with high T2 signal intensity (thick yellow arrows). **c** Oblique coronal fat sat T2-weighted image at the level of coracoid process illustrating high signal intensity at the subcoracoid fat triangle (thick yellow arrows). **d** Oblique sagittal T1-weighted image demonstrating an obliterated subcoracoid fat triangle (thin yellow arrows). **e** Axial PD fat suppressed weighted image at the level of center of humeral head showing the angle of external rotation

concordance of different measures was assessed using Intra-class correlation coefficients (for quantitative variables) and Kappa measure of agreement (for qualitative variables). ICC or kappa values were interpreted as follows: 0, poor concordance; 0.01–0.20, slight concordance; 0.21–0.40, fair concordance; 0.41–0.60, moderate concordance; 0.61–0.80, good concordance; and 0.81–1.00, excellent concordance. P values less than or equal to 0.05 were considered statistically significant.

The standard of reference

A clinical diagnosis of adhesive capsulitis was considered the gold standard technique.

Results

Comparisons of MRI findings by univariate analysis

Table 3 shows the clinical signs (including the range of motion, visual analogue score (VAS) pain score classification) and risk factors for adhesive capsulitis of the study population. In the adhesive capsulitis group, all the 28 cases of adhesive capsulitis suffered from shoulder pain. The VAS pain score tended to increase in the order of pain at rest, pain at night, pain during motion, and worst pain.with reduced external rotation in 92.9% of cases, 85.7% with reduced abduction and anterior flexion, and 92.9% with reduced internal rotation.

Table 3 Clinical signs and risk factors for adhesive capsulitis cases

	Groups Cases (n:28)
Range of motion limitation	
External rotation	26 (92.9%)
Internal rotation	26 (92.9%)
Forward flexion	24 (85.7%)
Abduction	24 (85.7%)
Pain	
Pain at rest	
Range	0—4
Mean ± SD	2 ± 1.39
Pain at night	
Range	2—6
Mean ± SD	4 ± 1.39
Pain at motion	
Range	4—8
Mean ± SD	6 ± 1.39
Worst pain	
Range	5—9
Mean ± SD	7 ± 1.39
Risk factors	
Hypertension	8 (28.6%)
Diabetes	7 (25%)
Thyroid diseases	2 (7.1%)
Heart diseases	2 (7.1%)

The comparison between patients and controls regarding their quantitative and qualitative MRI findings is illustrated in in Table 1. There was a statistically significant difference between the adhesive capsulitis group and the control group regarding all of the examined quantitative MRI data. The mean anterior joint capsule thickness in the adhesive capsulitis group was significantly higher than that in the control group (4.02 ± 0.92 mm vs.1.72 ± 0.55 mm, p: 0.000). Abnormal hyperintense signal of anterior joint capsule also showed a statistically significant difference between adhesive capsulitis patients group and control group (21 vs. 12, p: 0.014). There was three qualitative MRI parameters that didn't show a statistically significant difference between the adhesive capsulitis and control groups, namely the abnormal hyperintense signal of humeral portion of axillary recess, subcoracoid fat triangle obliteration and subcoracoid fat triangle abnormal high signal intensity.

Diagnostic performance

According to the ROC curve study, both anterior joint capsule thickness and maximum joint capsule thickness in axillary recess showed statistically significant values in diagnosing adhesive capsulitis in patients compared to controls. The anterior joint capsule thickness revealed a greater diagnostic accuracy than the maximum joint capsule thickness in axillary recess regarding the diagnosis of adhesive capsulitis, with AUCs of 1.0 and 0.855, respectively. The studied cut-off values and results of area under the ROC curve are illustrated in Table 4 and Fig. 5, respectively. A cut-off value of anterior joint capsule thickness of 2.45 mm presented a very high sensitivity and a specificity of 100% (Fig. 6). A cut-off value of maximum joint capsule thickness in axillary recess of 3.5 mm also presented a high sensitivity of 75% and a very high specificity of 100% (Fig. 7).

Inter-rater agreement

The results of agreement between both observers are shown in Table 5. Excellent agreement was demonstrated regarding the anterior joint capsule thickness (ICC = 0.877), maximum joint capsule thickness in axillary recess (ICC = 0.874), thickness of humeral and glenoid capsule in axillary recess (ICC = 0.833 and 0.866 respectively), coracohumeral ligament thickness (ICC = 0.953), degree of external rotation of the humeral head (ICC = 0.950) and subcoracoid fat triangle abnormal high signal intensity (Kappa = 0.819).

A good interobserver agreement was demonstrated regarding abnormal hyperintense signal of anterior joint capsule (Kappa = 0.705), abnormal hyperintense signal

Table 4 Validity measures and accuracy for both qualitative & quantitative assessments

	AUC (95%CI)	*P* value	Cut-off	Sensitivity (95%CI)	Specificity (95%CI)
Quantitative assessment					
Anterior capsule thickness	1.0 (0.936–1.0)	**0.000**	> 2.45	100 (87.7–100)	100 (87.7–100)
Maximal axillary capsule thickness	0.855 (0.735–0.934)	**0.000**	> 3.5	75 (55.1–89.3)	100 (87.7–100)
Humeral capsular thickness	0.793 (0.663–0.889)	**0.000**	> 2.92	60.7 (40.6–78.5)	100 (87.7–100)
Glenoid capsular thickness	0.823 (0.698–0.912)	**0.000**	> 3.47	67.9 (47.6–84.1)	100 (87.7–100)
Coracohumeral ligament thickness	0.817 (0.691–0.908)	**0.000**	> 2.54	71.4 (51.3 – 86.8)	67.9 (47.6—84.1)
Degree of external rotation	0.949 (0.855–0.990)	0.000	≤ 136.2	85.7 (67.3—96.0)	100 (87.7–100)
Qualitative assessment					
Anterior capsular abnormal hyperintensity	0.661 (0.522—0.782)	**0.011**		75 (55.1—89.3)	57.1 (37.2—75.5)
Axillary capsular abnormal hyperintensity	0.768 (0.636—0.870)	**0.000**		75 (55.1—89.3)	78.6 (59.1—91.7)
Humeral capsular abnormal hyperintensity	0.607 (0.468—0.735)	0.106		64.3 (44.1—81.4)	57.1 (37.2—75.5)
Glenoid capsular abnormal hyperintensity	0.732 (0.597—0.842)	**0.000**		57.1 (37.2—75.5)	89.3 (71.8—97.7)
Abnormal hyperintensity at subcoracoid fat triangle	0.589 (0.450—0.719)	0.175		67.9 (47.7—84.1)	50 (30.7—69.4)
Obliteration of the subcoracoid fat triangle	0.554 (0.415—0.687)	0.371		32.1 (15.9—52.4)	78.6 (59.1—91.7)

The statistically significant values were marked by bold

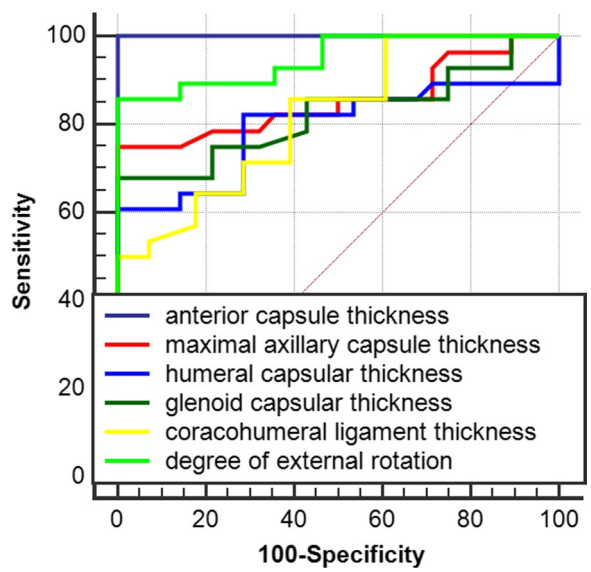

Fig. 5 ROC curve analysis for quantitative measures

of joint capsule in axillary recess (Kappa = 0.749), abnormal hyperintense single of humeral and glenoid portions of joint capsule in the axillary recess (Kappa = 0.716 and 0.798 respectively), and subcoracoid fat triangle obliteration (Kappa = 0.727).

Discussion

Our study showed the importance of the increased thickness of anterior shoulder joint capsule and significance of alteration of its signal intensity for the evaluation of adhesive capsulitis (AUC: 1.0 and 0.661, respectively) with excellent interobserver agreement for anterior capsular thickening (ICC = 0.877) and good interoberver reliability for anterior capsular hyperintensity (Kappa = 0.705). The thickness of anterior joint capsule with a cut-off value of 2.45 mm showed a very high diagnostic presentation (sensitivity, and specificity of 100%).

Previously published studies [5, 12, 13] showed that some MRI findings are impressive of a diagnosis of adhesive capsulitis. These findings include a substantially thickened coracohumeral ligament; thickening of the joint capsule in the rotator interval, thickening and altered signal of the joint capsule in axillary recess and obliteration of the subcoracoid fat triangle whether partial or complete. According to Erber et al. [14], none of these individual MRI signs was proved to be perfectly sensitive or specific.

To the best of our knowledge, a single previous study done by Park et al. [5], has focused on the role of MRI in detection of abnormal signal and thickness of the anterior joint capsule in diagnosis of patients with adhesive capsulitis. We did not only study the importance of anterior capsular abnormality in diagnosis of adhesive capsulitis, we also highlighted its importance among other parameters previously described in literature for diagnosis of frozen shoulder syndrome, as we proved that increased anterior capsule thickness has the highest AUC amongst these parameters. Anterior capsule increased signal intensity showed a high sensitivity in diagnosis as well.

In the previously described literature, the three ligaments involved in the formation of anterior joint capsule have been named as the superior, middle and inferior glenohumeral ligaments. The inferior glenohumeral ligament is separated into three parts: a band noted

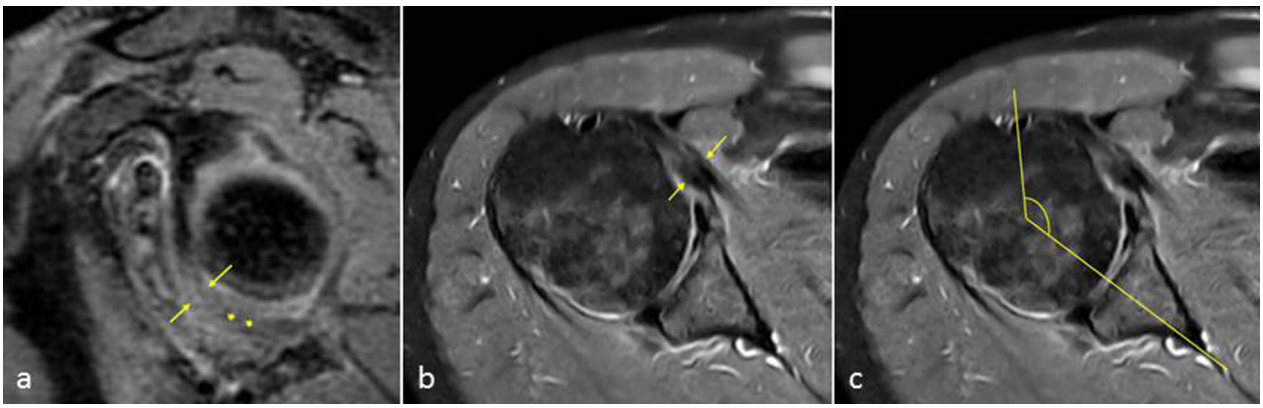

Fig. 6 A 47-year-old man with a clinical diagnosis of adhesive capsulitis (shoulder pain and limitation of movement). **a** Oblique sagittal PD VISTA SPAIR image illustrating a thickened (4.2 mm) anterior shoulder joint capsule (thin yellow arrows). A thickened and an increased signal intensity of the axillary shoulder joint capsule are also demonstrated (asterisks). **b** Axial fat-sat PD illustration of marked thickening and increased signal intensity of the anterior shoulder joint capsule is also noted (thin yellow arrows). **c** Same axial PD fat suppressed images showing angle of external rotation

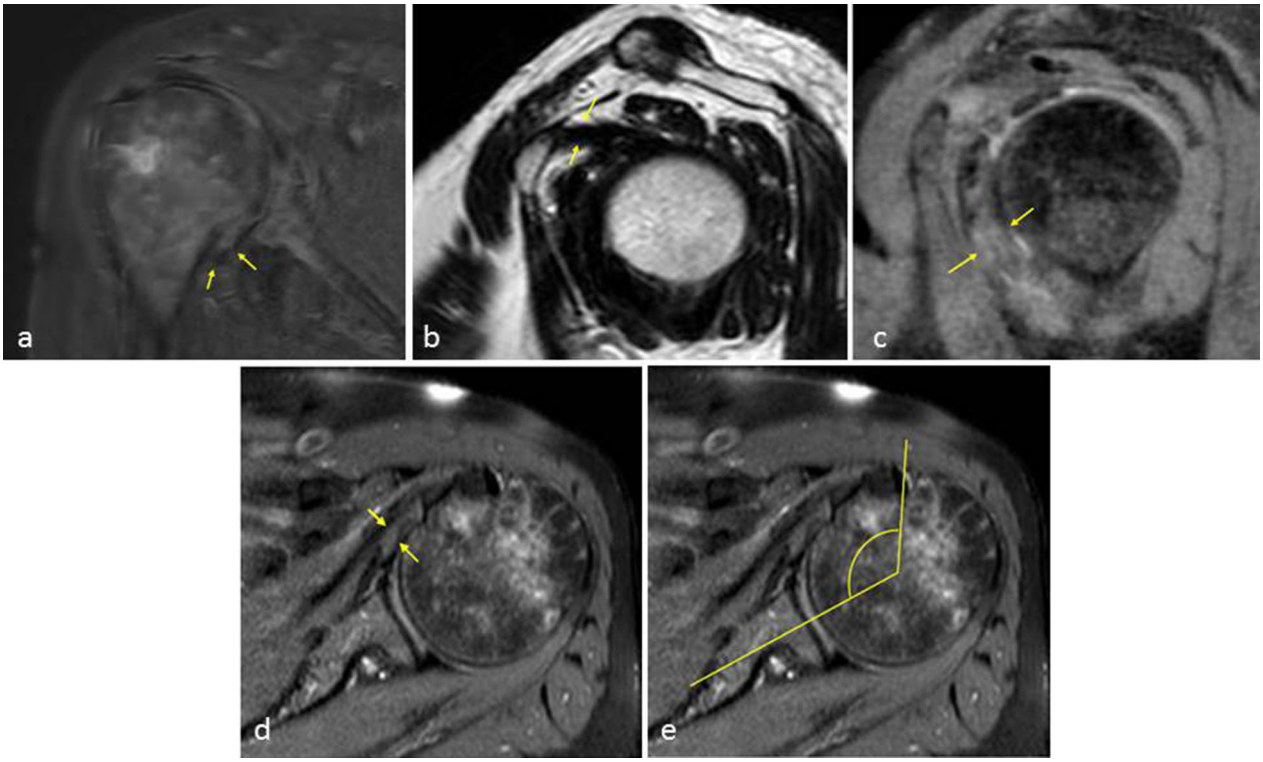

Fig. 7 A 65-year-old female patient with clinically suspected adhesive capsulitis (shoulder pain and limitation of movement). **a** Oblique coronal fat-sat T2-weighted image demonstrating no sizable increased thickness of the axillary recess (thin yellow arrows). Also there is no gross axillary capsule altered signal intensity. **b** Oblique sagittal T2-weighted image illustrating a thickened coracohumeral ligament. **c** Oblique sagittal PD VISTA SPAIR image illustrating thickened and increased signal intensity of the anterior joint capsule (thin yellow arrows). **d** Axial fat suppressed PD image demonstrating increased thickness (6.95 mm) and increased signal intensity of the anterior shoulder joint capsule (thin yellow arrows). **e** Same Axial PD fat suppressed weighted image at the level of center of humeral head showing the angle of external rotation

Table 5 Reliability measures for both qualitative & quantitative assessments (inter-rater agreement)

	ICC	95% CI	Inter-observer agreement%	K	95% CI	Degree of agreement
Quantitative assessment						
Anterior capsule thickness	0.877	(0.783—0.93)				Excellent
Maximal axillary capsule thickness	0.874	(0.786—0.926)				Excellent
Humeral capsular thickness	0.833	(0.714—0.902)				Excellent
Glenoid capsular thickness	0.866	(0.769—0.922)				Excellent
Coracohumeral ligament thickness	0.953	(0.921—0.973)				Excellent
Degree of external rotation	0.950	(0.915—0.971)				Excellent
Qualitative assessment						
Anterior capsular abnormal hyperintensity			85.7%	0.705	(0.516—0.894)	Good
Axillary capsular abnormal hyperintensity			87.5%	0.749	(0.576—0.923)	Good
Humeral capsular abnormal hyperintensity			85.7%	0.716	(0.535—0.896)	Good
Glenoid capsular abnormal hyperintensity			91.1%	0.798	(0.63—0.966)	Good
Abnormal hyperintensity at subcoracoid fat triangle			91.1%	0.819	(0.669—0.97)	Excellent
Obliteration of the subcoracoid fat triangle			91.1%	0.727	(0.522—0.932)	Good

anteriorly, a band noted posteriorly and an intervening axillary pouch. In addition to the superior, middle and inferior glenohumeral ligaments, a group of fibers called the "spiral glenohumeral ligament" is involved in the formation of superficial layer of the anterior shoulder joint capsule. It was given this name considering its macroscopic shape throughout the external rotation and abduction of the shoulder joint.According to a study done by Merila et al. [15], the spiral glenohumeral ligament was visualized as a band of low signal intensity on MR images through its course in the superficial layer of the anterior joint capsule (Figs. 1 and 2). Despite this ligament's firm connection with the middle and inferior glenohumeral ligaments, its importance in the shoulder joint biomechanics and association with different pathologic disorders has not been fully explored.

The three ligaments involved anatomically in the formation of anterior shoulder joint capsule, together with spiral glenohumeral ligament and inner capsular structure of subscapularis muscle were identified in our study. We measured the anterior joint capsule at its thickest aspect and we excluded the superior glenohumeral ligament and anterior band of inferior glenohumeral ligament from our study.

In our study, through ROC curve analysis, we reported cut off numbers of 2.45 mm and 3.5 mm for anterior capsular thickness and maximal axillary capsular thickness, with an AUC of 1 and 0.857 respectively. In accordance to our study, Park et al. [5] found that both, thickness of anterior joint capsule and maximum thickness of axillary capsule showed statistically significant values in diagnosing adhesive capsulitis in patients compared to controls with cut off numbers of 3.5 mm and 4.5 mm and an AUC of 0.897 and 0.863 respectively. On the other hand, regarding the qualitative parameters, Park et al. [5] reported a sensitivity and specificity of 82.76% and 90% respectively for anterior capsular abnormal hyperintensity in diagnosing adhesive capsulitis. Our study showed a sensitivity and specificity of 75% and 57.1% respectively for the same qualitative measurement (anterior capsular abnormal hyperintensity). This difference may be attributed to demographic variations between the studied sample populations.

Formerly, in literature, some surgical and pathologic studies have been involved in the evaluation of the anterior joint capsule structures in patients with adhesive capsulitis. A previous study [16] revealed that the release of the anteroinferior joint capsule, involving the anterior band of the inferior glenohumeral ligament, increased the range of elevation, and that posterior extended capsular release may not be important in the arthroscopic surgical treatment of shoulder stiffness. In another study [17] that concluded that ultrasound-guided anterior approach for hydrodilatation of rotator interval in patients with adhesive capsulitis, associated with proper exercise, is more efficient than the conventional posterior approach, they stated that the predominant pathological finding in adhesive capsulitis is observed around the rotator interval and the anterior capsule.In previous arthroscopic studies involving patients with adhesive capsulitis [18, 19], inflammation of joint capsule and synovium was mostly noted on the anterior side of the joint, involving the rotator interval and middle glenohumeral ligament prior to manipulation. After the manipulation, hemorrhage was predominantly noted in the anterior-inferior capsule and

inferior glenohuemral ligament. In a pathological study done by Uhthoff et al. [20], they hypothesized that the cytocontractile protein vimentin is present only in the anterior shoulder joint capsular structures, consequently their surgical release has frequently revealed a reestablishment of glenohumeral movement.

Concerning our study, the maximum joint capsule thickness and abnormal hyperintensity of the joint capsule in axillary recess revealed significantly different values between the adhesive capsulitis group and control group, showing both a significantly higher value in the cases group.Previously done, most recent MRI studies [14, 21] found similar results.

Our study also showed that coracohumeral ligament is significantly thicker in adhesive capsulitis patients compared to control group. This finding was also comparable to previous studies [4, 5, 22, 23].

In contrary to park et al. [5] and Erber et al. [14], we did not find a significant statistical difference between cases and controls regarding the obliteration of subcoracoid fat triangle. Other studies [24, 25] stated that only the complete, not the partial obliteration of subcoracoid fat triangle is specific to the diagnosis of adhesive capsulitis. May be this difference in results is attributed to the fact that, we combined both partial and complete obliteration of subcoracoid fat triangle as a single qualitative sign suggestive of adhesive capsulitis. We didn't consider them as two separate qualitative signs.

Our study had multiple limitations. First, we could not perform multivariate logistic regression analysis because the multicollinearity between different variants was very high. Also our study included a small sample size, considering the large number of adhesive capsulitis patients referred from the orthopedic department. Second, our study was a cross sectional analytic one, thus, we did not establish whether the anterior capsule abnormal thickness and intensity are characteristic signs related to adhesive capsulitis. Third, we did not depend on a true "gold standard".There was no arthroscopic or histopathological confirmation of our results. Fourth, we did not correlate between clinical stages and the MRI signs of adhesive capsulitis because of the small study population. Therefore, there must have been bias toward subgroup analysis. Fifth, we did not perform our MRI examinations using a 3 T MR machine, instead we used the available 1.5 T MRI machine. Sixth, we did not use contrast enhanced images for evaluation of adhesive capsulitis.

Conclusions

In conclusion, increased anterior capsular thickness and anterior capsule abnormal signal intensity, can be included as confident parameters for evaluation and diagnosis of adhesive capsulitis of the shoulder joint. Added to the formerly known abnormal MRI signs concerning the axillary recess, the subcoracoid fat triangle and the coracohumeral ligament, the assessment of the anterior shoulder joint capsule can be of value for establishing a diagnosis of adhesive capsulitis. Future studies involving a larger number of patient, in addition to correlation between anterior capsule abnormality in adhesive capsulitis patients and clinical features is advised.

Abbreviations

MRI: Magnetic resonance imaging; SPAIR: Spectral attenuated inversion recovery; SPSS: Statistical package of social science; ROC: Receiver operating characteristic; AUC: Area under the curve; ICC: Intra-class correlation coefficients; Lig: Ligamentum; VAS: Visual analogue scale; ER: External rotation; IR: Internal rotation.

Acknowledgements

The authors gratefully acknowledge the valuable contributions of Dr. Mohamed Abdelfattah Abdelaziz Afifi , resident of radiology; to facilitate performing this work. The authors are really appreciating the role of the Kasr ElAini institute and hospital for providing the study with the required type of patients and the help of reaching optimum diagnosis for the proper management service.

Author contributions

HK: Conceived the study, designed it, was the primary radiologist who interpreted the images blindly from the second radiologist, and drafted the manuscript. ME: Participated in the design of the study, revised and adjusted the manuscript. MR: Was the orthopedic surgeon who made the clinical exams and revised the orthopedic part of the manuscript. All authors have read and approved the final version of the manuscript.

Funding

No funding was obtained for this study.

Availability of data and materials

The datasets used and analyzed during the current study are available from the corresponding author on reasonable request.

Declarations

Ethics approval and consent to participate

The study had been approved by the Research Ethics Committee of the Faculty of Medicine at Cairo University in Egypt on 201672016; in compliance with Helsinki Declaration (DoH-oct20081). All patients included in this study gave written informed consent to participate in this research. If the patient was less than 16 years old or unconscious at the time of the study, written informed consent for their participation was given by their parent or legal guardian.

Consent for publication

All patients included in this research gave written informed consent to publish the data contained within this study. If the patient was less than 16 years old, deceased, or unconscious when consent for publication was requested, written informed consent for the publication of this data was given by their parent or legal guardian.

Competing interests

The authors declare that they have no competing interests.

Author details

[1]Department of Diagnostic and Interventional Radiology, Faculty of Medicine, Cairo University Kasr Alainy, 8 Ahmed eElshediak Street, Ard Elgolf, Heliopolis, Cairo, Egypt. [2]Department of Orthopedics, Faculty of Medicine, Cairo University Kasr Alainy, Cairo, Egypt.

Received: 13 July 2022 Accepted: 30 September 2022
Published online: 04 November 2022

References

1. Guha K (2019) Physiotherapy of adhesive capsulitis: a review. Int J Phys Educ Sports Health 6(2):12–16
2. Saraçgil Coşar SN, Ozen S, Niyazi Kurtcebe A, Coşkun M, Ümit Yemişci O (2021) Prognostic value of magnetic resonance imaging in the evaluation of physical therapy outcomes in patients with adhesive capsulitis. Turk J Phys Med Rehabil 67(2):146–154. https://doi.org/10.5606/tftrd.2021.5139. PMID:34396065;PMCID:PMC8343157
3. Ahn KS, Kang CH, Oh YW, Jeong WK (2012) Correlation between magnetic resonance imaging and clinical impairment in patients with adhesive capsulitis. Skeletal Radiol 41(10):1301–1308
4. Li JQ, Tang KL, Wang J, Li QY, Xu HT, Yang HF, Tan LW, Liu KJ, Zhang SX (2011) MRI findings for frozen shoulder evaluation: is the thickness of the coracohumeral ligament a valuable diagnostic tool? PLoS ONE 6(12):e28704
5. Park J, Choi YH, Chai JW, Cha SW, Lim JH, Jo CH, Kim DH (2019) Anterior capsular abnormality: another important MRI finding for the diagnosis of adhesive capsulitis of the shoulder. Skeletal Radiol 48(4):543–552
6. Nishimoto H, Fukuta S, Fukui N, Sairyo K, Yamaguchi T (2022) Characteristics of gene expression in frozen shoulder. BMC Musculoskelet Disord 23(1):811
7. Arirachakaran A, Chaijenkij K, Maljadi JA, Kongtharvonskul J (2020) Comparison of surgical outcomes between rotator cuff repair with and without rotator interval capsular release for rotator cuff tears to prevent and improve postoperative stiffness: a meta-analysis. Eur J Orthop Surg Traumatol 30(7):1263–1275
8. Pogorzelski J, Imhoff AB, Degenhardt H, Siebenlist S (2019) Primäre (idiopathische) Schultersteife: definition, Krankheitsverlauf, Epidemiologie und Ätiologie [Primary (idiopathic) shoulder stiffness: definition, disease progression, epidemiology and etiology]. Unfallchirurg. 122(12):917–924
9. Kim YS, Lee YG, Park HS, Cho RK, Lee HJ (2021) Comparison of gene expression of inflammation- and fibrosis-related factors between the anterior and posterior capsule in patients with rotator cuff tear and shoulder stiffness. Orthop J Sports Med 9(10):23259671211032544
10. Ohya N, Yamada T (2022) Evaluation of the tissue thickness of the supraspinatus and biceps long head tendons using ultrasound among elderly patients with unilateral adhesive capsulitis in the freezing phase. J Phys Ther Sci 34(6):426–432
11. Barnes RH, Paterno AV, Lin FC, Zhang J, Berkoff D, Creighton RA (2022) Glenohumeral hydrodistension for postoperative stiffness after arthroscopic primary rotator cuff repair. Orthop J Sports Med 10(6):23259671221104504
12. Tamai K, Akutsu M, Yano Y (2014) Primary frozen shoulder: brief review of pathology and imaging abnormalities. J Orthop Sci 19(1):1–5
13. Ryan V, Brown H, Minns Lowe CJ, Lewis JS (2016) The pathophysiology associated with primary (idiopathic) frozen shoulder: a systematic review. BMC Musculoskelet Disord 17(1):340
14. Erber B, Hesse N, Glaser C, Baur-Melnyk A, Goller S, Ricke J, Heuck A (2022) MR imaging detection of adhesive capsulitis of the shoulder: impact of intravenous contrast administration and reader's experience on diagnostic performance. Skeletal Radiol 51(9):1807–1815
15. Merila M, Leibecke T, Gehl HB, Busch LC, Russlies M, Eller A, Haviko T, Kolts I (2004) The anterior glenohumeral joint capsule: macroscopic and MRI anatomy of the fasciculus obliquus or so-called ligamentum glenohumerale spirale. Eur Radiol 14(8):1421–1426
16. Kim YS, Lee HJ, Park IJ (2014) Clinical outcomes do not support arthroscopic posterior capsular release in addition to anterior release for shoulder stiffness: a randomized controlled study. Am J Sports Med 42(5):1143–1149
17. Elnady B, Rageh EM, Hussein MS, Abu-Zaid MH, Desouky DE, Ekhouly T, Rasker JJ (2020) In shoulder adhesive capsulitis, ultrasound-guided anterior hydrodilatation in rotator interval is more effective than posterior approach: a randomized controlled study. Clin Rheumatol 39(12):3805–3814
18. Ohya N, Yamada T (2022) Evaluation of the tissue thickness of the supraspinatus and biceps long head tendons using ultrasound among elderly patients with unilateral adhesive capsulitis in the freezing phase. J Phys Ther Sci 34(6):426–432
19. Lee GY, Ha YC, Kim S, Kim JY (2019) Computed tomography arthrography findings of idiopathic adhesive capsulitis of the hip: an analog of adhesive capsulitis of the shoulder. Korean J Radiol 20(3):479–486
20. Uhthoff HK, Boileau P (2007) Primary frozen shoulder: global capsular stiffness versus localized contracture. Clin Orthop Relat Res 456:79–84
21. Gillet R, Zhu F, Padoin P, Rauch A, Hossu G, Teixeira P, Blum A (2021) MR imaging biomarkers for clinical impairment and disease progression in patients with shoulder adhesive capsulitis: a prospective study. J Clin Med 10(17):3882
22. Kerimoglu U, Aydingoz U, Atay OA, Ergen FB, Kirkpantur A, Arici M (2007) Magnetic resonance imaging of the rotator interval in patients on long-term hemodialysis: correlation with the range of shoulder motions. J Comput Assist Tomogr 31(6):970–975
23. Chellathurai A, Subbiah K, Elangovan A, Kannappan S (2019) Adhesive capsulitis: MRI correlation with clinical stages and proposal of MRI staging. Indian J Radiol Imaging 29(1):19–24
24. Suh CH, Yun SJ, Jin W, Lee SH, Park SY, Park JS, Ryu KN (2019) Systematic review and meta-analysis of magnetic resonance imaging features for diagnosis of adhesive capsulitis of the shoulder. Eur Radiol 29(2):566–577
25. Mohammed MH, Fahmi FM, Shehata KA, Elia RZ (2022) Shoulder adhesive capsulitis: can clinical data correlate with fat-suppressed T2 weighted MRI findings? Egypt J Radiol Nucl Med 53(1):76

Publisher's Note