Boles *et al. Egypt J Radiol Nucl Med* (2023) 54:54
https://doi.org/10.1186/s43055-023-00989-z

Egyptian Journal of Radiology and Nuclear Medicine

RESEARCH

Open Access

Introducing 3D modelling of MRI in the preoperative mapping of perianal fistula: How it could help the surgeons?

Mary Salah Roman Boles[1], Rania Farouk El-Sayed[1], Haney Ahmed Sami Shawali[1], Ahmed Farag[2], Fawzy Salah Fawzy[3] and Maryse Youssef Awadallah[1*]

Abstract

Background Surgeons find treating perianal fistula difficult because insufficient drainage and failure to eradicate perianal sepsis could increase the risk of recurrence and postoperative complications. For better planning of the most suitable surgical technique, surgeons must consider the risk factors of recurrence with an accurate pre-operative assessment of perianal fistulae.The most common imaging method for grading primary perianal fistulas, identifying their complications, and locating occult extensions is magnetic resonance imaging (MRI). However, surgeons may find it challenging to read the lengthy reports of complex tracts, particularly for complicated patients. The creation of three-dimensional (3D) models has gained traction recently as a genuinely useful diagnostic tool for pre-operative planning. The authors evaluated the value of these surgical models. Inspecting the 3D models in addition to the routine two-dimensional study caused four out of five skilled colorectal surgeons to re-evaluate how far the fistulae extended. This made promise that 3D models would be helpful, simple to understand, and quick to interpret for colorectal surgeons. The purpose of the study is to assess the value of adding 3D modelling of MRI to standard two-dimensional MRI protocol for more accurate delineation of perianal fistula and its complications aiming at better surgical outcomes.

Results Regarding 3D models, the highest degree of accuracy was in detecting supra-levator extension (100%) by both the third radiologist and the surgeon. There was a statistically high diagnostic inter-observer agreement between both, with a p-value < 0.0001. The highest inter-observer agreement was in the supra-levator extension (50/50, 100%), and the lowest agreement was in the side branches detection (44/50, 88%).

Conclusions Pre-operative 3D MRI modelling provided the surgeon with a pre- and intra-operative road map that improved the surgeon's orientation and ability to see complex perianal fistulas and their consequences, especially those with supra levator extension, thus helping the surgeon achieve better surgical results and decrease the preoperative risk factors of recurrence. Surgeons should utilise it in complex and recurrent cases reducing preoperative risk factors and improving outcomes. Although this technique is expensive, its cost–benefit ratio is low relative to recurrent hospitalisation and complications.

Keywords Colorectal surgery, Rectal fistula, 3D imagings, Computer generated

*Correspondence:
Maryse Youssef Awadallah
maryse.youssef@kasralainy.edu.eg; Maryseawadallah@gmail.com
[1]Department of Diagnostic and Interventional Radiology, Kasr Al Ainy Hospital, Faculty of Medicine, Cairo University, 71 Kasr Al Ainy Street, Cairo 11562, Egypt.
[2]Department of General Surgery, Kasr Al Ainy Hospital, Faculty of Medicine, Cairo University, 71 Kasr Al Ainy Street, Cairo 11562, Egypt.
[3]Department of General Surgery, Faculty of Medicine, Ain Shams University, Nour Mosque, 38 Abbasia, Al Waili, Cairo 11562, Egypt.

Background

Perianal fistula is a common condition of abnormal epithelialised communication between the perianal skin and the anal canal, with an incidence rate of 0.7–37% and a recurrence rate of 7–50% [1, 2].

There are multiple pre-operative, intra-operative, and post-operative risk factors for the recurrence of perianal fistulae, as a result; treating perianal fistula is considered challenging for surgeons because incomplete drainage and eradication of the perianal sepsis could raise the recurrence rate and postoperative complications; therefore, surgeons must keep the risk factors of recurrence in mind, with an accurate pre-operative assessment of perianal fistulae for better planning of the most appropriate surgical procedure [1, 3].

MRI is considered the standard imaging modality for grading primary perianal fistula, detecting its complications and occult extensions. However, the lengthy reports of complicated tracts may be difficult for surgeons to interpret, especially for complex cases [4, 5].

In recent years, the conception of 3D models has been gaining space as a promising aiding diagnostic modality in pre-operative planning [5]. Smith et al. [4] tested the usefulness of 3D models of perianal fistulae for surgeons. When inspecting the 3D models, four out of five experienced colorectal surgeons altered their perception of the fistulae's extension. The study concluded that all surgeons participating in the study found 3D models useful, easy, and fast to interpret.

Thus, our study aimed to test the value of 3D modelling of the perianal fistula in addition to the standard 2D MRI protocol and to investigate its impact in enhancing surgeons' insight regarding its complexity and related complications, reaching better surgical outcomes and hence reducing the risk factors of recurrence and the cost of repeated hospitalisation.

Methods

This prospective study was ethically approved by the "Scientific Research and Ethics Committee" (SREC) of the Radiology Department of our University, followed by the institutional review board (IRB) of the faculty of medicine of our University. Number: I-191015.

Study design

This is an observational, cross-sectional analytical study that compares the accuracy of 3D modelling interpretation of an expert radiologist versus that of an expert colorectal surgeon, then calculating their interobserver agreement. The results of the 2D MRI were considered the reference standard in this study.

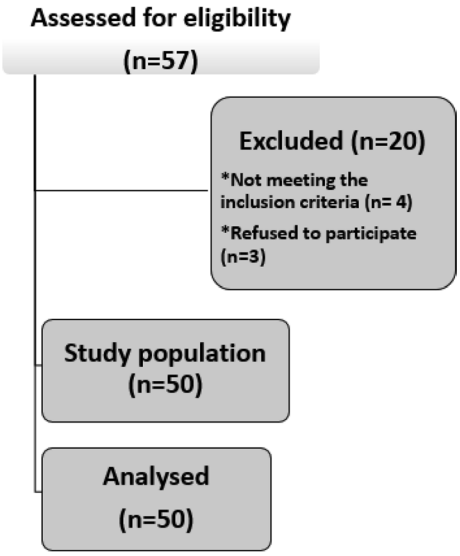

Fig. 1 Flowchart of the study population including the number of excluded patients

Study population

The study population consisted of fifty adult patients with symptoms of perianal inflammatory disorders who were presented between May 2019 and April 2020 and were referred to the Radiology department, of our teaching university hospital. Informed written consent was taken from all the subjects before the study. The patient population ($n=50$) consisted of; 44 (88%) males and 6 (12%) females with a mean age of 39 years old (range 20–68 years).

The study included adult patients of both sexes with clinical suspicion of perianal inflammatory conditions, whether of suspected recent or recurrent perianal fistulas, who were referred to the radiology department of our teaching hospitals during the routine work of the colorectal surgical clinic. Where an experienced colorectal surgeon (A.F., with 32 years of experience in clinical evaluation and management of perianal fistula) has examined the patients by direct rectal examination (DRE), recorded their clinical findings, and the provisional clinical diagnosis in a referral sheet that was sent to the radiology department. We excluded children and patients who were contraindicated for MRI, such as those with cardiac pacemakers or claustrophobia. (Fig. 1).

Standard 2D MRI acquisition

All patients underwent MR examinations using a 1.5-T MRI scanner (ACHIEVA, PHILIPS Healthcare) using a phased array body coil. No special preparations were needed. Our institution's standard MRI protocol of the perianal fistula is shown in (Table 1). Patients were lying

Table 1 Standard 2D MRI protocol of perianal fistula in our institution

	TR (ms)	TE (ms)	FOV (ms)	Matrix	SL (mm)	NEX
T2W TSE sagittal	3000	90	290	320 × 320	4	3
T2W TSE axial	7228	100	260	384 × 384	3	3
FS T2W TSE axial	4899	80	260	288 × 288	3	2
T2W TSE coronal	3259	100	320	224 × 224	3	3
FS T2W TSE coronal	4355	80	320	288 × 288	3	2
T1W TSE axial	576	20	260	384 × 384	3	3

TSE Turbo spin echo, *FS* Fat-saturated, *TR* Repetition time, *TE* Echo time, *FOV* Field of view, *NEX* Number of excitations

in the supine position. Initial three planes were obtained. On the sagittal images, the axial plane was planned perpendicular to the anal canal, while the coronal images were planned parallel to the anal canal. A radiologist (M.S., with five years of experience in imaging of perianal fistula) attended each MRI examination to ensure correct angulation and acquisition of the planes. No special preparations were needed. No IV contrast was given. No rectal jelly was injected. As recently, non-contrast MRI was proven to be sufficient, as stated by Gupa et al. [6].

Magnetic resonance images were reported by a radiologist (R.F.E.S., with 20 years of experience in 2D imaging of perianal fistula). The radiologist (R.F.E.S) was aware of each patient's clinical history and provisional diagnosis. The radiologist (R.F.E.S) commented on the internal opening site, presence of side branches, abscess collections, horseshoe collections, and supra-levator extensions. Standard 2D MRI protocol was the standard reference for creating the 3D models.

The internal opening was recognised by the enteric end of the primary tract in the anal canal, and its site was described according to the anal clock. The perianal abscess was defined as a focal widening of the tract more than 10 mm in diameter. The horseshoe collection was recognised by its horizontal orientation across the midline, either along the inter-sphincteric plane or outside. Secondary side branches were defined as tracts that emerge from the primary tract. Supra-levator extension was defined as a proximal extension of the primary tract or its side branches across the levator ani muscle [7].

Creation of the 3D models

The radiologist (M.S.) created the 3D models of the perianal fistula and related pelvic structures using the standard 2D MRI that were exported to 3D-DOCTOR™ able software, version 5.0.20140721. The 3D model was performed by doing a 3D reconstruction of the pelvic structures and the fistulous tract; first by doing manual segmentation;—a post-processing imaging technique that has been used to trace selected structures in the consecutive oblique axial T2-weighted images (Fig. 2). Second, by applying surface rendering to create the 3D model which demonstrated each anatomical structure in a different colour. The fistula was traced in red colour, the internal anal sphincter in blue, the external anal sphincter in yellow, the puborectalis muscle in light green, and the rest of the levator plate in deep green. For better orientation, an anal clock was established with the 3D model. The software enabled the removal or addition of any anatomical structure for better visualisation of the perianal tract in the 3D models. Each 3D model was saved in the format of a movie. At the beginning of our work, the reconstruction of each 3D model was a lengthy procedure. Each case of 3D model reconstruction has taken time of nearly 2 h. By developing experience of about two months, time was cut down to 20–40 min depending on the complexity of the perianal fistula.

Analysis of the 3D models

A radiologist (M.Y.A, with 15 years of experience in 2D imaging of perianal fistula) and a colorectal surgeon (F.S.F, with eight years of experience in assessment and management of perianal fistula) were asked to interpret the 3D models. Both were trained by the radiologist (M.S.) to recognise the coloured anatomical structures in the 3D models. The radiologist (M.Y.A.) and the surgeon (F.S.F) were blinded to 2D MRI findings and the reports written by the radiologist (R.F.E.S.). Both of them have individually interpreted the 3D models. Each 3D model was assessed according to the site of the internal opening of the tract, the presence of side branches, abscesses, horseshoe collections, and supra-levator extensions. The reported data of the radiologist (M.Y.A.) and the surgeon (F.S.F) were compared to the 2D MRI findings to detect the sensitivity, specificity, + ve predictive value, -ve predictive value, and overall accuracy. Thereafter, the percentage of inter-observer diagnostic agreement between the radiologist (M.Y.A.) and the surgeon (F.S.F) was calculated.

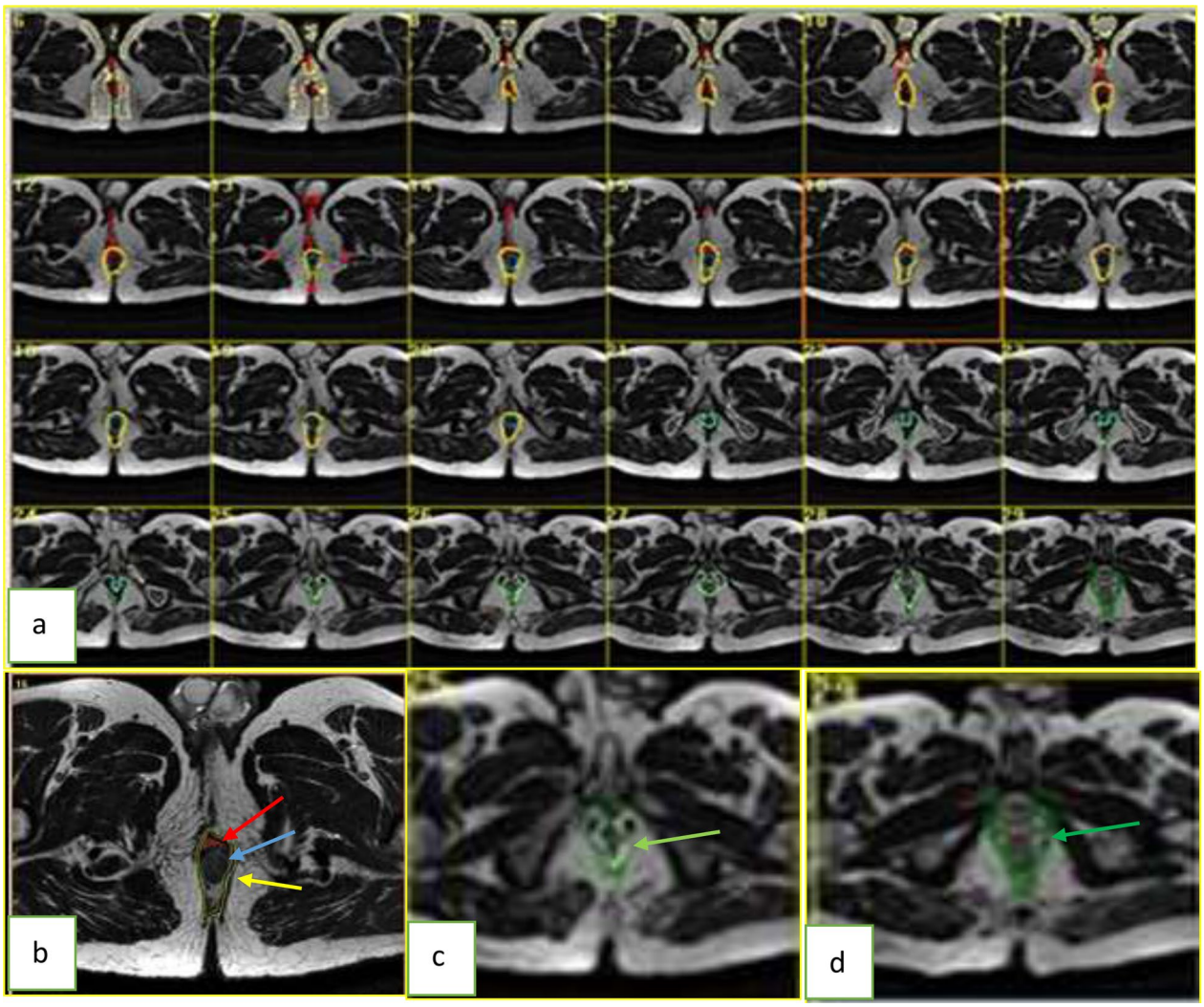

Fig. 2 Consecutive oblique axial T2-weighted turbo spin-echo MR images (TR/TE, 7228/100) of a 40-year-old male patient presenting with discharging perianal fistula. The manual segmentation process was done by tracing different anatomical structures in each image in different colours (**a**). The fistula was traced in red colour (red arrow), the internal anal sphincter in blue (blue arrow), the external anal sphincter in yellow (yellow arrow) (**b**), the puborectalis muscle in light green (**c**) and the rest of the levator plate in deep green (**d**)

Statistical analysis

Data were statistically described in terms of frequencies and percentages. Accuracy was represented using the terms sensitivity, specificity, + ve predictive value, -ve predictive value, and overall accuracy. p values less than 0.05 was considered statistically significant. All statistical calculations were done using MedCalc® Statistical Software version 20.009 (MedCalc Software Ltd, Ostend, Belgium; https://www.medcalc.org; 2021).

Results

Demographic data

This prospective study included fifty adult patients with symptoms of perianal inflammatory disorders. As shown in Table 2, the patient population ($n = 50$) consisted of 44 (88%) males and 6 (12%) females with a mean age of 39 years (range 20–68 years).

Out of our fifty patients, twenty-seven (27/50, 54%) have presented with recurrent symptoms of perianal fistula, as shown in Table 3.

Table 2 Demographics of the study population according to the sex of the patients

	Frequency	Percentage
Male	44	88%
Female	6	12%
Total	50	100

Table 3 Demographics of the study population according to the perianal fistula recurrence

	Frequency	Percentage
Recurrent	27	54%
Non-recurrent	23	46%
Total	50	100

Analysis of the obtained data

Analysis of standard 2D images by the radiologist (R.F.E.S)

Regarding the internal opening site of the perianal fistula, eight patients had anterior midline opening at 12 o'clock, thirteen patients had midline posterior opening at 6 o'clock, six patients had a right-sided internal opening (1 at 7 o'clock, 4 at 10 o'clock, and 1 at 11 o'clock) and ten patients had a left-sided internal opening (5 at 1 o'clock, 2 at 2 o'clock, 2 at 3 o'clock and 1 at 5 o'clock). One patient presented with two perianal tracts with internal openings at 5 and 8 O'clock. The specific internal anal sphincter breaching site was not demonstrated in 12 MRI examinations.

Side branches were present in 15 (15/50, 30%) patients, abscesses in two (2/50, 4%) patients, horseshoe collections in six (6/50, 12%) patients, and supra-levator extension in eight (8/50, 16%) patients.

Analysis of 3D models

Interpretation of 3D models by the radiologist (M.Y.A) Regarding the radiologist's visualisation of the internal opening (M.Y.A), anterior midline openings were present at 12 O'clock in five patients, posterior midline opening at 6 o'clock in ten patients, a right-sided internal opening in eight patients (1 at 7 o'clock, 1 at 9 o'clock, 4 at 10 o'clock, and 2 at 11 o'clock.), and a left-sided internal opening in six patients (5 at 1 o'clock and 1 at 2 o'clock). The specific site of internal anal sphincter breaching was not recognised in 21 patients.

Side branches were present in fifteen (15/50, 30%) patients, abscesses in five (5/50, 10%) patients, horseshoe collections in six (6/50, 12%) patients, and supra-levator extension in eight (8/50, 16%) patients.

Interpretation of 3D models by the surgeon (F.S.F) Considering the detection of the internal opening by the surgeon (F.S.F), a midline anterior opening at 12 o'clock was present in five patients, a midline posterior opening at 6 o'clock in ten patients, a right-sided internal opening in eight patients (1 at 7 o'clock, 1 at 9 o'clock, 4 at 10 o'clock and 2 at 11 o'clock.) and a left-sided internal opening in five patients (2 at 1 o'clock, 1 at 2 o'clock, 1 at 3 o'clock and 1 at 5 o'clock). The exact site of internal anal sphincter breaching was not demonstrated in 22 patients.

Side branches were present in thirteen (13/50, 26%) patients, an abscess in one (1/50, 2%) patient, horseshoe collections in four (4/50, 8%) patients and supra-levator extension in eight (8/50, 16%) patients.

Examples of interpretation of 3D models are shown in Fig. 3, 4, 5, 6 and 7.

Comparison of reading of 3D models by the radiologist (M.Y.A.) and the surgeon (F.S.F) to 2D MRI findings Regarding visualisation of the site of the internal opening in 3D models in comparison with 2D MRI, both the radiologist and the surgeon showed the same specificity (100%). However, the reading of the radiologist showed higher sensitivity (76.32%) than that of the surgeon (73.68%) and higher accuracy (82.00%) compared to (80.00%) for the surgeon.

Considering the detection of side branches of perianal fistula in 3D models in comparison with 2D MRI, reading of the 3D models by the radiologist showed higher sensitivity (80%), specificity (91.43), and accuracy (88%) in the detection of side branches while reading by the surgeon showed sensitivity (60%), specificity (88.57%) and accuracy (80%).

In diagnosing abscesses in 3D models compared to 2D MRI, the radiologist's reading showed higher sensitivity (100%) in detecting the abscesses compared to the surgeon's reading (50%). However, the radiologist's reading of 3D models showed lower specificity (93.75%) and accuracy (94%) in the detection of the abscesses compared to those of the surgeon, with specificity (100%) and accuracy (98%).

On the subject of visualisation of horseshoe collections in 3D models in comparison with 2D MRI, reading of 3D models by the radiologist showed higher sensitivity (100.00%) than the surgeon (60%) and higher accuracy (96.00%) compared to (94.00%) by the radiologist and the surgeon, respectively. The surgeon showed higher specificity (97.78%) than the radiologist (95.56%).

Regarding the detection of supra-levator extension of the perianal fistula in 3D models in comparison with 2D MRI, reading of 3D models by the radiologist and the surgeon had the highest sensitivity (100%), specificity (100%) and accuracy (100%).

Sensitivity, specificity, positive predictive value (PPV), negative predictive value (NPV), and accuracy of reading 3D models by the radiologist and the surgeon are shown in (Tables 4 and 5).

Inter-observer agreement between the radiologist (M.Y.A.) and the surgeon (F.S.F) There was a statistically high inter-observer agreement between the radiologist and the surgeon, with a p-value < 0.0001 regarding the five different variables. The highest inter-observer agreement was

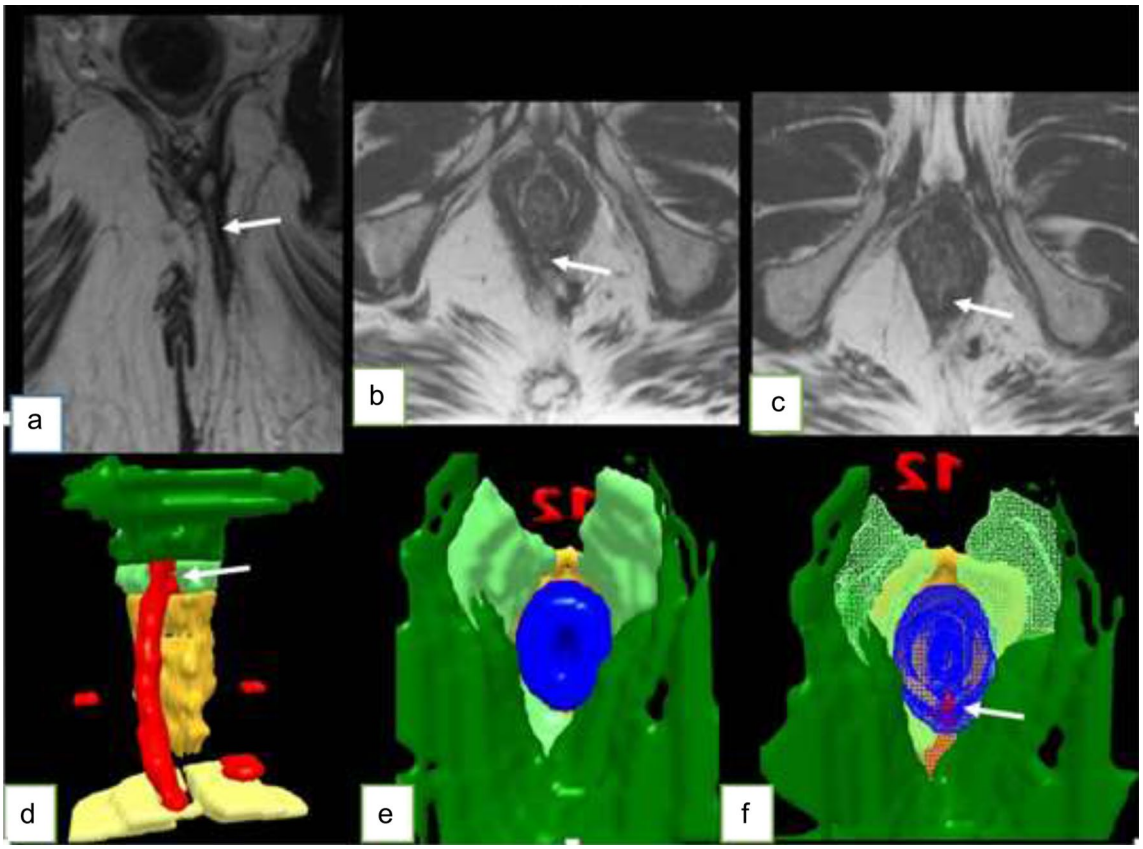

Fig. 3 A 54-year-old male patient presented with discharging perianal fistula. On DRE, a left high posterior tract is felt. 2D MRI in oblique coronal T2 (TR/TE, 3259/100) (**a**), oblique axial T2W images (TR/TE, 7228/100) (**b**, **c**) show a left posterior perianal tract extending along the left ischio-anal fossa to breech the left sling of puborectalis muscle at 5 o'clock (white arrows) (**b**), to end at the anal canal at 6 o'clock (white arrow) (**c**). Posterior coronal view (**d**) and top views (**e**, **f**) of the 3D model show a posterior left high tract, breeching the puborectalis muscle (white arrow). The internal opening was not seen by either the radiologist or the surgeon due to the overlap of structures. Retrograde, on applying the wireframe option, the site of the internal opening was identified (white arrow) (**f**)

in the visualisation of the supra-levator extension of perianal fistula (50/50, 100%), while the lowest inter-observer agreement was in the detection of the side branches by (44/50, 88%) (Table 6).

Discussion

Perianal fistula is a common condition with a relatively high recurrence rate. One of the most important causes of recurrence is the difficult pre-operative interpretation of the extent of the fistulous tract and its related pathologies. That may result in an inappropriate choice of the operative procedure, lengthy operations, and a high recurrence rate and post-operative co-morbidities [1, 2].

Surgeons may find difficulties interpreting lengthy MRI reports, especially in complex cases. That raised the concept of 3D post-processing of 2D MRI images. The surgeons may easily interpret the complementary 3D post-processing technique to help them choose the most appropriate surgical procedure [5].

Accordingly, the current study tested the accuracy of pre-operative 3D modelling in the assessment of the perianal fistula. Thus, it can be used as a road map for surgeons, aiding in the decision of the appropriate surgical procedure and reducing the intra and post-operative risk factors of recurrence. This study idea was based on a study published by Sahnan et al. [8] who conducted the first trial to test the interest of surgeons in the 3D modelling of perianal fistula using a survey for an international cohort of surgeons. Participants were asked about their interest in using 3D models of perianal fistula in their

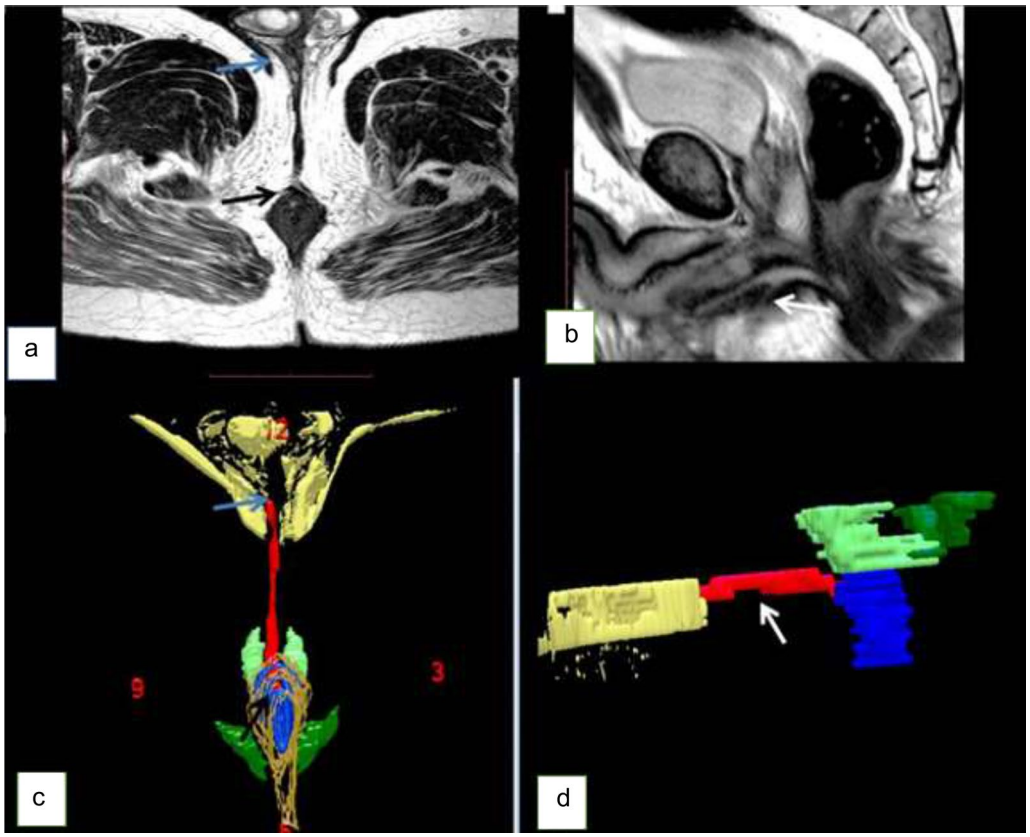

Fig. 4 A 50-year-old male patient presented with a high perianal fistula and came for a follow-up. 2D MRI with oblique axial T2 (TR/TE, 7228/100) (**a**) and sagittal T2W images (**b**) shows a tract starting at the right scrotal sac (blue arrow) extending posteriorly to breech the proximal third of deep external anal sphincter, with an internal opening at 12 o'clock (black arrow). MRI reveals a small side branch from the under-surface of the tract (white arrow in b). Lithotomy view (**c**) and side view (**d**) of the 3D model show the right scrotal opening (blue arrow), the tract (red) crossing from anterior to posterior, breaching both internal and external anal sphincters at 12 o'clock (black arrow). The radiologist or the surgeon did not identify the fore-mentioned side branch (white arrow)

institutions. They concluded that 85% of surgeons have expected 3D modelling to be beneficial for operative decisions, and 88% of surgeons would use it if obtainable.

To our knowledge, our study was the first to examine a large number of cases using 3D models. We examined fifty cases suffering from perianal fistula, in contrast to Lam et al. [9] and Smith et al. [4], who examined ten patients.

Using the technique of manual segmentation of MR images guaranteed high accuracy in the creation of 3D models.

In our study, the radiologist and the colorectal surgeon who individually interpreted the 3D models were both blinded to the standard 2D MRI findings, to avoid any bias in the visualisation of the 3D models. The data collected from both of them were compared to 2D MRI findings, and the percentage of inter-observer agreement was tested as well.

According to our knowledge, our study was the first to assess the accuracy of 3D models of perianal fistula in the context of sensitivity, specificity, PPV, NPV, and overall accuracy. Other studies were either demonstrative with a small number of cases or only tested the diagnostic agreement between surgeons and radiologists [10].

In our study, a 2D MRI of the perianal fistula has been chosen as the reference standard for the evaluation of the 3D models because MRI has high sensitivity and specificity in the detection of the perianal fistula and its related pathologies [11, 12].

According to our experience in our institution, T2 turbo spin echo is the best MRI sequence to trace the course of the perianal tract and visualise the other anatomical structures in the same MRI sequence. Therefore, we used the T2 turbo-spin echo sequence with a 3 mm thickness and no gap. Smith et al. [4] used turbo-spin echo T2 sequence for segmentation as well, but with 3D MRI acquisition. In contrast,

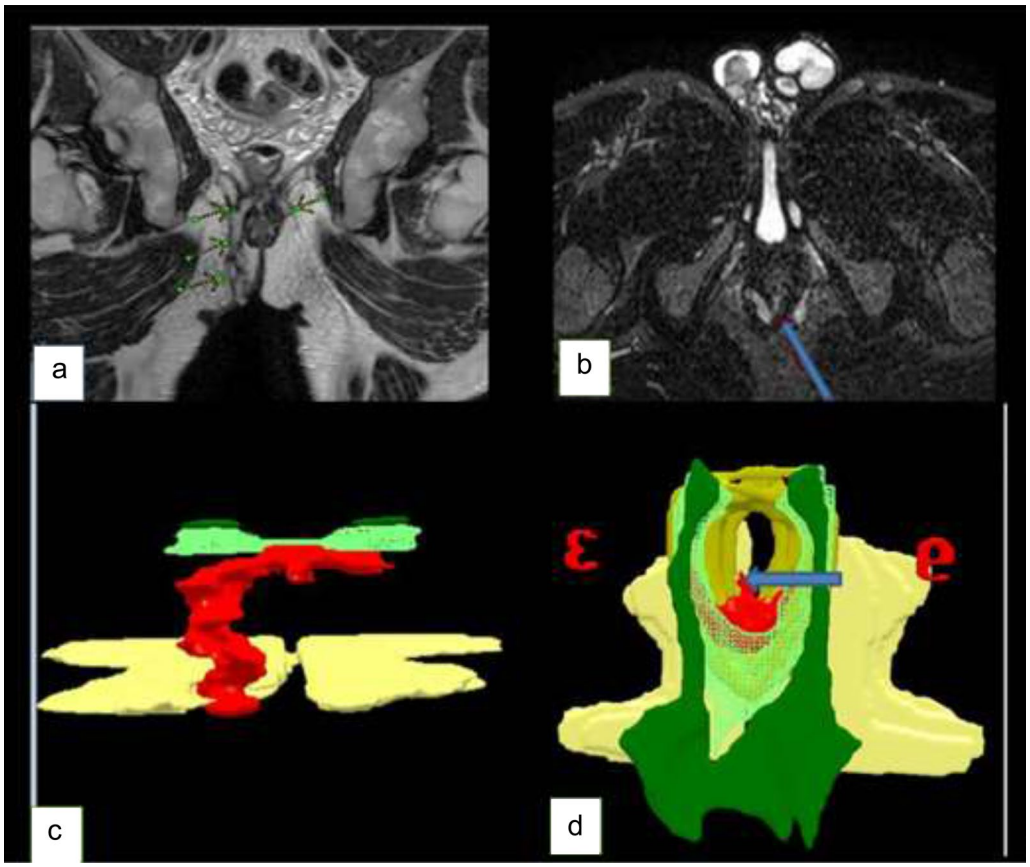

Fig. 5 A 25-year-old male patient presented with perianal pain and discharge. On DRE, a right perianal tract was felt; its external opening was seen at 10 o'clock, with a suspected posterior collection. 2D MRI in oblique coronal T2 (**a**) and oblique axial T2 FS (TR/TE, 4899/ 80) (**b**) showing a right-sided tract, starting at the perineal skin and extending cranially along the right ischio-anal fossa (green arrows), breaching the external anal sphincter, forming a posterior horseshoe collection at the level of the puborectalis muscle, with an internal opening at 6 o'clock (blue arrow). AP view (**c**) and top view (**d**) of 3D models show a right-sided tract (red) extending to the level of the puborectalis muscle (light green), forming a posterior horseshoe collection, with an internal opening seen at 6 o'clock (blue arrow)

Sahnan et al. [13] used T2 inversion recovery sequences for segmentation with a slice thickness of 4 mm. Day et al. [10] used T1-weighted images for segmentation of the anatomical structures while STIR sequences for visualisation of the fistulas, creating two separate volumes which were fused into one volume.

In the current study, each 3D model was saved as a representative movie. In contrast, in some recent studies [4, 14, 15], 3D models were printed using 3D printing tools, creating physical 3D models. Sousa et al. [16] assessed the 3D models on an innovative smartphone application to be used in pre- and intra-operative conditions.

In our study, the manual segmentation process took nearly two hours, which agreed with Guz et al. [15], who took about 2 h. After two months of experience, we were able to finish the whole process of manual segmentation in a time ranging from 20 to 40 min according to the fistula complexity. In contrast to our segmentation process, some studies used a semi-automated segmentation tool, such as Chapple et al. [17] and Lam [9]. They documented segmentation times of less than 30 min and about 15 min, respectively. Although manual segmentation took more time in our study, we preferred it to ensure precise tract delineation. In the current study, we used the anal clock on 3D models for better orientation of the site of the fistulous tracts, in agreement with Chapple et al. [17].

Regarding the detection of the internal opening of perianal tracts, the reason why the exact site of the

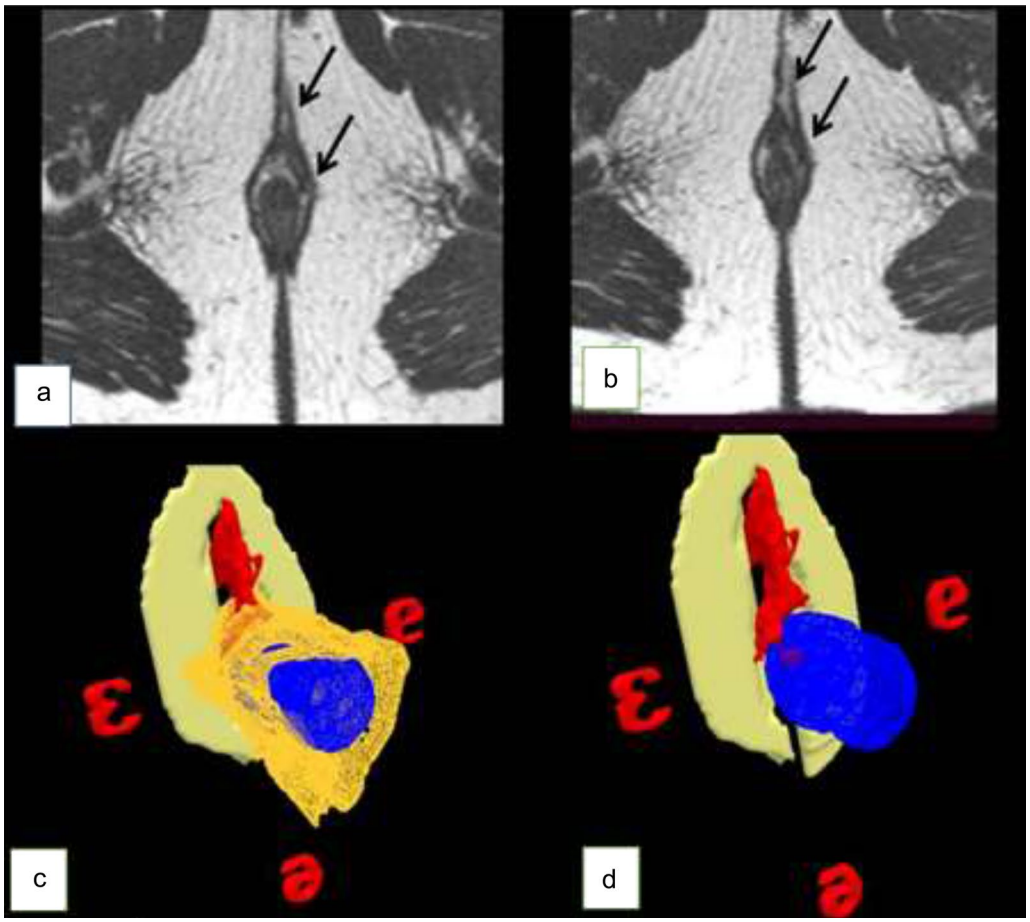

Fig. 6 A 40-year-old male patient presented with a discharging perianal fistula. On DRE, an anterior left-sided tract is felt. 2D MRI in oblique axial T2W images (TR/TE, 7228/100) shows a left-sided anterior tract (arrows) breaching the superficial part of the external anal sphincter at 2 o'clock. (**a**, **b**). 3D models on the oblique top view (**c**, **d**) show the tract breaching the external anal sphincter. The radiologist interpreted the AP extension of the tract as an abscess. The external anal sphincter (yellow) was removed to interpret the tract's extension (**d**) fully

internal opening was not easily recognised in some cases is the overlap of the anatomical structures which hindered the visualisation of the internal opening. At the same time, the readers were provided with a non-modifiable movie of each 3D model.

In the detection of the abscesses, the absence of an objective measuring tool in the 3D models was misleading the radiologist who subjectively considered a widened portion of the fistulous tract as an abscess.

Concerning the detection of supra-levator extension, 3D models showed 100% sensitivity, specificity, and accuracy for both the radiologist and the surgeon. Thus emphasising the easiness of interpretation of all cases presented with a supra-levator extension of perianal tracts.

Our results revealed statistically significant inter-observer diagnostic agreement between the interpretation of 3D models by the radiologist and the surgeon, with p-value < 0.0001, which gave the impression that 3D models can be easily interpreted by radiologists and surgeons as well. Those results agreed with Day et al. [10], who tested the diagnostic agreement between a surgeon and two radiologists, comparing the 3D model with 2D MRI.

Our study had limitations

The inability to measure the size or the volume of the tracts on the 3D models; therefore, a measuring scale is recommended. This agreed with Sahnan et al. [13], who displayed measurements in the 3D models, including volume, surface area, length, and distance between the anus and the internal opening. Detection of the internal opening was sometimes difficult in 3D models due to the overlap of the anatomical structures in the 3D model and, on the other side, the inability of the reader to make changes in the 3D models. This

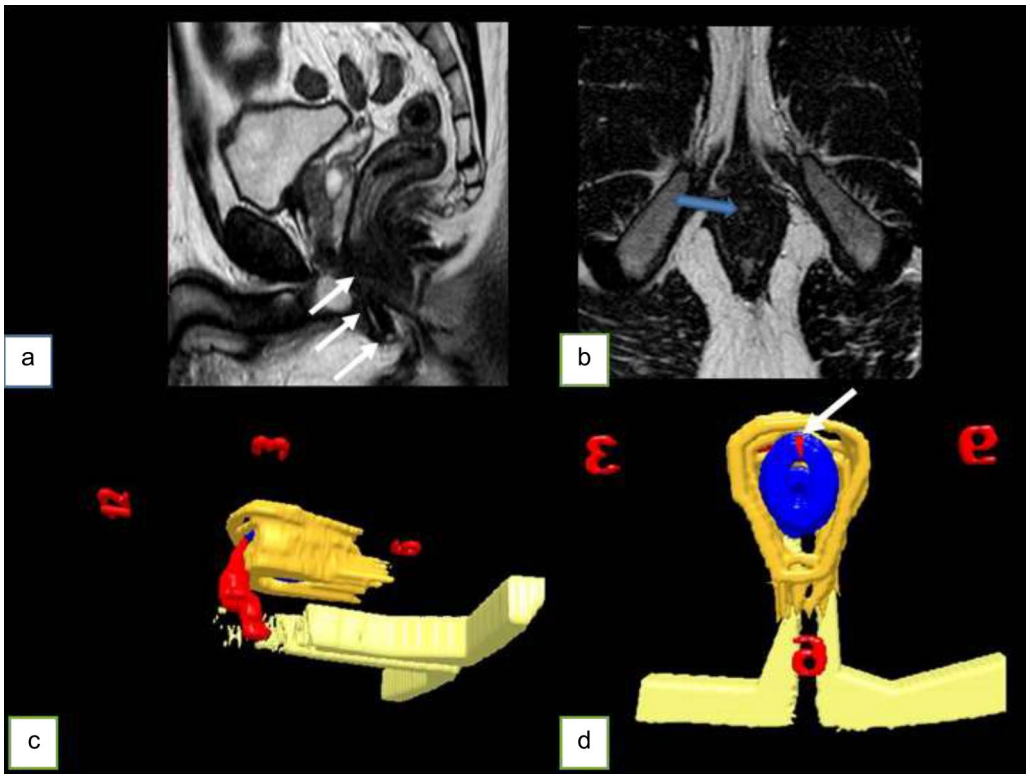

Fig. 7 A 38-year-old male patient; with a history of drainage of perianal abscess one year ago. He presented with discharging perianal fistula of one-month duration. On DRE, a left low perianal tract is felt, with an external opening seen at 2 o'clock. 2D MRI showing sagittal T2 (TR/TE, 3000/90) (**a**) and oblique axial T2W images (TR/TE, 7228/100) (**b**) with an anterior tract (white arrows), extending cranially to breech the external anal sphincter, with an enteric opening at 12 o'clock (blue arrow). Side view (**c**) and top view (**d**) of the 3D model show the tract (red) extending cranially to breech the external anal sphincter (yellow) with an internal opening seen breaching the internal anal sphincter (blue) at 12 o'clock (White arrow)

Table 4 Sensitivity, specificity, PPV, NPV, and accuracy of reading 3D models by the radiologist

	Internal opening		Abscess collections		Horseshoe collections		Supra-levator extension		Side branches	
	Value (%)	95% CI	Value (%)	95% CI	Value (%)	95% CI	Value (%)	95% CI	Value (%)	95% CI
Sensitivity	76.32%	59.76–88.56%	100.00%	15.81–100.00%	100.000%	47.818–100.000%	100.00%	63.06–100.00%	80.00%	51.91–95.67%
Specificity	100.00%	73.54–100.00%	93.75%	82.80–98.69%	95.556%	84.851–99.457%	100.00%	91.59–100.00%	91.43%	76.94–98.20%
PPV	100.00%			18.23–66.60%	71.429%	39.210–90.645%	100.00%		80.00%	56.83–92.40%
NPV	57.14%	42.97–70.23%	100.00%		100.000%		100.00%		91.43%	79.41–96.72%
Accuracy	82.00%	68.56–91.42%	94.00%	83.45–98.75%	96.000%	86.286–99.512%	100.00%	92.89–100.00%	88.00%	75.69–95.47%

Table 5 Sensitivity, specificity, PPV, NPV, and accuracy of reading 3D models by the surgeon

	Internal opening		Abscess collections		Horseshoe collections		Supra-levator extension		Side branches	
	Value (%)	95% CI	Value (%)	95% CI	Value (%)	95% CI	Value (%)	95% CI	Value (%)	95% CI
Sensitivity	73.68%	56.90–86.60%	50.00%	1.26–98.74%	60.00%	14.66–94.73%	100.00%	63.06–100.00%	60.00%	32.29–83.66%
Specificity	100.00%	73.54–100.00%	100.00%	92.60–100.00%	97.78%	88.23–99.94%	100.00%	91.59–100.00%	88.57%	73.26–96.80%
PPV	100.00%		100.00%	100.00%	75.00%	27.54–95.95%	100.00%		69.23%	45.02–86.08%
NPV	54.55%	41.35–67.14%	97.96%	92.31–99.48%	95.65%	88.25–98.47%	100.00%		83.78%	73.32–90.66%
Accuracy	80.00%	66.28–89.97%	98.00%	89.35–99.95%	94.00%	83.45–98.75%	100.00%	92.89–100.00%	80.00%	66.28–89.97%

Table 6 Inter-observer agreement between the radiologist and the surgeon

	Internal opening	Side branches	Abscess collections	Horseshoe collection	Supra-levator extension
Agree	49/50 (98%)	44/50 (88%)	46/50 (92%)	48/50 (96%)	50/50 (100%)
Disagree	1/50 (2%)	6/50 (12%)	4/50 (8%)	2/50 (4%)	0/50 (0%)

would have been avoided if the readers of the 3D model were able to remove or add the anatomical structures according to their desire and not just provided by a representative movie. Segmentation of the 3D models mainly depends on the perfect interpretation of standard 2D MRI images and the perfect tracing of the anatomical structures. Therefore, we recommend that expert radiologists fully report the standard 2D MRI of the perianal fistula first and ensure accurate segmentation of the fistulous tracts; otherwise, a 3D model may provide inaccurate information to the surgeon.

Conclusions

The pre-operative availability of 3D MRI modelling enhanced the surgeon's visualisation of complex perianal fistula and its complications. It is considered a good road map for delineating the course of the perianal tract and its associated pathologies before and even during the surgical procedure.

We recommend the utilisation of 3D modelling of perianal fistula in the clinical practice, principally in complex and recurrent cases, providing the full extent and its associated pathologies, which could help in better operative outcomes by reducing the pre-operative risk factors of recurrence, especially in the detection of supra-levator extension. Moreover, it is considered a simple teaching tool for junior surgeons in the interpretation of complex cases of perianal tracts.

Although this new technology is relatively expensive, its cost–benefit ratio is considered low compared to the expenses of recurrent hospitalisation and related complications.

Abbreviations

3D	Three dimensions
2D	Two dimensions
MRI	Magnetic resonance imaging
SREC	Scientific research and ethics committee
IRB	Institutional review board
DRE	Direct rectal examination
PPV	Positive predictive value
NPV	Negative predictive value

Acknowledgements

Medical editor Katharine O'Moore-Klopf, ELS (East Setauket, NY, USA) provided professional English-language editing of this article.

Author contributions

MSR and MYA conceived of the idea for the study. RFES developed the study's hypothesis. AF obtained full medical histories from the participants and examined participants by digital rectal examination. RFES reported the findings regarding perianal fistulas obtained by standard 2D MRI. MSR designed 3D models from the standard 2D MRI protocol. FSF and MYA read the 3D models. MSR collected and analysed the data. MSR wrote the manuscript with the support of MYA and RFES, AF and HASS verified the analytical methods and revised the manuscript critically for important intellectual content. RFES and HASS supervised the work. All authors provided critical feedback and helped shape the research, analysis, and final version of the manuscript. All authors have read and approved the manuscript.

Author's information

Rania Farouk El Sayed, MD, PHD
Founder of the "ESUR Pelvic Floor Imaging Working Group" Europe 2005
Founding Member of the "SAR Pelvic Floor DFP" USA 2014.

Funding

No funding was received for performing this study.

Availability of data and materials

All the data and materials used in the manuscript are available with the corresponding author upon reasonable request.

Declarations

Ethics approval and consent to participate

This prospective study was ethically approved by the "Scientific Research and Ethics Committee (SREC) of the Radiology Department, Cairo University, followed by the institutional review board (IRB) of the faculty of medicine Cairo University hospitals. Number: I-191015. Informed verbal consent was taken from the participants. No additional intervention was needed for the routinely referred 2D perianal fistula MRI protocol from the colorectal surgical clinic.

Consent for publication

No participant's personal information is included in our manuscript, and before publishing, names were taken from all the photos and figures.

Competing interests

We have no competing interests.

Received: 10 November 2022 Accepted: 7 February 2023
Published online: 16 March 2023

References

1. Emile SH (2020) Recurrent anal fistulas: When, why, and how to manage? World J Clin Cases 8:1586–1591. https://doi.org/10.12998/WJCC.V8.I9.1586
2. Bakhtawar N, Usman M (2019) Factors increasing the risk of recurrence in fistula-in-ano. Cureus 11(3):e4200-4207. https://doi.org/10.7759/cureus.4200
3. Mei Z, Wang Q, Zhang Y et al (2019) Risk factors for recurrence after anal fistula surgery: a meta-analysis. Int J Surg 69:153–164. https://doi.org/10.1016/j.ijsu.2019.08.003
4. Smith NL, D'Souza B, Lam D et al (2021) Does 3D MRI and 3D printing help the colorectal surgeon manage perianal Crohn's disease? Tech Coloproctol 25:249–250. https://doi.org/10.1007/s10151-020-02375-7

5. Sousa EC, Nogueirac AT, Rochad BA et al (2018) Three-dimensional virtual reconstruction as a tool for preoperative planning in the management of complex anorectal fistulas. J Coloproctol 38(1):77–81
6. Gupta R, Kumar S, Kumar A et al (2021) Magnetic resonance imaging of perianal fistulas in clinically symptomatic patients and the correlation among plain, contrast, and post jelly MRI fistulography. J Coloproctol 41:265–274. https://doi.org/10.1055/s-0041-1730260
7. Kumar N, Agarwal Y, Chawla AS et al (2015) MRI of perianal fistulae: a pictorial kaleidoscope. Clin Radiol 70:1451–1461. https://doi.org/10.1016/j.crad.2015.09.001
8. Sahnan K, Adegbola SO, Tozer PJ et al (2017) P126 Experience of 3D modelling in perianal fistula disease and survey of international surgical interest. J Crohn's Colitis 11:S140–S141. https://doi.org/10.1093/ecco-jcc/jjx002.252
9. Lam D, Yong E, D'Souza B et al (2018) Three-dimensional modelling for Crohn's fistula-in-ano: a novel, interactive approach. Dis Colon Rectum 61:567–572. https://doi.org/10.1097/DCR.0000000000001084
10. Day NJ, Earnshaw D, Salazar-Ferrer P et al (2013) Pre-operative mapping of fistula-in-ano: a new three-dimensional MRI-based modelling technique. Color Dis 15:699–702. https://doi.org/10.1111/codi.12438
11. Jajoo SS, Gupta P, Ramesh KH et al (2018) Clinical correlation and MRI finding in the management of fistula in ano. Indian J Surg 80:347–352. https://doi.org/10.1007/s12262-017-1607-1
12. Devi BV, Supraja C, Mutheeswaraiah Y et al (2017) MRI in the diagnosis and pre-operative classification of perianal and anal fistulas. Int J Res Med 6(1):64–70
13. Sahnan K, Adegbola SO, Tozer PJ et al (2018) Improving the understanding of Perianal Crohn fistula through 3D modelling. Ann Surg 267(6):e105–e107. https://doi.org/10.1097/SLA.0000000000002629
14. Sahnan K, Adegbola SO, Tozer PJ et al (2018) Innovation in the imaging of perianal fistula: a step towards personalised medicine. Ther Adv Gastroenterol 11:1–7. https://doi.org/10.1177/1756284818775060
15. Guz W, Ozóg L, Aebisher D et al (2021) The use of magnetic resonance imaging technique and 3D printing in order to develop a three-dimensional fistula model for patients with Crohn's disease: personalised medicine. Prz Gastroenterol 16:83–88. https://doi.org/10.5114/pg.2020.101629
16. Sousa EC, Eulálio MN, Nogueira AT et al (2019) Use of three-dimensional virtual images for planning surgery of complex anal fistulas: a new technology available via smartphone. Tech Coloproctol 23:775–778
17. Chapple KS, Purves J, Metherall P et al (2017) Three-dimensional magnetic resonance visualisation of fistula-in-ano. Tech Coloproctol 21:97–99

Publisher's Note