Fares *Egypt J Radiol Nucl Med* (2023) 54:55
https://doi.org/10.1186/s43055-023-01005-0

Egyptian Journal of Radiology and Nuclear Medicine

CASE REPORT

Open Access

Metastases to breast from primary lung cancer

Nevien Ragae Fares*

Abstract

Background Metastatic involvement of the breast is relatively rare and has an incidence of 0.5–3%. Lesions that metastasize to the breast may produce changes that look similar to those of primary breast cancer on mammography, but they are more likely to be multiple and are frequently bilateral.

Case presentation A 38-year-old female complaining of progressive proptosis with bilateral palpable breast lumps. She was referred to the breast imaging unit to evaluate the nature of those breast lesions, diagnostic mammography, and complementary ultrasound was done that revealed multiple variable-sized well-defined masses scattered all over their parenchyma. True cut biopsy was taken from one of them that show metastatic carcinoma of non-mammary origin. Immunophenotyping revealed neuroendocrine carcinoma of lung origin. A metastatic workup was done that revealed horrible metastatic deposits in multiple organs and the primary was found in the lung.

Conclusions Metastasis to the breast from extra-mammary carcinomas is extremely rare. The most common types are malignant melanoma, secondary lymphomas, and tumors of neuroendocrine origin like Small cell carcinoma. Histopathology and sometimes immunophenotyping can provide the diagnosis.

Keywords Small cell lung cancer, Breast metastasis, Immunophenotyping

Background

Metastatic involvement of the breast is relatively rare. Metastatic disease of the breast is therefore often an unexpected diagnosis in a female patient presenting with a breast mass. The commonest cause is spread from contralateral breast carcinoma. The most common cancers to metastasize to the breast are, in declining order of frequency, malignant melanoma, lymphoma, lung cancer especially that of neuroendocrinal origin, ovarian carcinoma, soft tissue sarcoma, and gastrointestinal and genitourinary tumors. Besides these, metastases from osteosarcoma, thyroid neoplasms, and cervical, vaginal, and endometrial carcinomas [1].

*Correspondence:
Nevien Ragae Fares
Nova.fares.33@gmail.com; Besa33@hotmail.com
Minia Oncology Center, Minia Governate, Minia, Egypt

Case presentation

A 38-year-old female came with progressive proptosis and palpable bilateral breast masses. She was referred to the breast imaging unit to evaluate the nature of those breast lesions, diagnostic mammography, and complementary ultrasound was done that revealed multiple variable-sized well-defined masses scattered all over their parenchyma (Figs. 1 and 2).

True cut biopsy was taken from one of the breast lesions that show metastatic carcinoma of non-mammary origin. Immunophenotyping revealed neuroendocrine carcinoma of lung origin.

Computed tomography of the head, neck, chest, abdomen, and pelvis was requested as a metastatic workup that revealed horrible metastatic deposits in multiple organs with the primary at the lung. Another true cut biopsy was taken from a large destructive bony lesion revealed also metastatic carcinoma and immunophenotyping showed a neuroendocrine carcinoma of lung origin (Fig. 3).

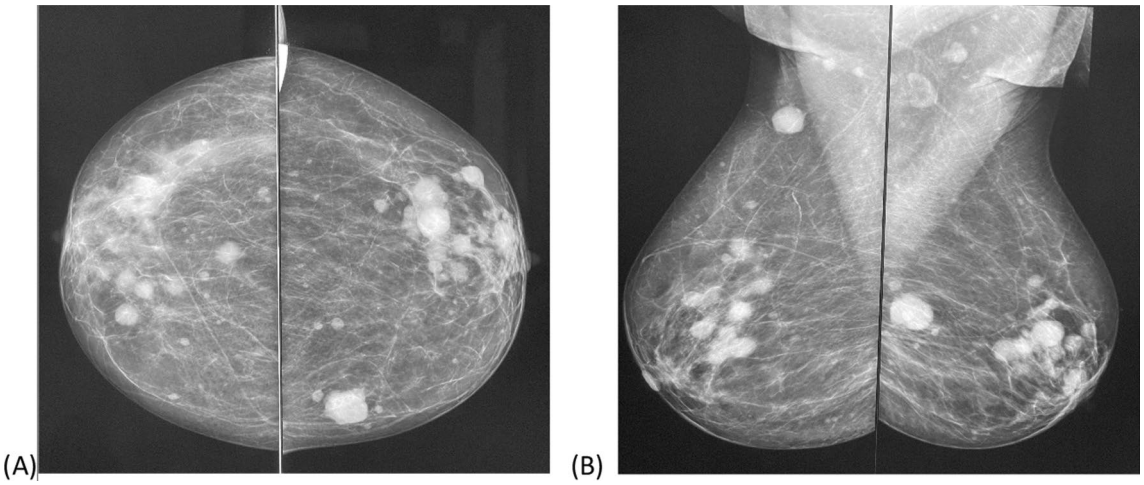

Fig. 1 Diagnostic Digital Mammography CC & MLO (**A**, **B**) show multiple variable-sized well-circumscribed lesions scattered all over the parenchyma of both breasts with no either macro-calcifications or micro-calcifications. No speculation

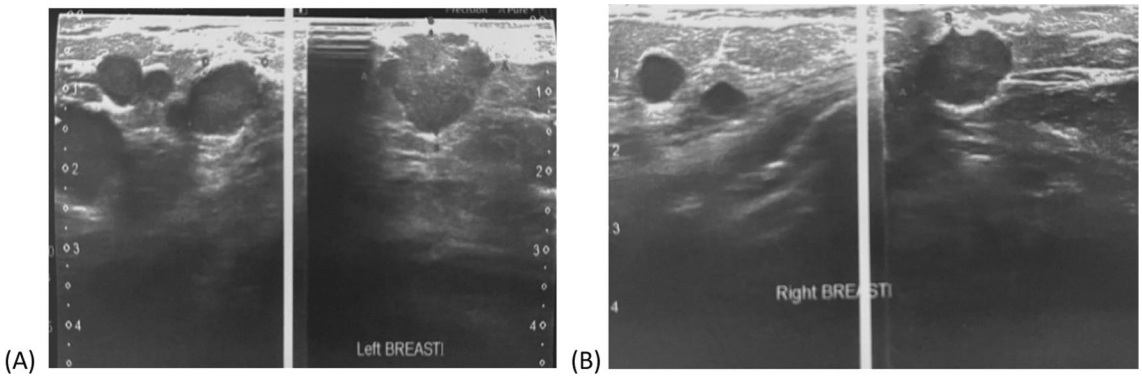

Fig. 2 Diagnostic ultrasound of both breasts revealed multiple well-circumscribed soft tissue masses nearly all of them of the same echogenicity with some of them subdermal in location. Most of them are not respecting related tissue plans

Discussion

Metastatic cancer is an unexpected diagnosis in a female patient presenting with a breast mass and is relatively uncommon due to the large area of fibrous tissue and relatively poor blood supply of the breast. Mammography usually reveals a well-defined rounded mass and multiple or bilateral lesions are seen. In contrast with primary breast cancers, calcification is rare and speculation uncommon [2].

Metastases to the breast typically lie in the subcutaneous plane and hence are usually palpable. Primary breast carcinomas arise from the glandular epithelium and are usually deep-seated but also often palpable [3].

Breast masses presenting as metastatic spread from primary lung cancer can be difficult to diagnose in the absence of new and concerning respiratory symptoms. Histopathology can provide the diagnosis. However, in most instances, immunohistochemical staining is required to confirm the primary site of the tumor as evidenced in our case [4].

Conclusions

Metastasis to the breast from extra-mammary carcinomas is extremely rare. The most common types are malignant melanoma, secondary lymphomas, and tumors of neuroendocrine origin like Small cell carcinoma. Histopathology and sometimes immunophenotyping can provide the diagnosis.

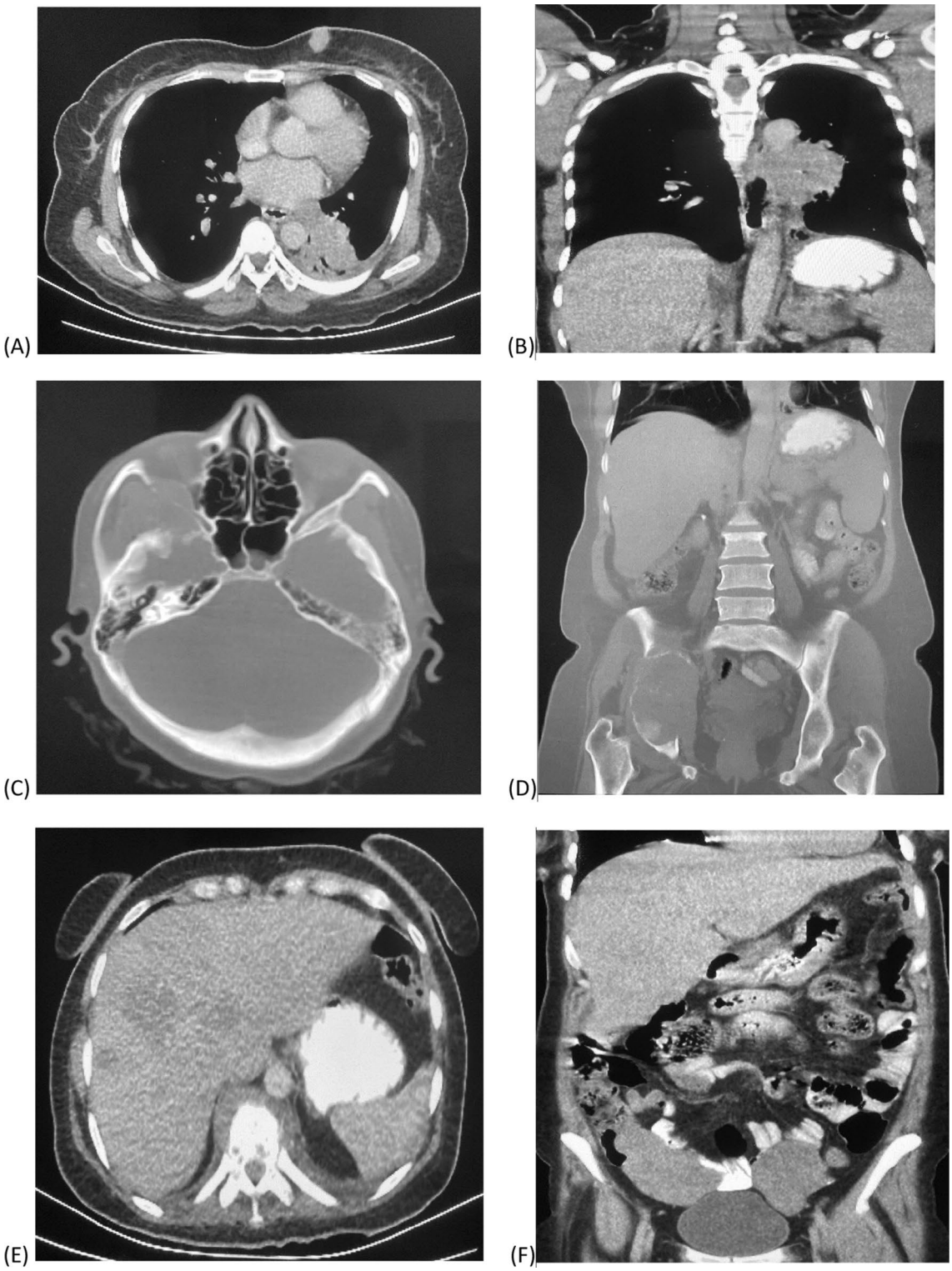

Fig. 3 Contrast-Enhanced staging CT. Thorax CT with axial and coronal (**A**, **B** mediastinal window) show speculated soft tissue mass lesion that involves the posteroinferior segment of left lower lung lobe abutting the related vascular structures (descending aorta and left atrium) as well as infiltrating-related pleural reflections. It is not respecting related tissue plans. Skull base axial cut and pelvic bones coronal cut (**C**, **D** bone window) show expansible destructive bony lesion seen involving right. Greater wing of sphenoid and Rt. Iliac bone with considerable soft tissue components, respectively. Abdomen and pelvis CT (**E**, **F**) axial and coronal soft tissue windows, respectively, show multiple hepatic focal lesions and bilateral solid adnexal lesions

Abbreviations

CC	Cephalocaudal
MLO	Mediolateral oblique
CT	Computed tomography

Acknowledgements
Not applicable

Author contributions
NRF: have made the first radiological diagnosis, collect the data and wright the case as a case report. All authors read and approved the final manuscript.

Funding
No funding disclosure.

Availability of data and materials
The datasets used and/or analyzed during the current study are available from the main author on reasonable request.

Declarations

Ethics approval and consent to participate
Approved by ethics committee of Minia Oncology Center.

Consent for publication
Written informed consent was obtained from the patient's relatives for the publication of his case report and accompanying images as the patient was died.

Competing interests
The authors declare that they have no competing interests.

Received: 2 January 2023 Accepted: 13 March 2023
Published online: 21 March 2023

References

1. Vergier B, Trojani M, de Mascarel I, Coindre JM, Le Treut AJ (1991) Metastases to the breast: differential diagnosis from primary breast carcinoma. Surg Oncol 48:112–116
2. Akçay MN (2002) Metastatic disease in the breast. Breast 11(6):526–528. https://doi.org/10.1054/brst.2002.0467. (**PMID: 14965721**)
3. Yeh CN, Lin CH, Chen MF (2004) Clinical and ultrasonographic characteristics of breast metastases from extramammary malignancies. Am Surg 70:287–290
4. Noguera JJ, Martinez-Miravete P, Idoate F et al (2007) Metastases to the breast: a review of 33 cases. Australas Radiol 51:133–138

Publisher's Note