Kobayashi *et al. Egypt J Radiol Nucl Med* (2023) 54:106
https://doi.org/10.1186/s43055-023-01052-7

Egyptian Journal of Radiology and Nuclear Medicine

RESEARCH

Open Access

Role of preoperative SPECT/CT standardized uptake values in medication-related osteonecrosis of the jaw: a preliminary study of SPECT/CT in relation to cone-beam CT and histopathological findings of the resected bone of mandibulectomy

Eizaburo Kobayashi[1], Yasuhito Tezuka[2], Junya Ono[3], Yasuo Okada[3] and Ichiro Ogura[2*]

Abstract

Background SPECT/CT has been applied for preoperative planning of MRONJ. Furthermore, the SUV using bone SPECT/CT has enabled quantitative analysis of jaw lesions. This study aimed to evaluate the role of preoperative SPECT/CT SUVs in MRONJ, especially SPECT/CT in relation to CBCT and histopathological findings of the resected bone of mandibulectomy. The preliminary study was conducted on five MRONJ patients who underwent mandibulectomy after SPECT/CT.

Results The SUVmax and SUVmean of MRONJ in all cases (19.5 ± 5.6 and 5.5 ± 0.8) were significantly higher than those of right side of the MRONJ (8.5 ± 2.0 and 2.7 ± 0.5) and left side of the MRONJ (7.2 ± 1.6 and 2.7 ± 0.4), respectively. The CBCT of all cases showed osteolytic and sclerotic internal texture and sequestrum. The histopathological characteristics of all cases showed necrotic bone and granulation tissue with the bone circumference surrounded by inflammatory cells.

Conclusions The preliminary results indicated a difference between MRONJ and right and left sides of the MRONJ in SPECT/CT SUVs. The SUVs has enabled quantitative analysis for surgical planning of MRONJ.

Keywords SPECT/CT, SUV, MRONJ

*Correspondence:
Ichiro Ogura
ogura@ngt.ndu.ac.jp
Full list of author information is available at the end of the article

Background

MRONJ is a well-known complication of treatment with bisphosphonates and denosumab for patients with osteoporosis or bone metastases [1, 2]. Patients with MRONJ are evaluated using scintigraphy, CT and MRI [3–5].

In the recent years, bone SPECT/CT has been applied for preoperative planning of MRONJ [6, 7]. Furthermore, the SUV using the SPECT/CT has enabled quantitative analysis of jaw lesions [8–10]. The SUV may be useful for the assessment of MRONJ [11–13]. Furthermore, both SPECT and CBCT could sensitively detect osteomyelitis/osteonecrosis lesions [14]. CBCT is effective to investigate surgical specimen of MRONJ [15]. However, no reports have been published on relationship SPECT/CT SUV and CBCT of the resected bone of mandibulectomy for MRONJ. The purpose of this study was to evaluate the role of preoperative SPECT/CT SUVs in MRONJ, especially SPECT/CT in relation to CBCT and histopathological findings of the resected bone of mandibulectomy.

Methods

Patient population

MRONJ patients (five women; mean age 82.2 years) who were diagnosed by the position paper [1] and underwent mandibulectomy after preoperative MDCT and SPECT/CT at our hospital from February 2020 to January 2022 were included in this study. The resected bone of mandibulectomy were analyzed using CBCT. The histopathological diagnoses were obtained by those resected bone in all cases. The patients with osteoporosis or bone metastases were diagnosed and treated at other hospital. The protocol was approved by the Ethics Committee of our University.

Image acquisition and analysis

Bone SPECT/CT was performed 4 h after injection of 740 MBq ^{99m}Tc-HMDP (Clear Bone Injection, Nihon Medi-Physics, Tokyo, Japan) with Optima NM/CT 640 (GE Healthcare Japan, Tokyo, Japan) [16]. Furthermore, the SUVmax and SUVmean were analyzed with a dosimetry software (Xeleris 4DR and Q. Volumetrix MI, GE Healthcare Japan, Tokyo, Japan) [16]. The VOI on SPECT/CT images was drawn over the MRONJ, right and left sides of the MRONJ by two radiologists. We defined high spot area on SPECT/CT as the MRONJ (sky blue) and right (red) and left (green) sides of the high spot area (Fig. 1). The SUVmax and SUVmean in a given VOI were calculated automatically (Fig. 2).

Imaging for the surgical planning was performed using a 16-MDCT (Aquilion TSX-101A; Canon Medical Systems) [3]. The surgical planning was decided using the preoperative MDCT imaging, such as osteolytic change of the jaw, sclerotic lesion, sequestrum separation and periosteal bone proliferation [3]. Furthermore, operators referred to the high spot area on the SPECT/CT for surgical planning.

Imaging of resected bone of mandibulectomy was performed using CBCT (Fine Cube; Yoshida, Tokyo, Japan) [15] and evaluated by two radiologists. The histopathological findings were evaluated by two pathologists using all histological slides stained with hematoxylin and eosin.

Statistical analyses

Statistical analysis was done using one-way analysis of variance. *P* values lower than 0.05 indicate significant differences using statistical software (IBM SPSS Statistics 26, IBM Japan, Tokyo, Japan).

Results

Table 1 shows SPECT/CT SUVs of five cases with MRONJ. The SUVmax and SUVmean for MRONJ in all cases (19.5 ± 5.6 and 5.5 ± 0.8) were significantly higher than those of right side of the MRONJ (8.5 ± 2.0 and 2.7 ± 0.5) and left side of the MRONJ (7.2 ± 1.6 and 2.7 ± 0.4), respectively. For all cases, the CBCT of the resected bone of mandibulectomy showed osteolytic and sclerotic internal texture, and sequestrum. The histopathological characteristics of all cases indicated necrotic bone and granulation tissue with the bone circumference surrounded by inflammatory cells. Figures 1, 2, 3, 4, and 5 show SPECT/CT, MDCT, CBCT and histopathological findings of MRONJ of the left side of the mandible in an 82-year-old female (Case 2).

Discussion

This study presented the preoperative SPECT/CT SUVs in MRONJ, especially SPECT/CT in relation to CBCT and histopathological findings of the resected bone of mandibulectomy, and showed that SUVmax and SUVmean for MRONJ in all cases by SPECT/CT were significantly higher than those of right and left sides of the MRONJ.

Miyashita et al. [6] indicated SPECT/CT image was effective for evaluation of the extent and surgical planning for mandibular surgery of MRONJ. Furthermore, Miyashita et al. [7] assessed preoperative SPECT/CT by comparison with histopathological findings of resected bone in MRONJ. We also consider that SPECT/CT may be effective for surgical procedure in MRONJ, because increased radiotracer uptake in the jaw was dependent on the presence of regenerative vascularity with necrosis or inflammation.

The SPECT/CT SUVs, such as voxel-based quantitative parameters, may be effective for the assessment of

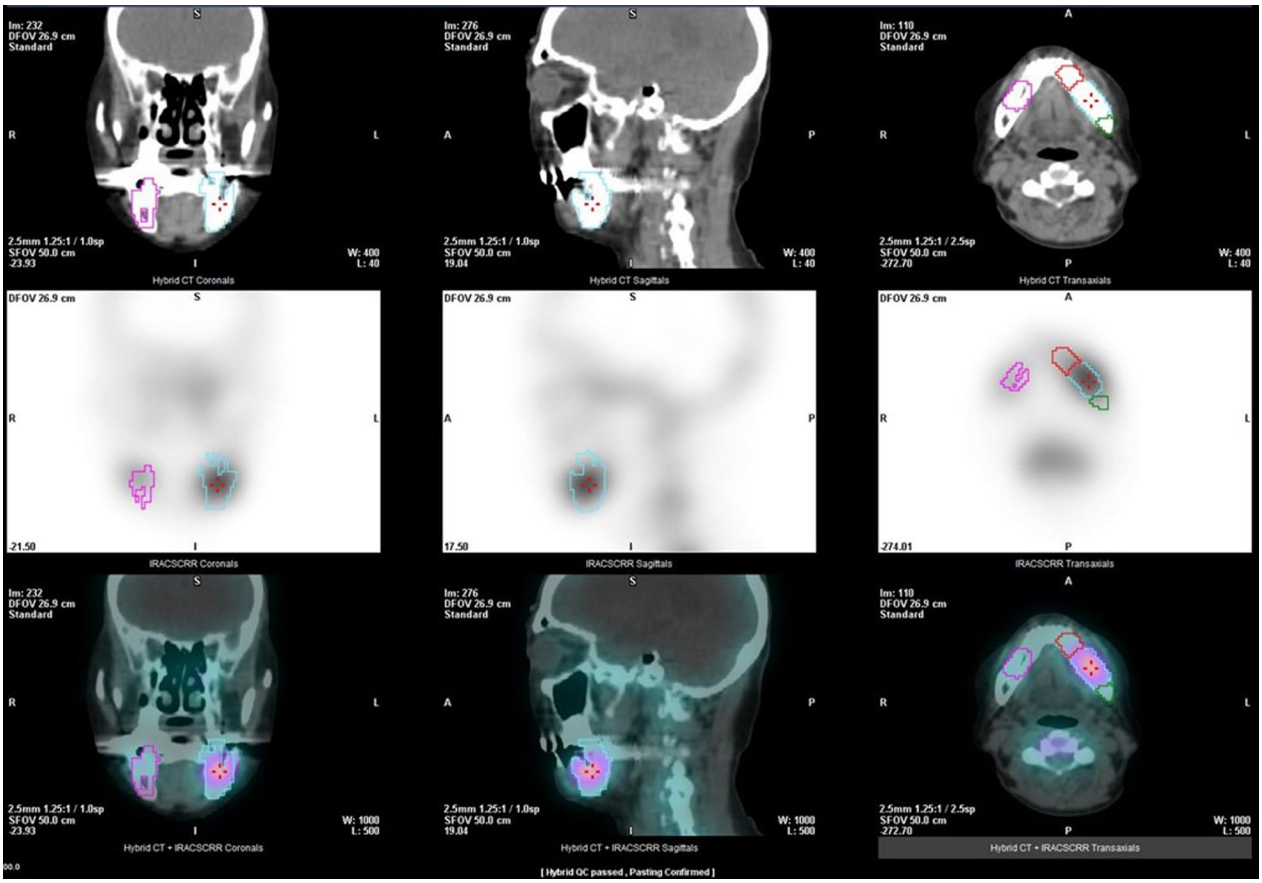

Fig. 1 SPECT/CT images of medication-related osteonecrosis of the jaw (MRONJ) of the left side of the mandible in an 82-year-old female (Case 2). Volume of interests were drawn over the MRONJ (sky blue), right side of the MRONJ (red) and left side of the MRONJ (green) using the CT, SPECT and SPECT/CT transaxial, coronal and sagittal images as the anatomical reference

MRONJ [9–13]. In this study, the CBCT and histopathological findings of resected bone of mandibulectomy were investigated using preoperative SPECT/CT SUVs. The results showed that SUVmax and SUVmean for MRONJ in all cases (19.5 ± 5.6 and 5.5 ± 0.8) were significantly higher than those of right side of the MRONJ (8.5 ± 2.0 and 2.7 ± 0.5) and left side of the MRONJ (7.2 ± 1.6 and 2.7 ± 0.4), respectively. We consider that the quantitative decision making to help outline the surgical margins based on SUV evaluation can be effective for surgical procedure in MRONJ, although the results were preliminary survey.

For all cases in this study, the CBCT of the resected bone of mandibulectomy showed osteolytic and sclerotic internal texture and sequestrum. Furthermore, the histopathological characteristics indicated necrotic bone and granulation tissue with the bone circumference surrounded by inflammatory cells. We consider that postoperative CBCT to examine the resected specimen may be useful for radiological features and boundaries in MRONJ.

The SUVs derived from bone SPECT/CT include maximum SUV, mean SUV and peak SUV [9]. In this study, we analyzed the SUVmax and SUVmean for MRONJ. The SUVmax is just one point in the VOI. Therefore, the SUV may not always represent the histopathological findings of each lesion. While the SUVmean is suitable value for pathophysiology, although the SUVmean is depended on VOI [17]. We suggest that the SUVmean can be effective for surgical procedure of MRONJ with the dosimetry software. Furthermore, at present, we have evaluated surgical planning for MRONJ with MDCT, not CBCT. However, we conclude that preoperative SPECT/CT SUVs and CBCT can be effective for surgical planning in this study.

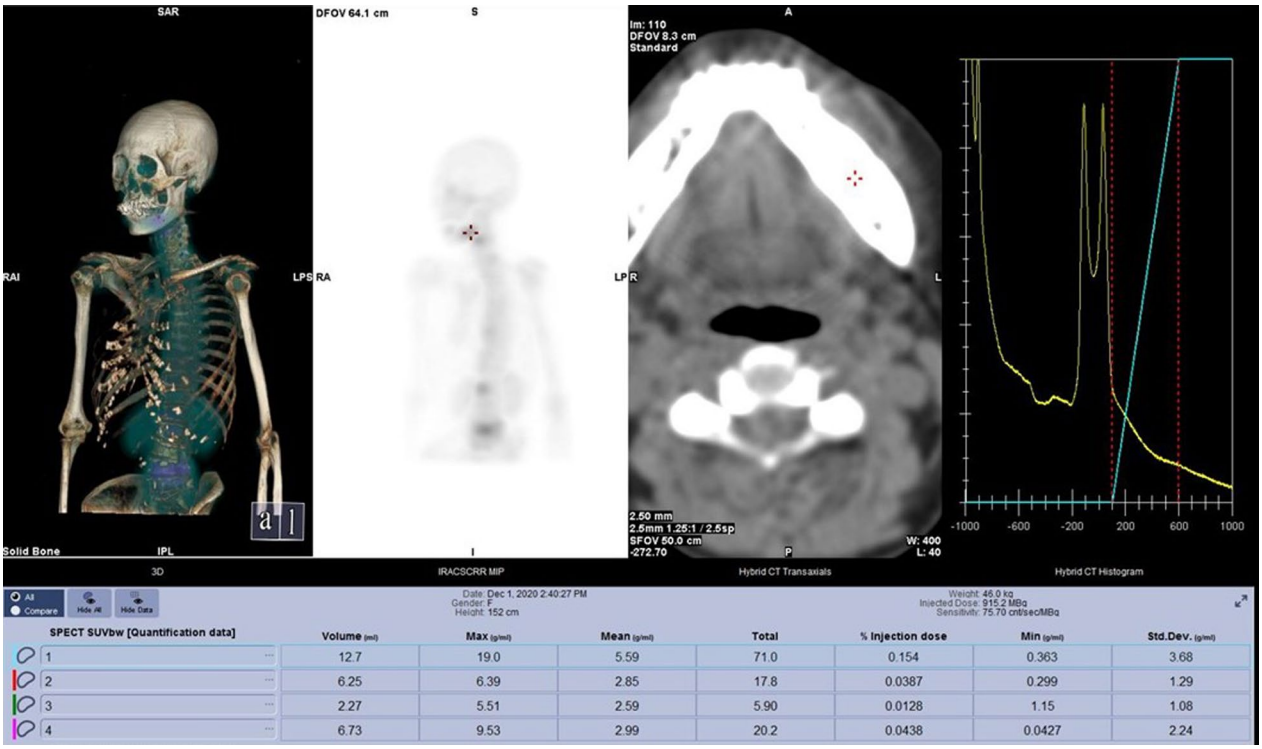

Fig. 2 Workstation and software (Xeleris 4DR and Q. Volumetrix MI) of medication-related osteonecrosis of the jaw (MRONJ) (Case 2). Maximum SUVs of the MRONJ (1, sky blue), right side of the MRONJ (2, red) and left side of the MRONJ (3, green) were 19.0, 6.39 and 5.51, respectively. Mean SUVs of the MRONJ (1, sky blue), right side of the MRONJ (2, red) and left side of the MRONJ (3, green) were 5.59, 2.85 and 2.59, respectively

Table 1 SPECT/CT standardized uptake values of five cases with medication-related osteonecrosis of the jaw (MRONJ)

Case	Age (years)	Gender	Underlying disease	Medication	Stage	Maximum standardized uptake value			Mean standardized uptake value		
						MRONJ	Right	Left	MRONJ	Right	Left
1	74	Female	Bone metastases from breast cancer	Denosumab	2	14.0	11.0	6.61	5.50	3.43	2.55
2	82	Female	Osteoporosis	Denosumab	2	19.0	6.39	5.51	5.59	2.85	2.59
3	83	Female	Osteoporosis	Minodronate	2	16.1	9.90	8.47	4.87	2.62	2.54
4	85	Female	Osteoporosis	Minodronate	3	28.6	8.00	6.14	4.62	2.39	2.39
5	88	Female	Osteoporosis	Minodronate	3	20.0	6.98	9.38	6.78	2.04	3.37
Mean ± SD						19.5 ± 5.6	8.5 ± 2.0	7.2 ± 1.6	5.5 ± 0.8	2.7 ± 0.5	2.7 ± 0.4
P value						–	.001	< .001	–	< .001	< .001

Limitations

We evaluated small sample size because of preliminary study. Furthermore, there is no mention regarding the quantitative decision making to help outline the surgical margins based on SUV evaluation. We consider that this result is preliminary study of surgical planning. Therefore, we consider that further research of the quantitative decision making to help outline the surgical margins based on SUV evaluation is necessary.

Conclusions

We evaluated the role of preoperative SPECT/CT SUVs in MRONJ, especially SPECT/CT in relation to CBCT and histopathological findings of the resected bone of mandibulectomy. The preliminary results indicated a difference between MRONJ and right and left sides of the MRONJ in SPECT/CT SUVs. The SUVs have enabled quantitative analysis for surgical planning of MRONJ.

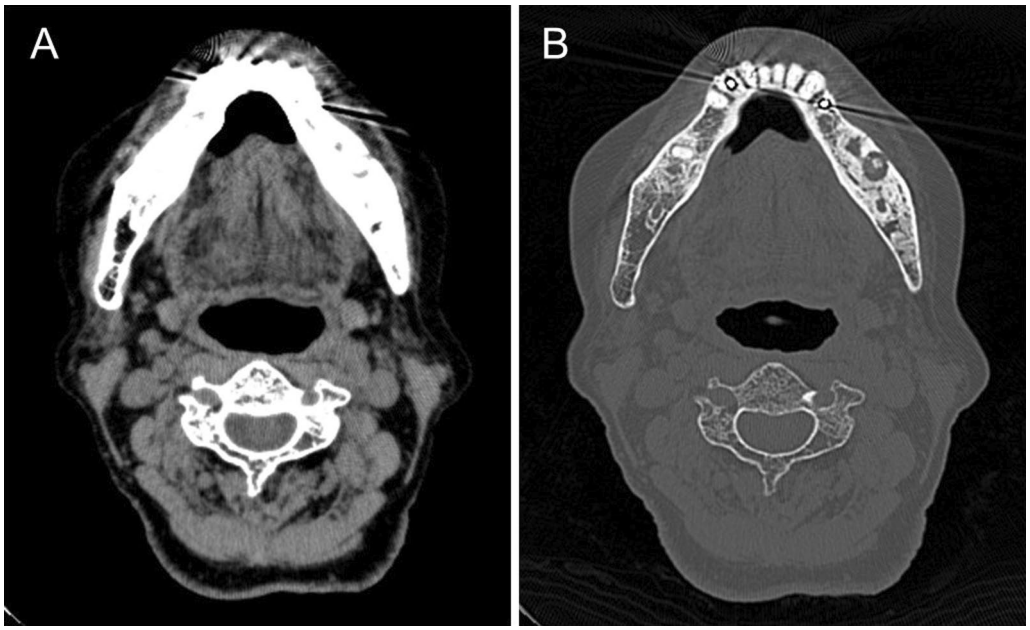

Fig. 3 Preoperative MDCT images of medication-related osteonecrosis of the jaw (MRONJ) (Case 2). The MDCT findings (**A** soft-tissue algorithm CT, **B** bone-algorithm CT) included osteolytic change of the jaw, sclerotic lesion, and sequestrum separation

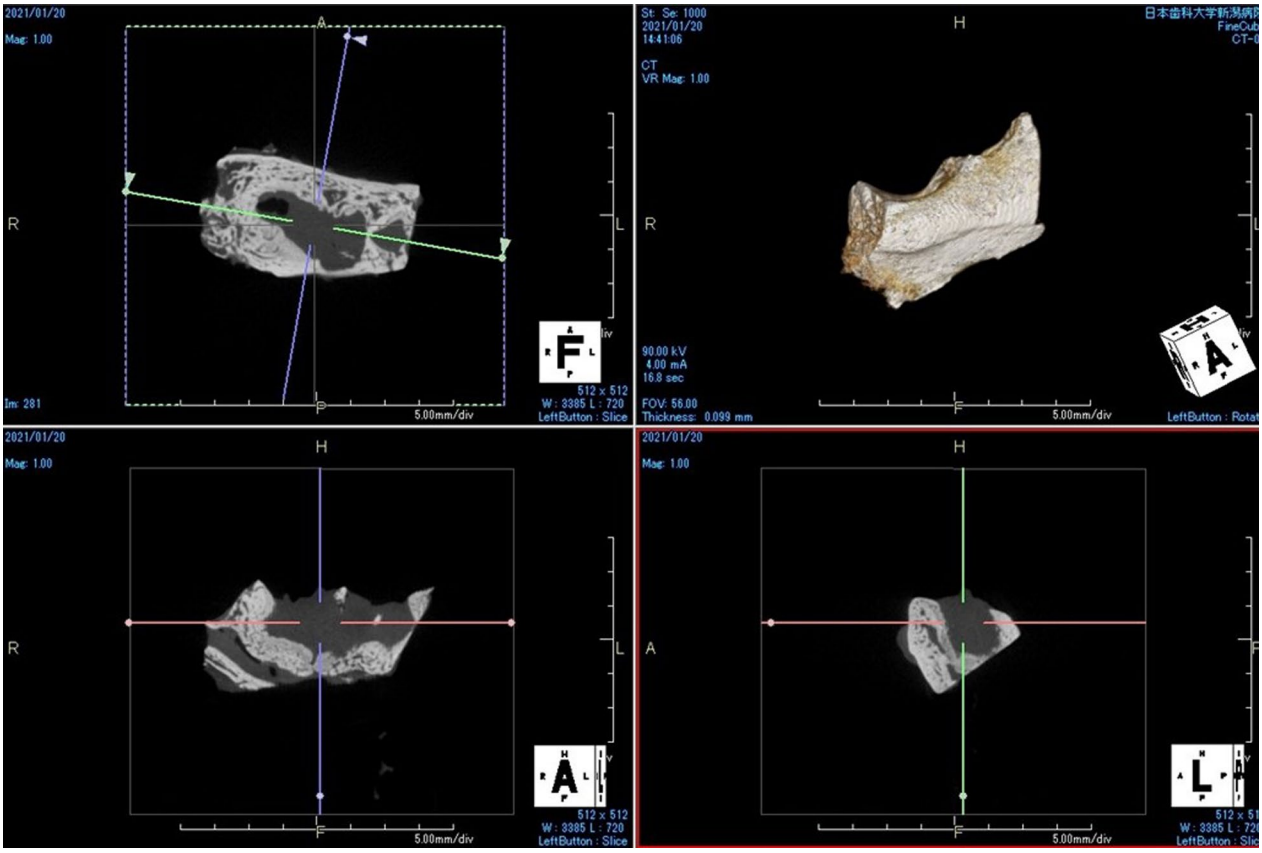

Fig. 4 CBCT images of a resected bone of medication-related osteonecrosis of the jaw (Case 2). The CBCT findings included osteolytic and sclerotic internal texture, and presence of sequestrum

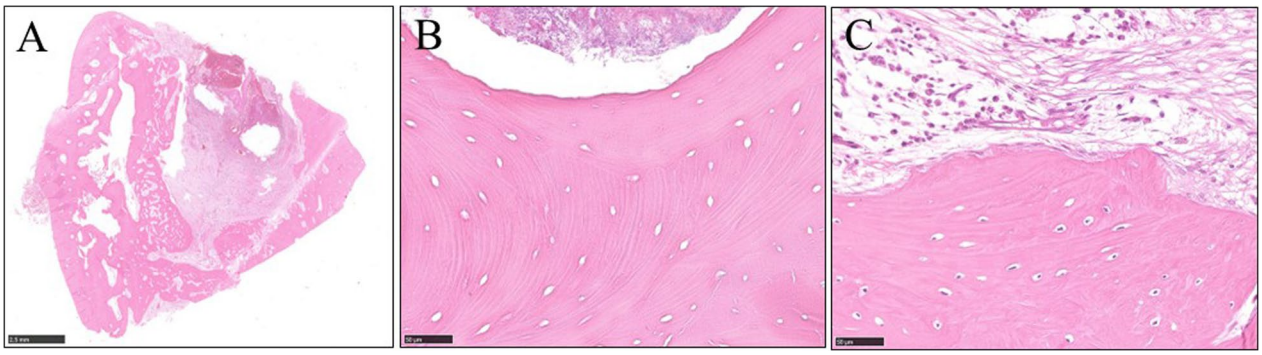

Fig. 5 Histopathological characteristics of a resected bone of medication-related osteonecrosis of the jaw (Case 2). **A** Histopathological finding of the low-power view specimen. This specimen indicates coronal images of CBCT (H-E, scale bar: 2.5 mm). **B** Histopathological findings of high-power view specimen. Empty osteocytic lacunae was observed. Osteoclast and resorption lacunae were not found on the surface of bone (H-E, scale bar: 50 μm). **C** Histopathological findings of the surgical margin. The mandible of the surgical margin was viable bone with chronic inflammatory cells (H-E, scale bar: 50 μm)

Abbreviations

CBCT	Cone-beam computed tomography
CT	Computed tomography
MDCT	Multidetector computed tomography
MRI	Magnetic resonance imaging
MRONJ	Medication-related osteonecrosis of the jaw
SPECT/CT	Single-photon emission computed tomography/computed tomography
SUV	Standardized uptake value
SUVmax	Maximum standardized uptake value
SUVmean	Mean standardized uptake value
^{99m}Tc-HMDP	Technetium-99 m hydroxymethylene diphosphonate
VOI	Volume of interest

Acknowledgements
Not applicable.

Author contributions
EK carried out the study design, provided the clinical information and wrote the paper. YT and IO carried out image reading, statistical analysis, in addition to editing of publications. JO and YO provided expert pathological advice. All authors read and approved the final manuscript.

Funding
No funding was obtained for this study.

Availability of data and materials
The datasets used and analyzed during the study are available from the corresponding author on reasonable request.

Declarations

Ethics approval and consent to participate
The study was approved by the Ethics Committee of The Nippon Dental University School of Life Dentistry at Niigata, Japan (approved no. ECNG-R-318) and conforms to the Declaration of Helsinki.

Consent for publication
Informed consent was obtained from all individual participants included in the study.

Competing interests
The authors declare that they have no competing interests.

Author details
[1]Oral and Maxillofacial Surgery, The Nippon Dental University Niigata Hospital, Niigata, Japan. [2]Department of Oral and Maxillofacial Radiology, The Nippon Dental University School of Life Dentistry at Niigata, 1-8 Hamaura-cho, Chuo-ku, Niigata, Niigata 951-8580, Japan. [3]Department of Pathology, The Nippon Dental University School of Life Dentistry at Niigata, Niigata, Japan.

Received: 2 May 2023 Accepted: 7 June 2023
Published online: 12 June 2023

References

1. Ruggiero SL, Dodson TB, Aghaloo T et al (2022) American Association of Oral and Maxillofacial Surgeons' position paper on medication-related osteonecrosis of the jaws-2022 update. J Oral Maxillofac Surg 80:920–943
2. Ogawa R, Minami Y, Ono J et al (2022) Medication-related osteonecrosis of the jaw in a patient with multiple myeloma: an unusual case with tumor in the surgical specimen. Oral Radiol 38:288–291
3. Ogura I, Sasaki Y, Kameta A et al (2017) Characteristic multimodal imaging of medication-related osteonecrosis of the jaw: comparison between oral and parenteral routes of medication administration. Pol J Radiol 82:551–560
4. Ogura I, Oda T, Sue M et al (2018) Comparison between squamous cell carcinoma and inflammatory diseases of the oral and maxillofacial region using gallium-67 scintigraphy with computed tomography and magnetic resonance imaging. Pol J Radiol 83:e452–e458
5. Ogura I, Sasaki Y, Sue M et al (2019) Tc-99m hydroxymethylene diphosphonate scintigraphy, computed tomography, and magnetic resonance imaging of osteonecrosis in the mandible: osteoradionecrosis versus medication-related osteonecrosis of the jaw. Imaging Sci Dent 49:53–58
6. Miyashita H, Shiba H, Kawana H et al (2015) Clinical utility of three-dimensional SPECT/CT imaging as a guide for the resection of medication-related osteonecrosis of the jaw. Int J Oral Maxillofac Surg 44:1106–1109
7. Miyashita H, Kameyama K, Morita M et al (2019) Three-dimensional radiologic-pathologic correlation of medication-related osteonecrosis of the jaw using 3D bone SPECT/CT imaging. Dentomaxillofac Radiol 48:20190208
8. Hata H, Kitao T, Sato J et al (2020) Monitoring indices of bone inflammatory activity of the jaw using SPECT bone scintigraphy: a study of ARONJ patients. Sci Rep 10:11385
9. Ogura I, Kobayashi E, Nakahara K et al (2019) Quantitative SPECT/CT imaging for medication-related osteonecrosis of the jaw: a preliminary study using volume-based parameters, comparison with chronic osteomyelitis. Ann Nucl Med 33:776–782
10. Ogura I, Sasaki Y, Sue M et al (2020) Tc-99m hydroxymethylene diphosphonate SPECT/CT for the evaluation of osteonecrosis of the jaw: preliminary study on diagnostic ability of maximum standardized uptake value. Clin Radiol 75:46–50

11. Toshima H, Ogura I (2020) Assessment of inflammatory jaw pathologies using bone SPECT/CT maximum standardized uptake value. Dentomaxillofac Radiol 49:20200043
12. Minami Y, Ogura I (2021) Bone single-photon emission computed tomography-CT peak standardized uptake value for chronic osteomyelitis, osteoradionecrosis and medication-related osteonecrosis of the jaw. J Med Imaging Radiat Oncol 65:160–165
13. Ogawa R, Ogura I (2021) Analysis of medication-related osteonecrosis of the jaw with bone SPECT/CT: relationship between patient characteristics and maximum standardized uptake value. Dentomaxillofac Radiol 50:20200516
14. Malina-Altzinger J, Klaeser B, Suter VGA et al (2019) Comparative evaluation of SPECT/CT and CBCT in patients with mandibular osteomyelitis and osteonecrosis. Clin Oral Investig 23:4213–4222
15. Ogura I, Minami Y, Ono J et al (2021) CBCT imaging and histopathological characteristics of osteoradionecrosis and medication-related osteonecrosis of the jaw. Imaging Sci Dent 51:73–80
16. Minami Y, Ogawa R, Ogura I (2022) Volumetric analysis of mandibular lesions with SPECT/CT: a pilot clinical study of maximum standardized uptake value. Pol J Radiol 87:e311–e315
17. Minami Y, Ogura I (2022) Comparison of maximum and mean standardized uptake values of jaw pathologies with bone SPECT/CT: an especial focus on medication-related osteonecrosis of the jaw. Nucl Med Commun 43:1188–1194

Publisher's Note