Yadav *et al. Egypt J Radiol Nucl Med* (2023) 54:110
https://doi.org/10.1186/s43055-023-01055-4

Egyptian Journal of Radiology and Nuclear Medicine

RESEARCH

Open Access

Diagnostic accuracy of shear wave elastography in evaluating renal fibrosis in children with chronic kidney disease: a comparative study with nuclear scan

Abhishek Kumar Yadav[1], Poonam Sherwani[1*], Enono Yhoshu[2], Vandana Kumar Dhingra[3] and Nowneet Kumar Bhat[4]

Abstract

Background Chronic kidney disease (CKD) is a significant health issue in pediatric patients due to fibrosis progression. Shear wave elastography (SWE) is a noninvasive technique used to assess fibrosis in CKD, but its efficacy needs to be better established. This study aimed to compare SWE with nuclear scan in assessing fibrosis in pediatric CKD patients.

Aim To determine the area of scarring/fibrosis of each kidney using shear wave elastography in chronic kidney disease and compare it with technetium-99m dimercaptosuccinic acid (DMSA) results.

Methods A prospective study included 39 chronic kidney disease patients who underwent shear wave elastography and grayscale ultrasound. DMSA scans were performed to identify scar areas of the kidneys. Young modulus was recorded for each pole of both kidneys and compared with scar areas on DMSA. Thirty-nine age-matched controls underwent shear wave elastography to estimate the average elasticity value in the normal population.

Results Thirty-nine CKD patients underwent this study, with 10 females and 29 males. The median age was 6.5 years. The cutoff value of cortical thickness ≤ 10.2 predicted scar on DMSA with a sensitivity of 79% and a specificity of 77%. The cutoff value of elasticity value ≥ 5.57 kPa predicted scar on DMSA with a sensitivity of 87% and a specificity of 96%. Median SWE values were significantly higher with the scar on DMSA (12.6 kPa) compared to no scar on DMSA (4.1 kPa). The controls mean values and standard deviation were 2.42 kPa and 0.45 kPa, respectively.

Conclusions Shear wave elastography has revealed that patients with chronic kidney disease exhibit higher values in the areas where scarring has occurred, compared to non-scarred areas. Fortunately, integrating shear wave elastography into routine ultrasonography assessments is a straightforward and painless process that requires no additional preparation from the patient. Not only is this method time efficient, but it also eliminates the need for potentially risky radiation exposure from radionuclide tests in the future.

Keywords Chronic kidney disease (CKD), DMSA (dimercapto succinic acid), Elasticity, Shear wave elastography, Youngs modulus

*Correspondence:
Poonam Sherwani
Sherwanipoonam@gmail.com
Full list of author information is available at the end of the article

Background

Chronic kidney disease (CKD) is a significant public health issue [1]. Evidence suggests that patients with advanced CKD have a higher risk of morbidity and mortality [2]. CKD has several serious health effects, including renal failure and an increased risk of cardiovascular disease. CKD is a disorder involving permanent kidney damage and the potential progression to end-stage renal disease (ESRD). Extensive epidemiological studies have focused on CKD in adults, but its frequency in the pediatric population remains poorly understood. Pediatric chronic kidney disease (CKD) presents with specific clinical features that particularly affect the growth and development of children [3]. Unfortunately, CKD is often clinically silent, especially during its initial stages, which leads to an underestimation of its true incidence and prevalence based on epidemiological data. However, despite its asymptomatic nature, CKD has a significant psychosocial impact on both the affected child and their family. The challenges associated with CKD, such as frequent medical visits, dietary restrictions, and the potential need for dialysis or transplantation, can disrupt normal daily life and create emotional stress for the child and their loved ones. Notably, the frequency of CKD has experienced a remarkable increase, which can be attributed to the significant advancements in CKD treatment and improved survival rates [4]. These advancements have provided better management options and increased life expectancy for children with CKD, but they have also contributed to the growing prevalence of the disease, further emphasizing the need for comprehensive support and care for pediatric CKD patients and their families.

Ultrasonography (USG), computed tomography (CT), magnetic resonance imaging (MRI), and renal biopsy are commonly used imaging modalities to detect and evaluate renal disorders. Each modality has its advantages and disadvantages. Ultrasonography (USG) is the most widely used modality to detect chronic kidney disease (CKD) in pediatric patients. USG is noninvasive, readily available, and does not involve radiation exposure, making it particularly suitable for use in children. It can provide valuable information about renal size, echogenicity, and the presence of structural abnormalities. However, it is important to note that USG may not be able to provide quantitative measurements and a detailed evaluation of certain renal conditions [5]. In such cases, additional imaging modalities or procedures, such as CT scans or renal biopsy, may be necessary for a more comprehensive assessment, along with an estimated glomerular filtration rate (eGFR), which is an indirect measure influenced by various factors like muscle mass, protein intake, and muscle damage [6]. Nonetheless, USG remains an essential tool in the initial evaluation and monitoring of pediatric CKD patients.

Doppler ultrasound may help identify CKD and its progression to ESRD. CEUS (contrast-enhanced ultrasonography) is a technique with no known nephrotoxicity. There is mounting evidence that CEUS has a role in renal lesion characterization [7], assessment of renal perfusion, and evaluation of renal transplant complications.

Sonoelastography, specifically shear wave elastography (SWE), has gained popularity for assessing soft tissue elasticity alongside traditional ultrasound techniques. SWE is objective, quantifiable, and repeatable, making it useful in detecting kidney fibrosis and scarring. By measuring tissue stiffness, SWE provides valuable information about the elastic properties of the kidney. Young's modulus (YM) is a measure of tissue elasticity, with higher values indicating more fibrosis [8]. SWE, already FDA-approved for liver assessment to distinguish between normal and cirrhotic livers [9], can potentially be used in CKD patients to evaluate disease severity and monitor treatment. Our study aimed to utilize SWE to identify CKD kidney scarring/fibrosis areas and compare the results with DMSA imaging.

Methods

Patients

This prospective institution-based study was conducted over 18 months on 39 patients with chronic kidney disease from any cause who came for pre-therapeutic assessment or follow-up during their management course. All patients underwent conventional grayscale ultrasonography and shear wave elastography, followed by a DMSA scan. Child assent (the parent or legal guardian) form was taken from all patients to use their results data.

Inclusion criteria for cases

All the children (0–18 years) diagnosed with CKD had a minimum renal cortical thickness of ~ 0.5 cm or more on ultrasound (the 0.5 cm threshold was chosen because ROI (region of interest) for taking elasticity values would not accommodate any thickness smaller than 0.5 cm).

Exclusion criteria for cases

We excluded the patients with any condition impeding visualization of the kidney by Ultrasonography. Children who could not hold their breath/follow the examiner's command.

Inclusion criteria for controls

Random controls were taken (0–18 years) for children with normal renal function tests. Children who came for ultrasonography for diseases other than renal cause.

Technique

The scans were done using an Esaote, my laboratory e XP USG machine by an experienced radiologist with 12 years of experience in ultrasonography and 5 years of experience in elastography.

Conventional grayscale ultrasonography evaluation

Both kidneys were subjected to a routine ultrasonography examination in the supine position using a curvilinear probe (the Esaote C1-8 Curved Array Transducer with a frequency range of 1.0–8.0 MHz). Kidney evaluation through ultrasound includes measuring the bipolar length and cortical thickness, as well as visually examining renal echogenicity compared to the liver and spleen. Normal kidneys have similar or lower echogenicity compared to the surrounding organs. Renal cortical thickness was measured between the kidney's outer border and the corticomedullary junction.

SWE evaluation

The same operator with 12 years of experience in ultrasonography and 5 years of experience in elastography performed the shear wave elastography examination using the same ultrasound instrument in the supine position with a curved array transducer with a frequency range of 1.0–8.0 MHz. Patients were scanned regardless of their bladder status. The transducer was positioned parallel to the renal axis view, and patients were told to hold their breath. The renal cortical thickness and Young's modulus were recorded at both cases' and controls' upper, lower, and interpolar regions. A small ROI box was established in the outer renal cortex, excluding the renal medulla and sinus, to quantify the SWE estimates of renal Young's modulus (YM in kPa). Two reads were taken at each pole, and then the mean and standard deviation of YM measurements were recorded.

DMSA scan

Cases underwent DMSA scans on a dual-headed gamma camera with 16-slice SPECT/CT (Discovery NM-CT), and they were administered 99 mTc-DMSA intravenously (1.85 MBq/kg (0.05 mCi/kg)) after 3 h, and static planar pictures of their kidneys in anterior and posterior projections were produced. Renal counts were gathered using a gamma camera. The numbers from each kidney were corrected for perirenal background values, tissue absorption, and radioactive decay. Renal uptake of 99 mTc-DMSA was calculated as a percentage of fixed net injected activity in each kidney, revealing the kidneys' relative function as a percentage. Dominant kidneys had the greatest rates of 99 mTc-DMSA uptake. The total of both sides' renal function was 100 percent. The scans were interpreted by an experienced nuclear medicine radiologist with 15 years of experience. Shear wave elastography was conducted on the same day as the DMSA scan.

Statistical analysis

Microsoft Excel and IBM Statistical Package for Social Sciences (SPSS) Statistics version 26 software were used for statistical analysis, and *p*-values less than 0.05 were considered to indicate statistically significant differences. Nonparametric tests (Spearman correlation) were used to explore the correlation between the two variables. Cut-off values were estimated using ROC (receiver operator characteristic) curve analysis, where the differences were statistically significant.

Results

There were 39 patients assessed using serum creatinine, eGFR, conventional ultrasonography, shear wave elastography, and 99 mTc-DMSA renal scintigraphy. Basic patient demographics and clinical data are illustrated in Table 1. The diagnosis of patients is summarized in Fig. 1.

Table 1 Summary of basic patient demographics and clinical data

Basic details	Mean ± SD	Median (IQR)	Min–Max	Frequency (%)
Age (years)	6.17 ± 4.32	5.00 (3.30–8.00)	0.25-17.00	
Age group				
0–5 years				21 (53.8%)
6–10 years				12 (30.8%)
11–18 years				6 (15.4%)
Gender				
Male			29 (74.4%)	
Female			10 (25.6%)	
Serum creatinine (mg/dL)	1.67 ± 1.29	1.36 (0.79–2.06)	0.26–6.20	
eGFR (mL/min/m^2)	102.41 ± 58.13	86.00 (58.50–152.00)	11.00–214.00	

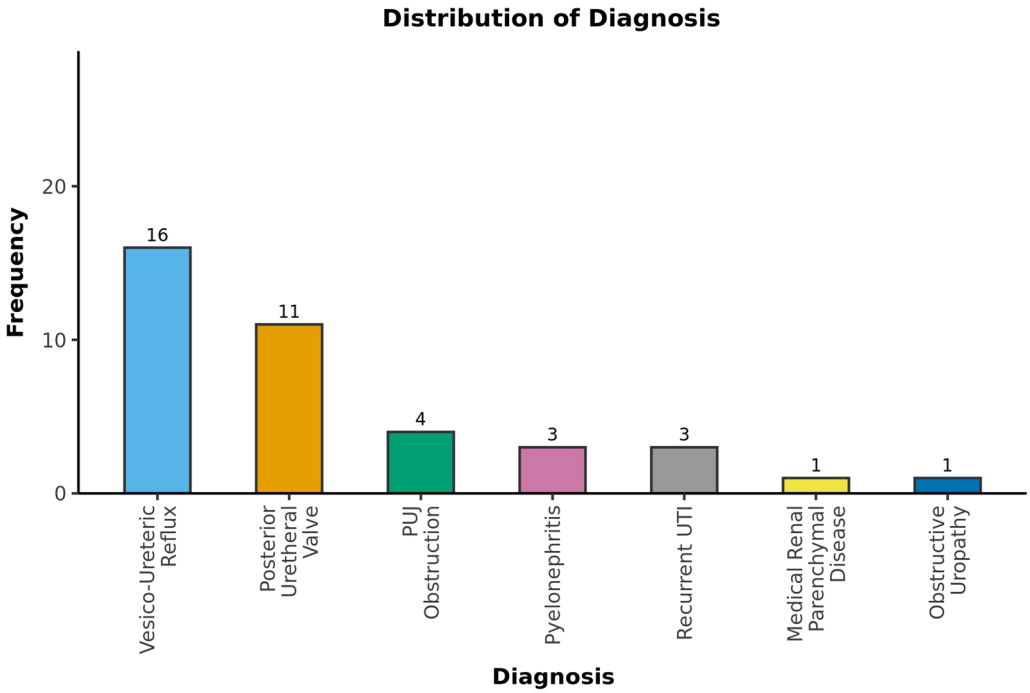

Fig. 1 Bar graph showing the frequency of diagnosis in patients who underwent the study

Table 2 Values of the parameters in case population

All parameters	Mean ± SD	Median (IQR)	Min–Max	Frequency {%}
Cortical thickness	10.61 ± 1.97	10.65 (9.20–11.90)	5.50–15.60	
Reduced cortical thickness (Yes)				79 (35.6%)
Elasticity value	7.51 ± 6.39	4.80 (3.59–10.49)	1.20–48.78	
Scar on DMSA (Yes)				85 (38.3%)

For the evaluation of all the poles in all the patients, we considered each pole as an individual, i.e., n = 222 (4 patients had a single kidney, so it came out to 222 poles). The mean cortical thickness was 10.61 ± 1.97. 35.6% (79) of the participants had reduced cortical thickness. The mean elasticity value was 7.51 ± 6.39. 38.3% (85) of the participants had scars on their DMSA, and 61.7% (137) of the participants had no scars on their DMSA. All these parameters are summarized in Table 2.

The variables shown in Table 3 (i.e., reduced cortical thickness and scar on DMSA) were significantly associated ($p < 0.05$) with the variable elasticity value.

Table 3 Association between elasticity value and parameters (reduced cortical thickness and scar on DMSA)

Parameters	Elasticity value	*p* value
*Reduced cortical thickness****		
Yes	12.83 ± 7.53	< 0.001[a]
No	4.57 ± 2.83	
*Scar on DMSA****		
Yes	12.96 ± 7.17	< 0.001[a]
No	4.12 ± 2.12	

***Significant at $p < 0.05$, [a]Wilcoxon–Mann–Whitney U test

Association between scar on DMSA and elasticity values

Table 4 summarizes the elasticity values at the upper pole, interpolar region, and lower pole of both kidneys. The elasticity value in the group with scars on DMSA ranged from 3.59 to 48.78. The elasticity value in the group without scar on DMSA ranged from 1.2 to 17.3. Table 5 summarizes the scar at different regions of the kidney on DMSA.

Table 4 Summary of elasticity value

Elasticity value	Mean ± SD	Median (IQR)	Min–max
Right upper pole	7.32 ± 5.58	4.95 (4.30–9.52)	1.2–28.2
Right interpolar	6.81 ± 8.06	4.20 (3.32–6.38)	1.2–48.8
Right lower pole	6.12 ± 4.53	4.60 (3.28–6.84)	2.1–20.8
Left upper pole	9.18 ± 7.91	5.20 (4.25–13.22)	1.3–36.8
Left interpolar	7.95 ± 5.86	5.11 (3.58–13.42)	1.9–22.8
Left lower pole	7.79 ± 5.66	4.80 (3.63–11.05	2.1–21.7

Table 5 Summary of scar on DMSA

Scar on DMSA	Yes	No
Right upper pole	15 (39.5%)	23 (60.5%)
Right interpolar	8 (21.1%)	30 (78.9%)
Right lower pole	10 (26.3%)	28 (73.7%)
Left upper pole	19 (52.8%)	17 (47.2%)
Left interpolar	16 (44.4%)	20 (55.6%)
Left lower pole	17 (47.2%)	19 (52.8%)

There was a significant difference between the two groups in terms of elasticity value ($p = < 0.001$), with the median elasticity value being highest in the scar on DMSA. The box-and-whisker plot for the distribution of elasticity value in the 2 groups, i.e., the group with the scar and the group without the scar. The middle horizontal line represents the median elasticity value; the upper and lower bounds of the box represent the 75th and 25th centiles of elasticity value, respectively, and the upper and lower extents of the whiskers represent the Tukey limits for elasticity value in each of the groups. The median (IQR) elasticity value in the group with the scar on DMSA was 12.6 (8.8–15.2). The median (IQR) elasticity value in the group without scar on DMSA was 4.1 (3.1–4.8) (Fig. 2).

Correlation between cortical thickness and elasticity value (n = 222)

Nonparametric tests (Spearman correlation) were used to explore the correlation between the two variables, as at least one of the variables was not normally distributed. The scatterplot depicted in Fig. 3 showed the correlation between cortical thickness and elasticity value, and there was a moderately negative correlation between cortical thickness and elasticity value, and this correlation was statistically significant (rho = − 0.4, $p = < 0.001$).

Diagnostic performance of SWE

The ROC curve was used to evaluate the diagnostic performance of SWE imaging, cortical thickness, and elasticity parameters in diagnosing scars on DMSA. When the sum of sensitivity and specificity is maximized, the best cutoff value of cortical thickness ≤ 10.2 mm predicts scar on DMSA with a sensitivity of 79% and a specificity of 77% (Fig. 4). Similarly, in ROC curve analysis for the diagnostic performance of elasticity value in predicting scar on DMSA (n = 222), a cutoff of elasticity value ≥ 5.57 kPa indicates scar on DMSA with an 87% sensitivity and a 96% specificity (Fig. 5). In predicting

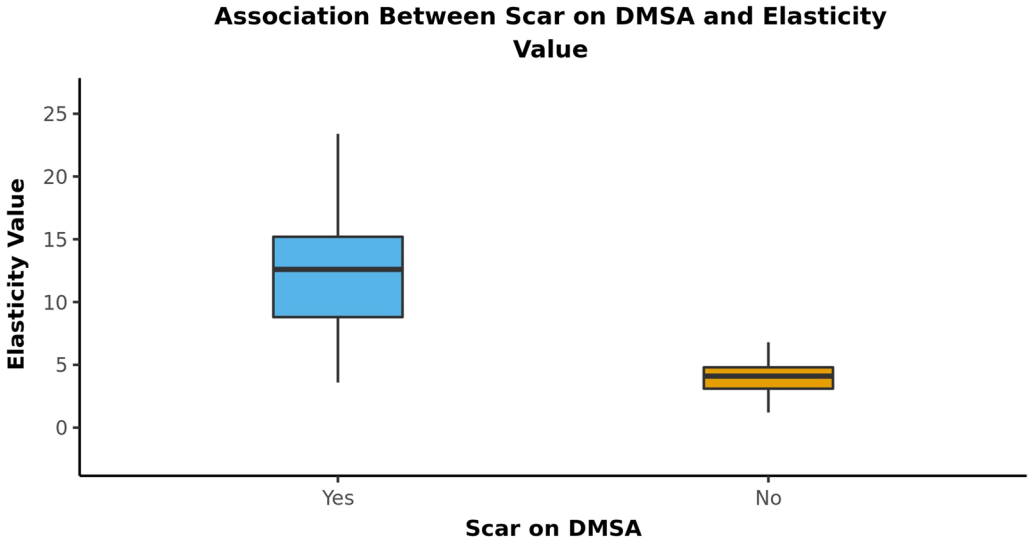

Fig. 2 The box-and-whisker plot above depicts the distribution of elasticity value in the 2 groups. The middle horizontal line represents the median Elasticity Value, the upper and lower bounds of the box represent the 75th and the 25th centile of Elasticity Value, respectively, and the upper and lower extent of the whiskers represent the Tukey limits for Elasticity Value in each of the groups

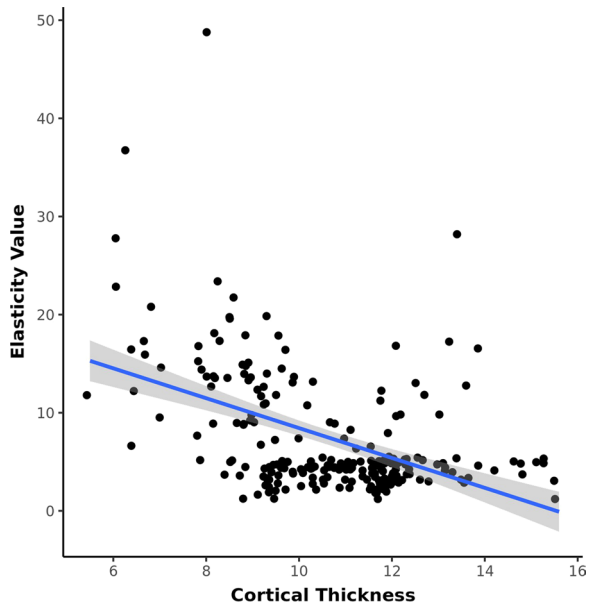

Fig. 3 The scatterplot showed the correlation between Cortical Thickness and Elasticity Value. Individual points represent individual cases. The blue trendline represents the general trend of correlation between the two variables. The shaded gray area represents the 95% confidence interval of this trendline

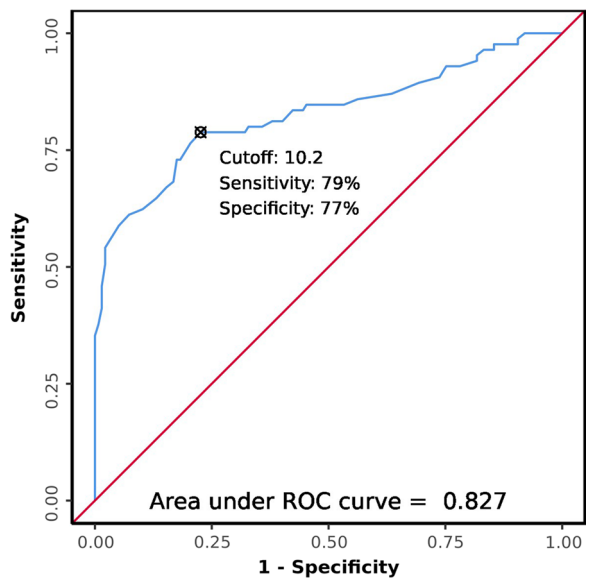

Fig. 4 ROC curve analysis for cortical thickness in predicting scar on DMSA

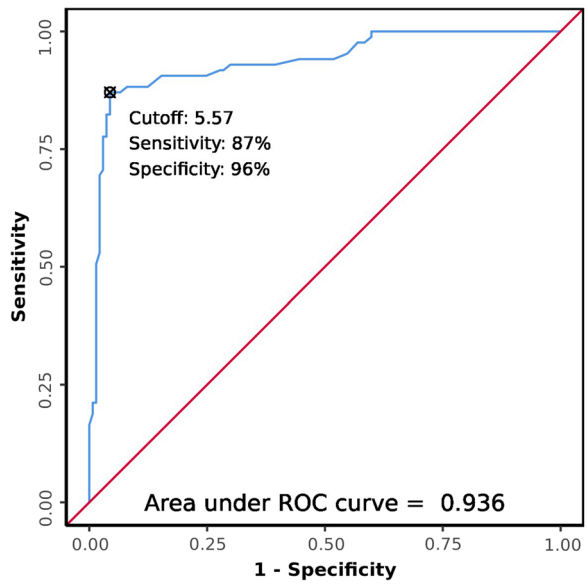

Fig. 5 ROC curve analysis for elasticity value in predicting scar on DMSA

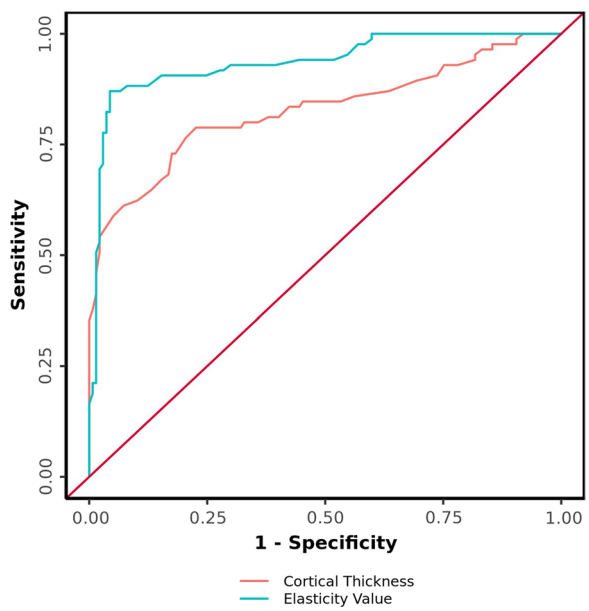

Fig. 6 Comparison of the diagnostic performance of various predictors in predicting scar on DMSA: Yes versus scar on DMSA: No (full sample) by ROC curve

the scar on DMSA, the area under the ROC curve for elasticity measurements, i.e., SWE imaging, outperforms cortical thickness (Fig. 6). The better parameter in terms of diagnostic accuracy is the elasticity value, as shown in Table 6.

Table 6 Comparison of the diagnostic performance of various predictors in predicting Scar on DMSA: Yes versus scar on DMSA: No (full sample)

Predictor	AUROC	95% CI
Cortical thickness	0.827	0.765–0.888
Elasticity value	0.936	0.901–0.972

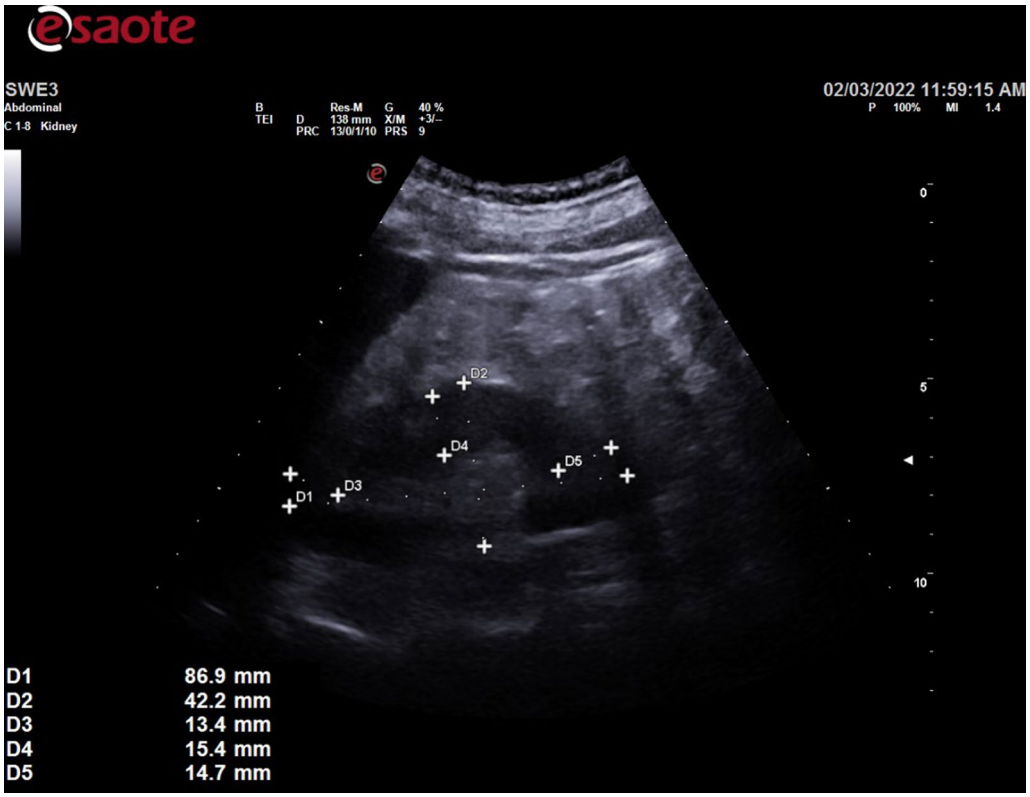

Fig. 7 Grayscale ultrasound shows kidney size, cortical thickness, and the absence of hydronephrosis

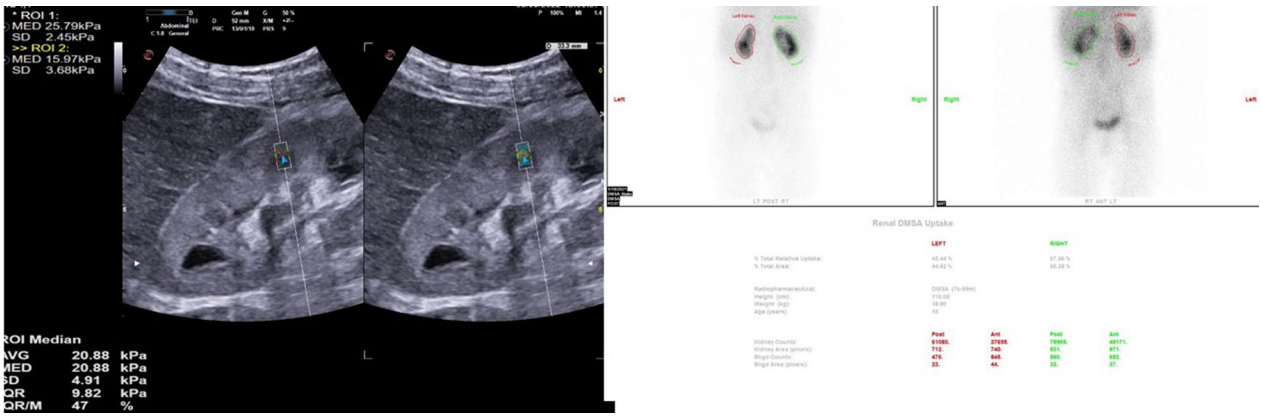

Fig. 8 A 10-year-old male case of vesico-uretric reflux disease showing shear wave elastography images depicting increased young modulus values(Average Elasticity values of 20.88 kPa) at the right interpolar poles after applying the ROI circle corresponding DMSA images depicts reduced cortical tracer uptake at the interpolar regions of the right kidney

Figure 7 shows how kidney length and cortical thickness were measured in the longitudinal section of the kidney. Figures 8 and 9 show two pediatric chronic kidney disease patients that illustrate increased elasticity values with corresponding photopenic areas in both pat ients.

Mean elasticity value in controls

For all 39 controls, the mean elasticity values came to 2.42 kPa, and the standard deviation was 0.45 kPa (Fig. 10). So, elasticity values above 2.4 ± 0.45 kPa can be considered abnormal, and shear wave elastography can predict a scar in the kidney at an elasticity value ≥ 5.57 kPa.

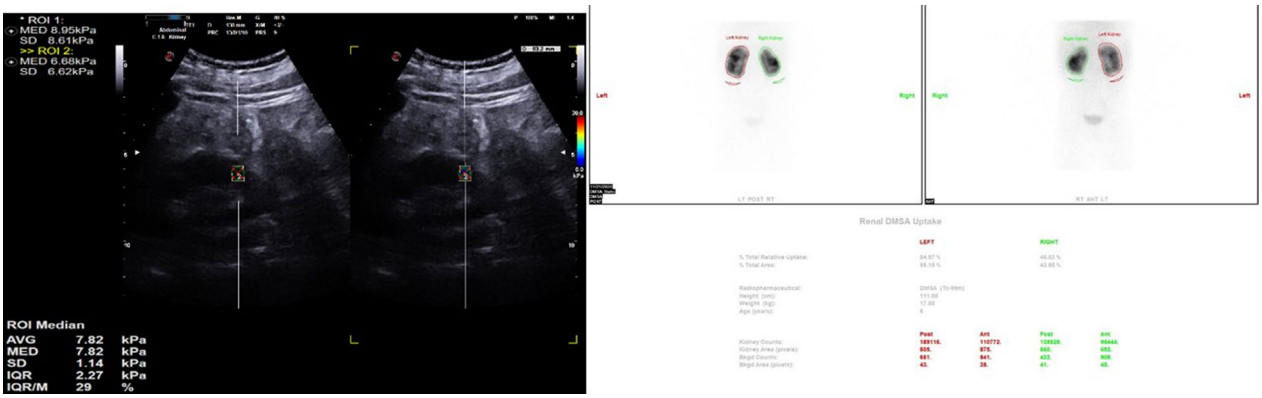

Fig. 9 A 6-year-old male with recurrent urinary tract infection with reflux shows shear wave ultrasonography with increased young modulus values(Average Elasticity values of 7.82 kPa) at the left lower poles after applying the ROI circle. And the corresponding DMSA images depicting focal areas of reduced tracer uptake are seen in the left kidney's upper pole and lower pole

Fig. 10 Bar chart showing mean and standard deviation of young modulus values in both the kidneys in all the controls

Discussion

Chronic kidney disease (CKD) is a common medical condition in children that can lead to renal fibrosis and scarring, resulting in the loss of kidney function. Early diagnosis and monitoring of renal fibrosis are crucial in improving the management and outcome of children with CKD [10]. Various imaging modalities have been used for the detection and evaluation of renal fibrosis, including conventional ultrasound, nuclear scintigraphy, and shear wave elastography (SWE). In this study, we compared the diagnostic accuracy of SWE with nuclear scintigraphy in evaluating renal fibrosis in children with CKD.

This study aimed to provide a more reliable and straightforward way to assess the scarred area of the kidneys and to give a means for determining scarred areas other than a DMSA scan, especially in locations where nuclear medicine resources are few. SWE imaging is a noninvasive approach to evaluating the mechanical stiffness of tissue. Shear wave elastography has been used in the liver and has shown that hepatic inflammation increases tissue stiffness estimates in patients with liver disease. It is now well established that elastography can stage liver fibrosis. SWE is commonly utilized in clinical settings to distinguish between early and severe liver fibrosis without requiring a biopsy [11].

CKD would cause tissue stiffness to change in a way SWE could detect. We believed this was biologically plausible since fibrosis and inflammation of the renal parenchyma are known to occur in CKD, and fibrosis has been demonstrated to alter tissue SWE estimations of tissue stiffness in other organs.

In a trial focused on Chinese people, the study included patients at different stages of the disease, assessed the correlation between shear wave elastography measurements and kidney function, and did not include healthy patients as a control group [12]. Sensitivity and specificity for assessing tissue stiffness were 84% and 80%, respectively. On the other hand, in our study, we included controls and CKD patients at any stage of the disease. So

we were also able to know the values that represent the normal population. However, our results were consistent with the fact that CKD leads to an increase in tissue stiffness, resulting in higher elasticity values.

Several studies have investigated the use of SWE in assessing renal fibrosis in adults with CKD. A study by Yoon et al. found that SWE could accurately predict the severity of renal fibrosis in adults with CKD [13]. Similarly, a study by Chen et al. found that SWE had a high diagnostic accuracy in predicting renal fibrosis in adults with CKD [14].

In pediatric patients, there have been fewer studies investigating the use of SWE in assessing renal fibrosis. A study by Huang et al. [15] compared the diagnostic performance of SWE with renal biopsy in 78 adults with CKD and found that SWE had a sensitivity of 85.7% and a specificity of 88.5% in detecting moderate to severe fibrosis. These findings are consistent with our study, as the diagnostic performance of elasticity value in predicting scar on DMSA is 87% sensitivity and 96% specificity, which found that SWE had good diagnostic performance in detecting renal scars in children with CKD. In another study by Turgutalp et al. with 30 participants, the sensitivity and specificity of SWE to diagnose the presence of interstitial fibrosis for YM > 15 kPa were 89% and 90%, respectively [16]. On the other side, in our study, a cutoff of 5.57 kPa was determined for the area of scarring, which is much lower than the peer study by Turgutalp.

One study by Zhang et al. [17] investigated the use of SWE in detecting renal fibrosis in 150 adults with IgA nephropathy and found that SWE had a sensitivity of 94.1% and a specificity of 88.5% in detecting fibrosis. This study reported higher sensitivity and lower specificity than our study. There were differences in patient populations or differences in the criteria used to define renal fibrosis, which was by renal tissue biopsy.

Another study by Wu et al. [18] investigated the use of SWE in detecting renal fibrosis in 71 adults with CKD and found that SWE had a sensitivity of 75.8% and a specificity of 92.3% in detecting fibrosis. This study reported lower sensitivity and higher specificity than our study, which may be due to differences in patient populations or differences in the SWE measurement techniques used.

We found an increase in young modulus values in scarred kidneys, which were in line with those of Goya et al. [19], who found increased SWVs in scarred kidneys. In addition, we discovered that the area under the ROC curve for identifying scarred regions in kidneys using SWE imaging was better than standard ultrasound parameters in our investigation.

In a study by Grosu et al. [20], in their study "chronic kidney disease patients, there were 22 healthy controls, and it was found that the mean SWV of the normal right kidney was 1.23 ± 0.33 m/s; and the normal left kidney was 1.26 ± 0.32 m/s."

The average elasticity values and standard deviation from 39 controls taken in our study came out to be 2.42 ± 0.45 kPa (Fig. 10). In our study, at a cutoff elasticity value ≥ 5.57 kPa, shear wave elastography predicted scar on DMSA with a sensitivity of 87% and a specificity of 96%. Yang et al. [21] conducted a study that included 120 patients with idiopathic nephrotic syndrome and concluded that SWE technology is a potential method for noninvasive quantitative measurement of renal parenchyma stiffness to determine the pathological changes of INS renal parenchyma and evaluate the effectiveness of steroid therapy.

However, there are limitations to the study, including the small sample size and the use of a single-center design. As ultrasonography was performed by one radiologist, we could not analyze interobserver variability, which may limit the generalizability of the findings.

Conclusions

Shear wave elastography has shown better results than conventional ultrasound for assessing chronic kidney disease. It is a noninvasive technique that could identify areas of scarring with higher sensitivity and specificity and could become an alternative for radionuclide study; i.e., 99TC-dimercaptosuccinic acid has an inherent radiation risk that is of serious concern in the pediatric age group and is also a cheaper modality, especially in children who are on regular follow-up with 99TC-dimercaptosuccinic acid, and could be particularly useful in monitoring disease progression and guiding treatment decisions. Further research is needed to confirm the utility of SWE in clinical practice, including the development of standardized protocols for its use in the assessment of pediatric CKD patients.

Abbreviations

CKD	Chronic kidney disease
SWE	Shear wave elastography
DSMA	Dimercapto succinic acid
KPa	Kilo pascal
ESRD	End-stage renal disease
CT	Computed tomography
USG	Ultrasonography
e GFR	Estimated glomerular filtration rate
CEUS	Contrast-enhanced ultrasonography
YM	Young's modulus
FDA	Food and Drug Administration
ROI	Region of interest
ROC	Receiver operator curve
IQR	Interquartile range
SWV	Shear wave velocity

Acknowledgements

To Pediatric and Pediatric Surgery Department

Author contributions
AY collected the data, literature review, and drafted the article. PS did the basic designing and the critical revision of the article. All authors read and approved the final manuscript. All authors agreed with the content, and all gave explicit consent to submit. EY, VKG, and NKB provided the clinical inputs and VKG analyzed the nuclear scan.

Funding
No funding was obtained for this study.

Availability of data and materials
The datasets used and/or analyzed during the current study are available from the corresponding author on reasonable request.

Declarations

Ethics approval and consent to participate
The Institute Ethics Committee received an application for full ethical approval, and on July 16, 2021, ethics consent was granted with the approval number AIIMSRPR/ IEC/21/419. The study procedures followed the ethical standards set by the institutional ethics committee. Before participation, written informed consent was obtained from all individuals who volunteered for the study.

Consent for publication
The authors affirm that human research participants provided written informed consent for publication of the images in the figures.

Competing interests
The authors have no relevant financial or non-financial interests to disclose.

Author details
[1]Department of Radiodiagnosis, All India Institute of Medical Sciences (AIIMS), Rishikesh, Uttarakhand 249203, India. [2]Department of Pediatric Surgery, All India Institute of Medical Sciences (AIIMS), Rishikesh, Uttarakhand 249203, India. [3]Department of Nuclear Medicine, All India Institute of Medical Sciences (AIIMS), Rishikesh, Uttarakhand 249203, India. [4]Department of Pediatrics, All India Institute of Medical Sciences (AIIMS), Rishikesh, Uttarakhand 249203, India.

Received: 28 March 2023 Accepted: 12 June 2023
Published online: 20 June 2023

References

1. Lysaght MJ (2002) Maintenance dialysis population dynamics: current trends and long-term implications. J Am Soc Nephrol 13(suppl 1):S37–S40
2. United States Renal Data System. (2013). Atlas of chronic kidney disease & end-stage renal disease in the United States. Saunders.
3. Schaefer B, Wühl E (2012) Educational paper: progression in chronic kidney disease and prevention strategies. Eur J Pediatr 171:1579–1588
4. Moore, J. E. C. (2020). Measuring knowledge of chronic kidney disease (CKD) among community college students (Doctoral dissertation, Walden University).
5. Schieppati A, Remuzzi G (2005) Chronic renal diseases as a public health problem: epidemiology, social, and economic implications. Kidney Int 68:S7–S10
6. Brück K, Stel VS, Fraser S, De Goeij MC, Caskey F, Abu-Hanna A, Jager KJ (2015) Translational research in nephrology: chronic kidney disease prevention and public health. Clin Kidney J 8(6):647–655
7. He L, Li Z, Zhang Q, Chen Y, Gao Y, Chen T, Fan Y (2022) Evaluation of renal microperfusion in hyperuricemic nephropathy by contrast-enhanced ultrasound imaging. Dis Models Mech 15(7):dmm049382
8. Harambat J, van Stralen KJ, Kim JJ, Tizard EJ (2012) Epidemiology of chronic kidney disease in children. Pediatr Nephrol 27:363–373
9. Vivante A, Hildebrandt F (2016) Exploring the genetic basis of early-onset chronic kidney disease. Nat Rev Nephrol 12(3):133–146
10. Hodgkins KS, Schnaper HW (2012) Tubulointerstitial injury and the progression of chronic kidney disease. Pediatr Nephrol 27:901–909
11. Leong SS, Wong JHD, Md Shah MN, Vijayananthan A, Jalalonmuhali M, Ng KH (2018) Shear wave elastography in the evaluation of renal parenchymal stiffness in patients with chronic kidney disease. Br J Radiol 91(1089):20180235
12. Mo XL, Meng HY, Wu YY, Wei XY, Li ZK, Yang SQ (2022) Shear wave elastography in the evaluation of renal parenchymal stiffness in patients with chronic kidney disease: a meta-analysis. Jof Clin Med Res 14(2):95
13. Shin HJ, Yoon H, Kim MJ, Han SJ, Koh H, Kim S, Lee MJ (2018) Liver intravoxel incoherent motion diffusion-weighted imaging for the assessment of hepatic steatosis and fibrosis in children. World J Gastroenterol 24(27):3013
14. Chen Z, Chen J, Chen H, Su Z (2023) A nomogram based on shear wave elastography for assessment of renal fibrosis in patients with chronic kidney disease. J Nephrol 36(3):719–729
15. Huang JL, Song YJ, Zhang JW, Cao XJ, Chen W, Wang XH (2015) Noninvasive assessment of renal fibrosis with real-time tissue elastography in renal transplant recipients: a single-center experience. J Ultrasound Med 34(5):761–769
16. Turgutalp K, Balcı Y, Özer C, Bardak S, Gürses İ, Karabulut Y, Kıykım A (2020) Shear wave elastography findings in Immunoglobulin a nephropathy patients: Is it more specific and sensitive for interstitial fibrosis or interstitial fibrosis/tubular atrophy? Renal Fail 42(1):590–599
17. Zhang X, Liu X, Liu H, Chen H, Zhang L, Wang Y (2015) Real-time tissue elastography in the diagnosis of renal fibrosis in patients with IgA nephropathy. J Ultrasound Med 34(2):233–241
18. Wu T, Li L, Lu J, Wang L, Zhang H, Cao Y, Chen X (2017) Use of real-time shear wave elastography to differentiate stage 1–2 from stage 3–5 chronic kidney disease in chronic renal patients: a pilot study. Eur Radiol 27(4):1494–1501
19. Göya C, Hamidi C, Ece A, Okur MH, Taşdemir B, Çetinçakmak MG, Şahin C (2015) Acoustic radiation force impulse (ARFI) elastography for detection of renal damage in children. Pediatric Radiol 45:55–61
20. Grosu I, Bob F, Sporea I, Popescu A, Şirli R, Schiller A (2018) Correlation of point shear wave velocity and kidney function in chronic kidney disease. J Ultrasound Med 37(11):2613–2620
21. Yang X, Hou FL, Zhao C, Jiang CY, Li XM, Yu N (2020) The role of real-time shear wave elastography in the diagnosis of idiopathic nephrotic syndrome and evaluation of the curative effect. Abdom Radiol 45:2508–2517

Publisher's Note