Ahmed *et al. Egypt J Radiol Nucl Med* (2023) 54:112
https://doi.org/10.1186/s43055-023-01057-2

Egyptian Journal of Radiology and Nuclear Medicine

RESEARCH

Open Access

Role of tomosynthesis and ultrasound in the assessment of asymmetric breast densities: a comparative prospective study

Rasha Osama Abdel Ghany Ahmed[1*], Mohamed Abo El-Hoda Darwish[2], Nivine Abd Elmoneim Chalabi[2] and Salma Hassan Tantawy[2]

Abstract

Background Tomosynthesis is a recent advancement of full-field digital mammography involves transforming two-dimensional (2D) breast images into three dimensions (3D) images. It reduces the adverse effect of tissue superimposition on conventional 2D- mammography, therefore having high potential enhancing identification and assessment of asymmetric breast densities. The aim of the study was to assess and compare the diagnostic performance of breast ultrasound and 3D digital breast tomosynthesis in the assessment of asymmetric breast densities.

Results In the current study, 80 patients with 80 mammographically and/or tomosynthesized breast asymmetries were included. The patients' ages ranged from 30 to 70 years old, with a mean age of 47.2 ± 9.2 SD. Breast ultrasound outperformed digital breast tomosynthesis in terms of diagnostic performance. Tomosynthesis had a sensitivity of 86.4%, specificity of 93.1%, positive predictive value of 82.6%, negative predictive value of 94.7%, and accuracy of 91.3% compared to ultrasounds' sensitivity of 100.00%, specificity of 93.1%, positive predictive value of 84.6%, negative predictive value of 100.00%, and accuracy of 95%.

Conclusions Incorporating ultrasonography in the assessment of asymmetric breast densities outperformed tomosynthesis and shown to be more precise in characterisation of lesions underlying asymmetric breast density.

Keywords Mammography, DBT, US, Breast asymmetries

Background

Although breast size and parenchymal pattern might vary greatly, breasts typically have a symmetrical shape and have a comparable density, architecture, and distribution of fibroglandular tissue. However, asymmetric breast tissue is a common observation in screening and diagnostic mammography.

*Correspondence:
Rasha Osama Abdel Ghany Ahmed
rasha1.osama1@gmail.com
[1] Radiodiagnosis Department, Al Ahrar Teaching Hospital, Zagazig, Egypt
[2] Radiodiagnosis Department, Faculty of Medicine, Ain Shams University, Cairo, Egypt

In contrast to a mass, which is three-dimensional, asymmetric breast tissue is defined as having a greater volume or density of breast tissue in one breast than in the corresponding area in the contralateral breast. It lacks a defined contour and resembles normal fibroglandular tissue, with fat interspersed throughout and no outward convex margins [1–3].

Asymmetric breast densities were grouped into four categories in the 5th edition of the Breast Imaging-Report and Data System Atlas (BI-RADS): asymmetry, focal asymmetry, global asymmetry, and developing asymmetry [1].

Normal breast tissue variations, surgical changes, or hormone replacement treatment can all result in asymmetric breast tissue, which is often a benign appearance. Asymmetric breast densities, on the other hand, are the

second most prevalent source of false negative screening recall assessments and account for 6% of non-palpable, screen-detected malignancies and 27% of missed cancers [1].

The current standard screening procedure for breast cancer is mammography screening, which is recognised as the most accurate imaging modality for early breast cancer detection [4].

The sensitivity and specificity of mammography are limited, especially when it comes to locating and categorising breast tumours in dense breasts. Full-field digital two-dimensional (2D) mammography recently underwent a transformation that creates three-dimensional breast images (3D). It has the potential to boost the diagnosis of breast cancer since it lowers the effect of tissue superimposition on traditional 2D-mammography [5].

Breast US has proved to be excellent modality in the assessment of asymmetric breast density, as it enhances visualisation of lesion characteristics (e.g. shape, boundary, orientation, length/width ratio, echogenicity, calcification, posterior features) beneath breast asymmetry, it reliably differentiates solid from cystic lesions and detects if the cystic lesion is simple, complicated or complex. It has additional benefits as evaluating lesions in real time, low cost and no radiation exposure [2, 6].

Methods

Patients

In this prospective analysis of 80 females between October 2020 and August 2022, 28 (35%) of whom presented for screening and 52 (65%) of whom were symptomatic and referred from the clinic for a diagnostic mammogram and/or tomosynthesis. Patients were sent to the breast imaging unit with their ages ranged between 30 and 70 years, with a mean age of 47.2±9.2 SD years.

All patients were subjected to clinical examinations, full history taking, demographic analysis and full US study for the breast and axilla.

Inclusion criteria

(1) Women ≥ the age of 30 who had asymmetric breast density detected on mammography and tomosynthesis (including females who had previous surgery).

Exclusion criteria

1. Mammography contraindication as pregnant women.
2. Patients who had recent biopsy (less than 6 weeks) prior to mammography.
3. Patients who received neoadjuvant chemotherapy for breast cancer.

Ethics

Medical ethics were taken into account. The patient was told of the examination's specifics, informed consent was acquired, and the patient had to be familiar with the examination. The Ethics Committee gave its approval to this work.

Equipment

1. Using digital breast tomosynthesis (Senographe Pristina, GE Healthcare, USA) in performing both diagnostic 3D digital breast tomosynthesis and traditional 2D digital mammography screening.
2. Breast ultrasound examination utilising a superficial matrix linear 12–15 frequency probe and a GE Logic P9 machine.

Technique

Technique of mammography and tomosynthesis

- Proper positioning and compression were applied to each breast. For both techniques, two views—craniocaudal (CC) and mediolateral oblique (MLO)—were captured for each breast. With a 25° scan angle, 12–15 2D projections were acquired for 3D DBT. From the 2D projections, a succession of pictures (slices) of the whole breast were used to rebuild the 3D volume of the compressed breast. Liquid–crystal display (LCD) panels received images from both methods for reading. No further views were required since lesion identification could be facilitated by zooming, adjusting contrast, brightness, blackness, inverting the backdrop, and other tools while viewing digital pictures on LCD displays.
- The patients were all standing when the views were taken.

Technique of breast ultrasound

- All patients were subjected to full US study for the breast and axilla, all US images were acquired knowing the results of the tomosynthesis and mammography. The patient's arm was relaxed and flexed behind the head as US scanning of the whole breast, the axillary tail, and the axilla on both sides was done. The scanning included grey-scale images of breast lesions taken in at least two orthogonal planes (radial/anti-

radial imaging or transverse/longitudinal imaging), with specific attention paid to the predicted site of the asymmetry depicted at mammographic and/or tomosynthesis.

Image analysis and interpretation

- The FFDM and DBT pictures were brought to the workstation and interpreted individually (i.e. the images of FFDM were interpreted without knowledge of the DBT findings). Two devoted radiologists with ten years of breast imaging expertise read prospectively all studies. The US pictures were then viewed after the same two radiologists had assessed the FFDM and DBT, and they were allowed to modify the BI-RADS categorization (upgrade or downgrade it). The same two radiologists gave the final BI-RADS descriptor, in consensus, for each lesion after reviewing the DM, DBT, and US pictures' results collectively after one day. In case of disagreement in image interpretation, a third radiologist with more than 15 years of breast imaging expertise resolved it and gave the final BIRADS. The 1-day space was intended to reduce the memory bias of the radiologists.
- Finally, using the BI-RADS lexicon created by the American College of Radiology, each lesion was given five independent BI-RADS classifications (one by FFDM, DBT, US, one by combined FFDM and DBT, and one by combined FFDM and DBT and US). All radiologists were guided only by the clinical data and were blind to the pathology results.

Image analysis and interpretation of mammography and tomosynthesis

Careful right-to-left breast comparison was made of the same mammographic and/or tomosynthesis projections for detection of abnormalities including asymmetry then each asymmetry was evaluated with respect to:

- Its localization and type guided by the four types of asymmetry in the 5th edition of BI- RADS lexicon as follows:

  (a) Asymmetry: if a finding is seen on only one standard screening view.
  (b) Focal asymmetry: it is a mammographic abnormality seen on at least two different mammographic views, lacking outward convex borders, and often displaying interspersed fat.
  (c) Global asymmetry: it is an asymmetry occurs over a greater volume of the breast (at least a quadrant), compared to the corresponding region in the contralateral breast.
  (d) Developing asymmetry: it is a focal asymmetry that is newly developed or increasing in size or conspicuity compared with previous studies.

- Evaluating associated features such as distortion, microcalcifications, and skin and nipple changes.

Image analysis and interpretation of breast ultrasound

- B-mode US images of the associated lesions were assessed for their morphological features such as mass shape, margin, boundary, orientation, posterior acoustic features, and echogenicity (using BI-RADS lexicon descriptors), US images also used to determine whether the asymmetry was caused by non-mass area or by normal overlapping fibro-glandular tissue.
- Any associated features, such as calcification, architectural distortion, skin thickening or retraction, nipple retraction, or axillary lymphadenopathy was reported, then the final BI- RADS category, likelihood of malignancy (%), and management strategy was provided.
- Follow-up (over two years), fine needle aspiration cytology (for BIRADS 1, 2 and 3), and histopathological results of biopsy and surgical samples (for BIRADS 4 and 5 lesions, n = 26 cases) served as the gold standard of reference.

Statistical analysis

- The collected data were presented by tables and graphs and analysed by a computer data base software program (Statistical Package for the Social Science version 25).
- Data were statistically reported using frequencies (number of cases) and percentages.
- Accuracy was represented using the terms of sensitivity, specificity, positive predictive value, negative predictive value, and overall accuracy, the likelihood ratio of a positive test and the likelihood ratio of a negative test.

Results

This research, a prospective analysis, included 80 females, of whom 28 (35%) were screened, while 52 (65%) were symptomatic and referred from the clinic for a diagnostic mammography and/or tomosynthesis.

The patients' ages ranged from 30 to 70 years with mean age of 47.2 ± 9.2 SD.

Both benign and malignant tumours were identified. Malignant lesions were 22/80 (about 27.5%), whereas benign lesions were 58/80 (around 72.5%). Within the 58 benign lesions 26/80 (32.5%) lesions were condensed normal breast tissue (due to summation artefact), 14/80 lesions (17.5%) were breast adenosis, 4/80 (5%) lesions were fibrocystic changes, 1/80 lesion (1.3%) was fibroadenoma, 3/80 lesions (3.8%) were ductectasia, 1/80 lesion (1.3%) was simple cyst, 1/80 lesion (1.3%) was intra-mammary LN, 2/80 lesions (2.5%) were mastitis, 1/80 lesion (1.3%) was granulomatous mastitis and 5/80 lesions (6.3%) were post-operative changes. While within the malignant lesions which represented 22 cases in our study, 19/80 (23.8%) cases were invasive duct carcinoma and 3/80 (3.8%) of cases were ductal carcinomas in situ, we did not find lobular carcinoma in our study (Table 1).

Regarding the distribution of various types of asymmetries in our investigated patients according to their mammographic and/or tomosynthesis results, asymmetry was detected in 8/80 (10%) lesions, focal asymmetry in 52/80 (65%) lesions, global asymmetry in 19/80 (23.7%) lesions, and developing asymmetry in 1/80 (1.3%) lesions (Table 2).

Additionally, 8/8 cases of asymmetry (100 %) were benign and 0/8 (0 %) were malignant, 42/52 (80.7 %) cases of focal asymmetry were benign and 10/52 (19.2 %) cases were malignant. Out of 19 cases with global asymmetry, 7 cases (36.8%) were benign and 12 cases (63.1%) were malignant. The only case of developing asymmetry in our research found to be benign (100%) (Table 3).

Table 1 Distribution of various pathological findings within benign and malignant lesions among the examined patients

Diagnosis	(*n* = 80)	
	No	%
Benign:		
Condensed normal breast tissue (summation artefact)	26	32.5
Breast adenosis	14	17.5
Fibrocystic changes	4	5
Fibroadenoma	1	1.3
Ductectasia	3	3.8
Simple cyst	1	1.3
Intra-mammary LN	1	1.3
Mastitis	2	2.5
Granulomatous mastitis	1	1.3
Postoperative changes	5	6.3
Malignant:		
IDC	19	23.8
DCIS	3	3.8

Table 2 Distribution of different types of asymmetries according to mammographic and tomosynthesis findings among the studies patients

Type of asymmetry	(*n* = 80)	
	No	%
Asymmetry	8	10
Focal	52	65
Global	19	23.7
Developing	1	1.3

Mammography results

- Each lesion was assigned a BIRADS category based on the BIRADS morphological descriptors at mammography; 33/80 (41%) of the lesions were classified as malignant (BIRAD 4 and 5), whereas 47/80 (58.8%) of the lesions were classified as benign (BIRADS 1, 2, and 3) (Table 4).
- Guided by the pathology results 18/22 (81.8%) lesions were true positives, 15/58 (25.8%) lesions were false positive, 4/22 (18.1%) lesions were false negatives and 43/58 (74.1%) lesions were true negatives (Table 5).
- In our study, the false positive included 8 cases of normal breast tissue, 5 cases of post-operative changes, one case of fibroadenoma and one case of granulomatous mastitis, they were due to over lapping of fibroglandular tissue, increase breast density or obscured margins of a benign lesion.
- Obscured malignant lesions in ACR C and D heterogeneous dense breast count for the erroneous negative findings.

Table 3 Asymmetric densities and their correlation to their final diagnosis

Asymmetry	Benign (*n* = 58)	Malignant (*n* = 22)	Total
Asymmetry	8/8 (100%)	0/8 (0%)	8 (10%)
Focal	42/52 (80.7%)	10/52 (19.2%)	52 (65%)
Global	7/19 (36.8%)	12/19 (63.1%)	19 (23.7%)
Developing	1/1 (100%)	0/0 (0%)	1 (1.3%)
Total	58 (72.5%)	22 (27.5%)	80 (100%)

Table 4 The BI-RADS categories by mammography, tomo, US and combined protocols among the studied cases

Variable	DM		Tomo		US		DM + tomo		DM + tomo + US	
	No	%	No	%	No	%	No	%	No	%
BIRADS:										
1	9*	11.2*	22	27.5	28	35	22	27.5	28	35
2			15	18.8	18	22.5	15	18.8	19	23.8
3	38	47.5	20	25	8	10	18	22.5	7	8.7
4	31	38.8	19	23.8	17	21.3	21	26.2	17	21.3
5	2	2.5	4	5	9	11.3	4	5	9	11.2
Final:										
Benign (BIRADS 1, 2 and 3)	47	58.8	57	71.3	54	67.5	55	68.8	54	67.5
Malignant (BIRADS 4 and 5)	33	41.2	23	28.7	26	32.5	25	31.2	26	32.5

(*) = BIRADS 0 and 1, tomo; tomosynthesis

Table 5 Validity of Mammography in diagnosis of breast lesions compared to pathology results among the studied cases

Mammography	Pathology		Total	*K*	*p*
	Malignant	Benign			
Malignant	18 (TP)	15(FP)	33	0.55	0.001*
Benign	4 (FN)	43 (TN)	47		
Total	22	58	80		
Validity	Sensitivity:81.8%		Specificit:74.1%		
	PPV:54.5%		NPV:91.5%		
	Accuracy:76.3%				

K: Crohon's Kappa test, *: Significant ($p < 0.05$)

Table 6 Validity of Tomosynthesis in diagnosis of breast lesions compared to pathology results among the studied cases

Tomosynhhesis	Pathology		Total	*K*	*p*
	Malignant	Benign			
Malignant	19 (TP)	4 (FP)	23	0.79	< 0.001**
Benign	3 (FN)	54 (TN)	57		
Total	22	58	80		
Validity	Sensitivity:86.4%		Specificit:93.1%		
	PPV:82.6%		NPV:94.7%		
	Accuracy:91.3%				

K: Crohon's Kappa test, **: Highly Significant ($p < 0.001$)

3D digital tomosynthesis results

- Tomosynthesis' identified lesions were given a BIRADS category in accordance with the mammography BIRADS lexicon, and 57/80 (71.2%) of the lesions were deemed benign (BIRADS 1, 2, and 3), whereas 23/80 (28.7%) of the lesions were deemed malignant (BIRADS 4 and 5) (Table 4).
- Guided by the pathology findings, 19/22 (86.3%) of the lesions were true positives, 4/58 (6.8%) were false positives, 3/22 (13.6%) were false negatives, and 54/58 (93.1%) were true negatives (Table 6).
- When compared to digital mammography, tomosynthesis gave fewer false-positive findings (4 instead of 15 cases), as it eliminated tissue overlap and enhanced lesion visualisation. The dense breast tissue or a blurred or veiled lesion edge attribute to the false positive results. One case of fibroadenoma, one case of granulomatous mastitis and two cases of fibrocystic changes were among the false positive results.
- Three cases had false negative results, including one with a deeply seated lesion missed on the mammography film view and two cases with diffuse oedema and diffuse infiltration (misdiagnosed as breast mastitis).
- Tomosynthesis's sensitivity was 86.4%, specificity was 93.1%, positive predictive value was 82.6%, negative predictive value was 94.7%, and accuracy was 91.3% in this study.

Breast ultrasound results

- According to the BIRADS morphological descriptors, each lesion was given an ultrasound BIRADS category. Of the 80 lesions, 54 (67.5%) were benign (BIRADS 1, 2, and 3), and 26 (32.5%) were malignant (Table 4).
- Following reviewing the pathology results, 22/22 (100%) lesions were found to be true positives, 4/58 (6.8%) lesions were found to be false positives, there were no false negative results, and ultimately 54/58 (93.1%) lesions were found to be true negatives (Table 7).

Table 7 Validity of Ultrasound in diagnosis of breast lesions compared to pathology results among the studied cases

Ultrasound	Pathology		Total	*K*	*p*
	Malignant	Benign			
Malignant	22 (TP)	4 (FP)	26	0.88	< 0.001**
Benign	0 (FN)	54 (TN)	54		
Total	22	58	80		
Validity	Sensitivity:100%		Specificit:93.1%		
	PPV:84.6%		NPV:100%		
	Accuracy:95%				

K: Crohon's Kappa test, **: Highly Significant ($p < 0.001$)

- Among the false-positive outcomes were post-operative changes and granulomatous mastitis. This was explained by the fact that these lesions met the same morphologic criteria as a malignant breast lesion making them false positives.
- Breast ultrasonography, among the other modalities in this study, had the highest sensitivity, with a sensitivity of 100.00%, a specificity of 93.1%, a positive predictive value of 84.6%, a negative predictive value of 100.00%, and an accuracy of 95%.

Combined digital mammography and 3D tomosynthesis protocol

- According to the BIRADS mammography morphology descriptors, a combined digital mammography and 3D tomosynthesis BIRADS category was given to each lesion; 55/80 (68.8%) lesions were deemed benign (BIRADS 1, 2, and 3), whereas 25/80 (31.2%) lesions were deemed malignant (Table 4).
- When compared to the pathology results, 19/22 lesions (86.3%) were true positives, 6/58 lesions (10.3%) were false positives, 3/22 (13.6%) were false negatives, and 52/58 lesions (89.6%) were true negatives (Table 8).
- When compared to digital mammography alone, the false positive results were lower (becoming 6 instead of 15 cases), as tomosynthesis overcame tissue overlap problem and offers a clear visualisation of the lesion.
- Consequently, the combined performance of digital breast mammography and 3D tomosynthesis was 86.4% sensitive, 89.7% specific, 76% positive, and 94.5% negative.

Combined digital mammography, 3D tomosynthesis and ultrasound protocol

- According to the BIRADS morphological descriptors, a BIRADS category was given for each lesion using combined digital mammography, 3D tomosynthesis, and ultrasound findings; 54/80 (67.5%) lesions were deemed benign (BIRADS 1, 2, and 3), whereas 26/80 (32.5%) lesions were deemed malignant (BIRADS 4 and 5) (Table 4).
- On reviewing and comparing the pathological data, 54 (93.1%) of the 58 lesions were true negatives, 0 (0%) of the 58 lesions was false negative, 22 (100.00%) of the 58 lesions were true positives and four (6.8%) of the 58 lesions were false positive (Table 9).
- In this research work, the sensitivity, specificity, positive predictive value, and negative predictive value for combined digital mammography, 3D tomosynthesis, and ultrasound were 100.00%, 93.1%, 84.6%, and 100%, respectively, and an accuracy of 95%.

Table 5 and Fig. 1 show that there was a statistically significant moderate agreement between mammography and pathology in diagnosis of breast lesions with sensitivity 81.8%, specificity 74.1% and accuracy 76.3%.

Table 8 Validity of Combined Digital Breast Mammography and 3D Tomosynthesis in diagnosis of breast lesions in comparison to pathology among the studied cases

Mammography and tomosynthesis	Pathology		Total	*K*	*p*
	Malignant	Benign			
Malignant	19 (TP)	6 (FP)	25	0.77	< 0.001**
Benign	3 (FN)	52 (TN)	55		
Total	22	58	80		
Validity	Sensitivity:86.4%		Specificit:89.7%		
	PPV:76%		NPV:94.5%		
	Accuracy:88.8%				

K: Crohon's Kappa test, **: Highly Significant ($p < 0.001$)

Table 9 Validity of Combined Digital Breast Mammography, 3D Tomosynthesis and ultrasound in diagnosis of breast lesions in comparison to pathology among the studied cases

Mammography, tomosynthesis and ultrasound	Pathology		Total	*K*	*p*
	Malignant	Benign			
Malignant	22 (TP)	4 (FP)	26	0.88	< 0.001**
Benign	0 (FN)	54 (TN)	54		
Total	22	58	80		
Validity	Sensitivity:100%		Specificit:93.1%		
	PPV:84.6%		NPV:100%		
	Accuracy:95%				

K: Crohon's Kappa test **: Highly Significant ($p < 0.001$)

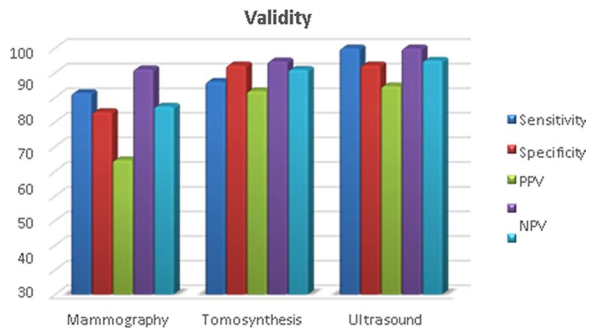

Fig. 1 Validity of different diagnostic methods compared to pathology results in diagnosis of breast lesions among the studied cases

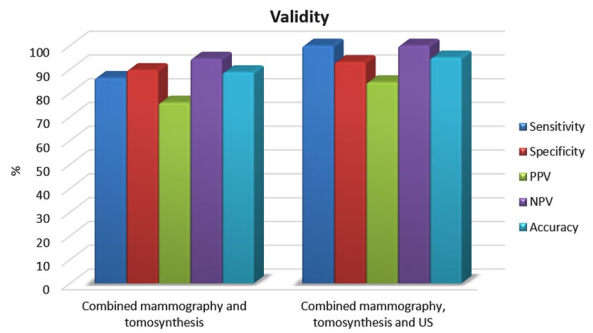

Fig. 2 Validity of combined diagnostic methods in comparison to pathology in diagnosis of breast lesions among the studied cases

Table 6 and Fig. 1 show that there was a statistically significant good agreement between tomosynthesis and pathology in diagnosis of breast lesions with sensitivity 86.4%, specificity 93.1% and accuracy 91.3%.

Table 7 and Fig. 1 show that there was a statistically significant perfect agreement between ultrasound and pathology in diagnosis of breast lesions with sensitivity 100%, specificity 93.1% and accuracy 9%.5.

The combined protocols results

Table 8 and Fig. 2 demonstrate that combined digital breast mammography and 3D tomosynthesis and pathology had a statistically good agreement in the diagnosis of breast lesions, with sensitivity 86.4%, specificity 89.7%, and accuracy 88.8%.

Table 9 and Fig. 2 demonstrate that there was 100% sensitivity, 93.1% specificity, and 95% accuracy in the combined diagnosis of breast lesions using digital breast mammography, 3D tomosynthesis, ultrasound, and the pathology results.

Our cases are illustrated in Figs. 3, 4, 5 and 6.

Discussion

On mammography, the distribution of ducts, adipose tissue, and fibroglandular tissue in the right and left breasts typically results in a fairly symmetric pattern. The most frequent presentation for the asymmetric density attributed to normal breast tissue variation, although it is also possible that it is the lone sign of breast cancer.

One of the most difficult parts of mammographic interpretation is differentiating between them. Moreover, in this regard, it is crucial to carefully compare the two breasts on the mammography and/or tomosynthesis, as well as to compare them to prior mammograms. The identification and evaluation of asymmetric breast density results are crucial steps in mammographic interpretation that will improve the detection of breast cancer and provide many women the chance for an earlier diagnosis.

Regarding distribution of different types of asymmetries according to mammographic and/or tomosynthesis findings among our studied cases, our results agree with multiple different previous literatures, one of them the study done by Wessam et al. [7] who stated that 88/125 (70.4%) females had focal asymmetry, 26/125

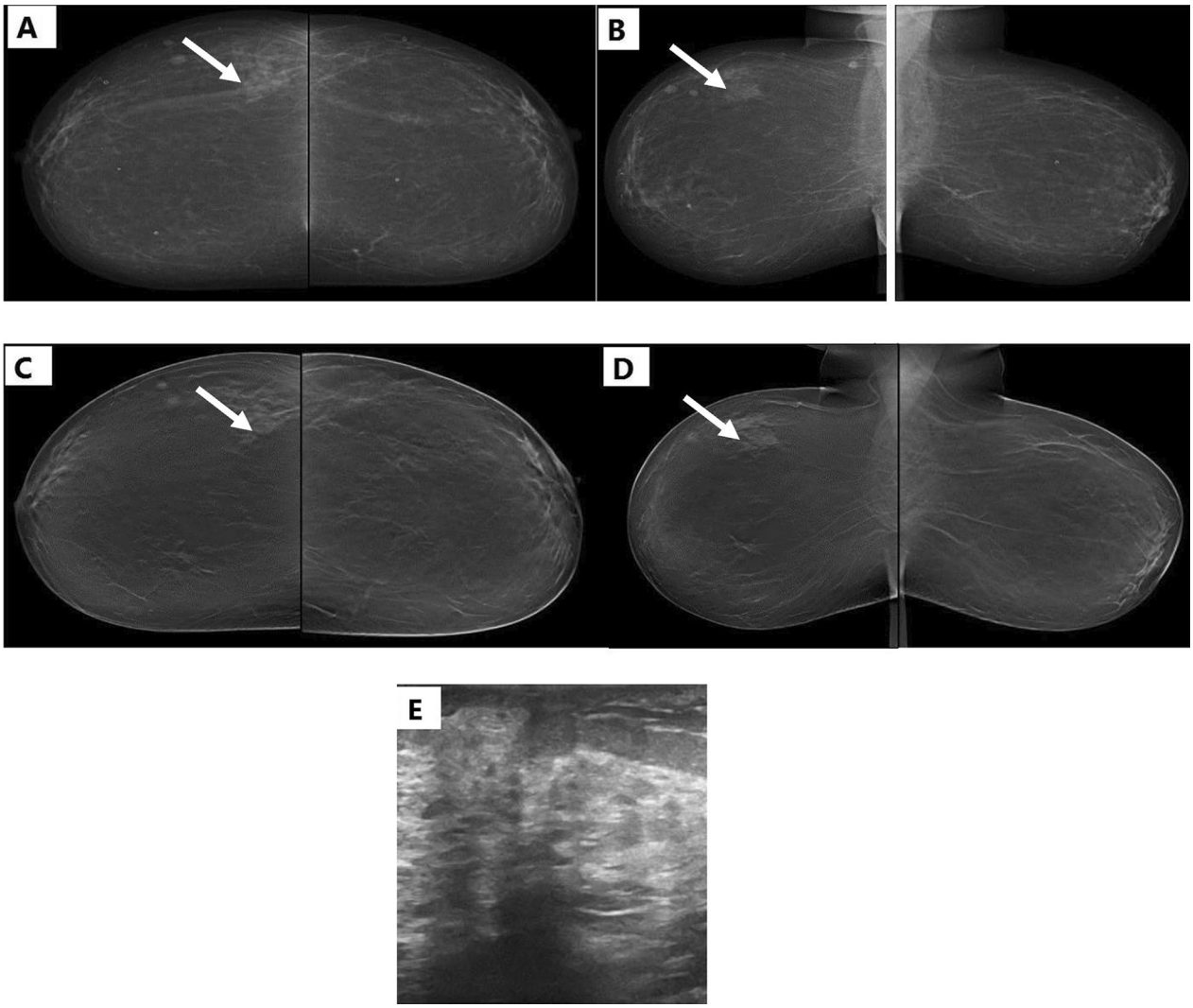

Fig. 3 Benign focal asymmetry in a 49 years old female complaining from palpable right breast lump with positive family history for cancer breast. CC (**A**) and MLO (**B**) mammography views of both breasts revealed right breast UOQ area of focal asymmetry (arrows), patient then proceeded to CC (**C**) and MLO (**D**) 3D digital tomosynthesis that better delineated the asymmetry (arrows) with no associated masses, architectural distortion or micro-calcification assigned as BIRADS 4a. (**E**) Ultrasonography image revealed isolated breast adenosis in the form of hyperechoic parenchyma with a mottling appearance (BIRADS 3). Ultrasound here confirmed the benign nature of the asymmetry which represented benign focal breast adenosis with absence of underlying breast lesions, which was confirmed by follow-up

(20.8%) had global asymmetry, 10/125 (8%) had asymmetry, and 1/125 (0.8%) had developing asymmetry while according to Zidan et al. [8] 4% one view asymmetry, 28% global asymmetry, 64% focal asymmetry, and 4% developing asymmetry were found among the 50 asymmetric densities.

We recommend the use of DBT as an additional imaging modality to increase diagnostic accuracy in detecting and characterising asymmetric breast lesions because the tomosynthesis results of our study demonstrated high diagnostic performance in the assessment of asymmetric breast densities compared to FFDM.

Our research supports Peppard et al. [9] assertion that DBT is helpful for evaluating a focal asymmetry. It can be used to support a discovery and describe it as a real asymmetry, rule out the finding as a superimposition, or reclassify the finding as a mass.

The use of DBT in assessing breast asymmetry can increase sensitivity and specificity in breast cancer screening and decrease the number of un-necessary biopsies and short-interval follow-up examinations, according to Gurando et al. in [1]. As a result of summing artefact, DBT is better able to distinguish benign

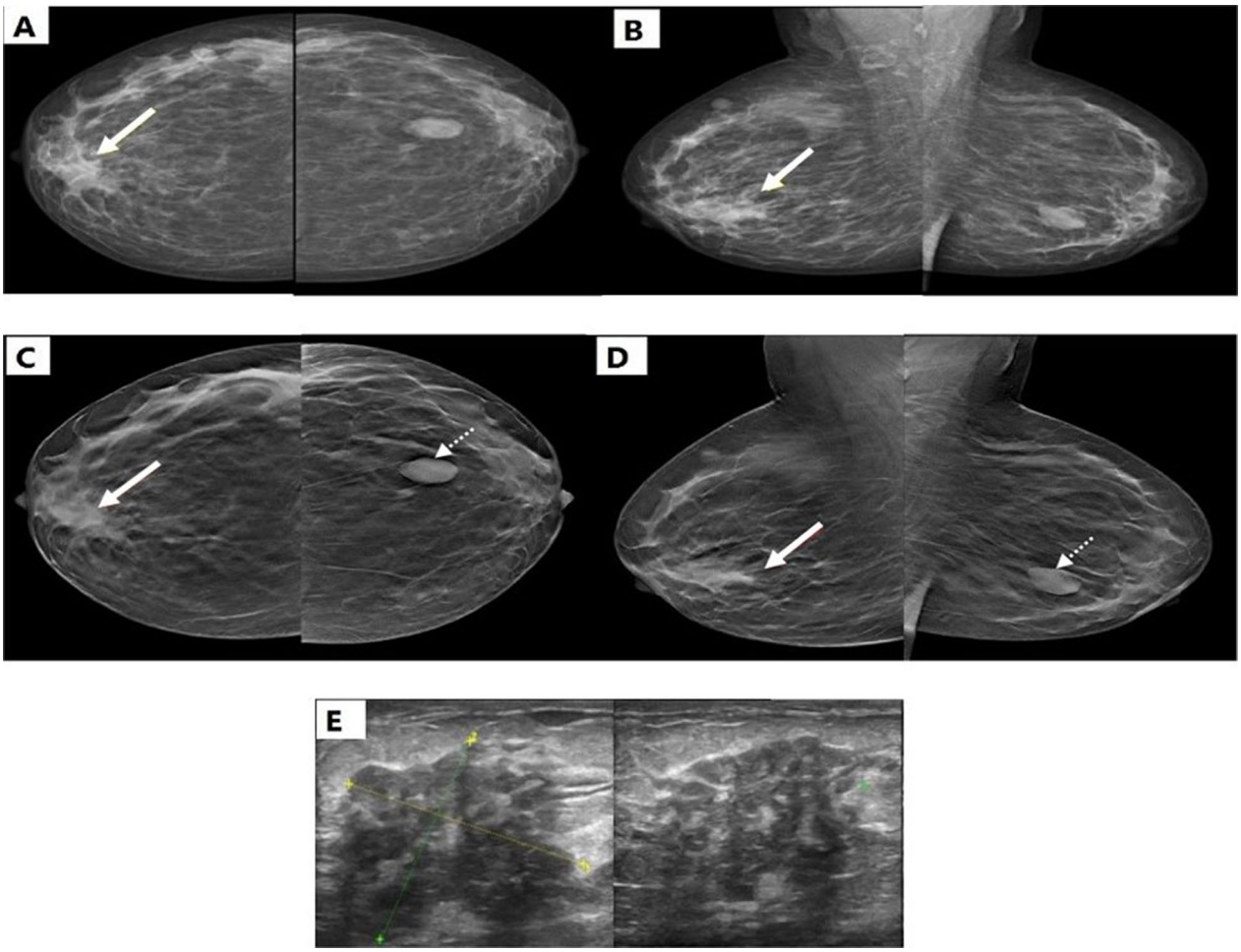

Fig. 4 Malignant focal asymmetry in a 49 years old female complaining from palpable right breast lesion (**A**) CC and (**B**) MLO mammography views of both breasts revealed right breast LIQ para-areolar area of focal asymmetry (arrows). (**C**) CC and (**D**) MLO 3D digital tomosynthesis was done and showed associated subtle architectural distortion, no suspicious microcalcification assigned as BIRADS 4a (arrows), the well circumscribed oval shape dense mass lesion (dashed arrows) at LOQ represents fibroadenoma (BIRADS 3). (**E**) Ultrasound revealed ill-defined area of pathological altered heterogeneous parenchyma, no associated suspicious LNs given BIRADS 4a. The focal asymmetry here proved ductal carcinoma in situ by histopathological correlation

breast asymmetry from breast malignancies, which can resemble normal fibroglandular tissue at FFDM.

We also concurred with Aragon et al. [10] who claim that tomosynthesis improves diagnostic mammography's sensitivity and specificity. The sensitivity and specificity of tomosynthesis are 93% and 70%, respectively, which is close to our research results.

Finally, Waheed et al. [11] study findings demonstrated that we may more accurately describe asymmetric densities and enhance BIRADS classification by integrating tomosynthesis images in the routine mammographic scan, and in line with Bahl et al. [12] who showed that DBT reduced the number of false-positive tests brought on by asymmetries.

Even though DBT yielded better diagnostic performance than DM, some breast lesions are still difficult to diagnose with DBT.

So ultrasound was performed for all cases and it showed the highest diagnostic performance in the assessment of asymmetric breast densities compared to tomosynthesis alone or when combined with DM.

Similar research to ours was carried out by Abousamra et al. in [13] who discovered that ultrasonography had a diagnostic accuracy of 86.7%, a positive predictive value of 66.7%, a negative predictive value of 95.5%, and a sensitivity of 85.7%. The combined sono-mammography's diagnostic accuracy (93.3%) outperformed the accuracy of each test used alone.

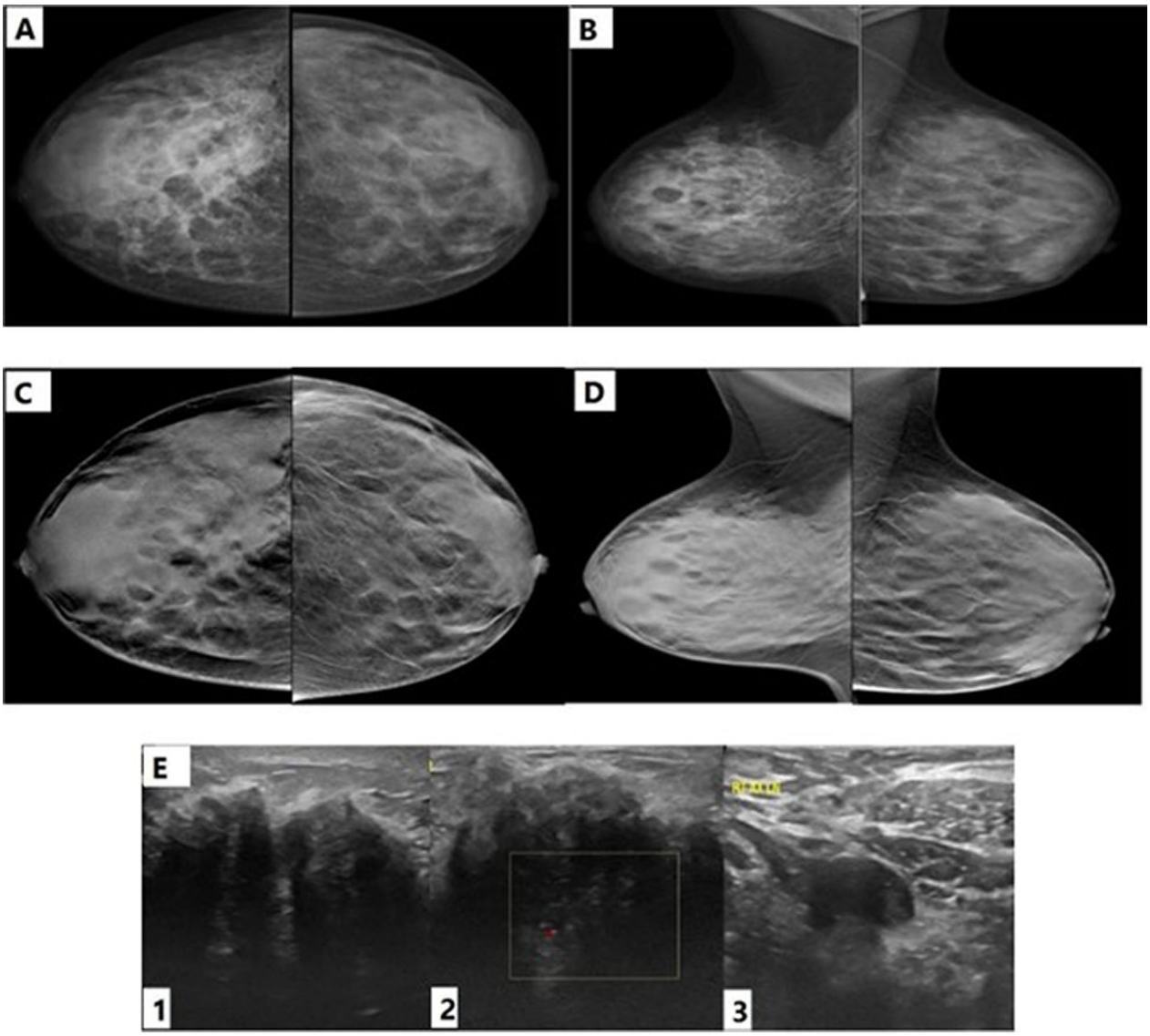

Fig. 5 False negative global asymmetry in a 30-year female patient complaining from diffuse right breast swelling and hardness. (**A**) CC and (**B**) MLO mammography views of both breasts revealed global asymmetry of the right breast with diffuse skin thickening and oedema pattern. (**C**) CC and (**D**) MLO 3 D tomosynthesis views of both breasts were inconclusive and did not add to the mammography showed no underlying masses, architectural distortion or suspicious micro-calcification assigned as BIRADS 4a. Ultrasound images on (**E**) revealed heterogeneous altered pathological breast parenchyma extending from 10 to 1 O'clock (illustrated at images E- 1 and 2) associated with enlarged pathological axillary LN with thickened cortex and infiltrated fatty hilum (E-3) (BIRADS 5). The lesion was infiltrating duct carcinoma by histopathological analysis

According to Kim et al. [14], prior prospective clinical studies have shown that using ultrasound as a supplement to mammography appropriately increases the sensitivity and specificity of breast cancer diagnoses, especially in younger and women with dense breasts.

As a result, our study advises using US in conjunction with a combined DM and DBT strategy since it enhanced BI-RADS performance for the detection of characterisation of asymmetric breast lesions, perhaps leading to better disease treatment. Similar results were seen in several additional investigations, where the inclusion of DBT resulted in a reduction in the number of false cases.

We identified higher accuracy rates in assessment of asymmetric breast density when evaluated by combined FFDM, DBT and US than when evaluated by each modality solely.

In terms of the distribution of the final BIRADS categories, we observed no appreciable statistical difference between the diagnostic performance of US findings and

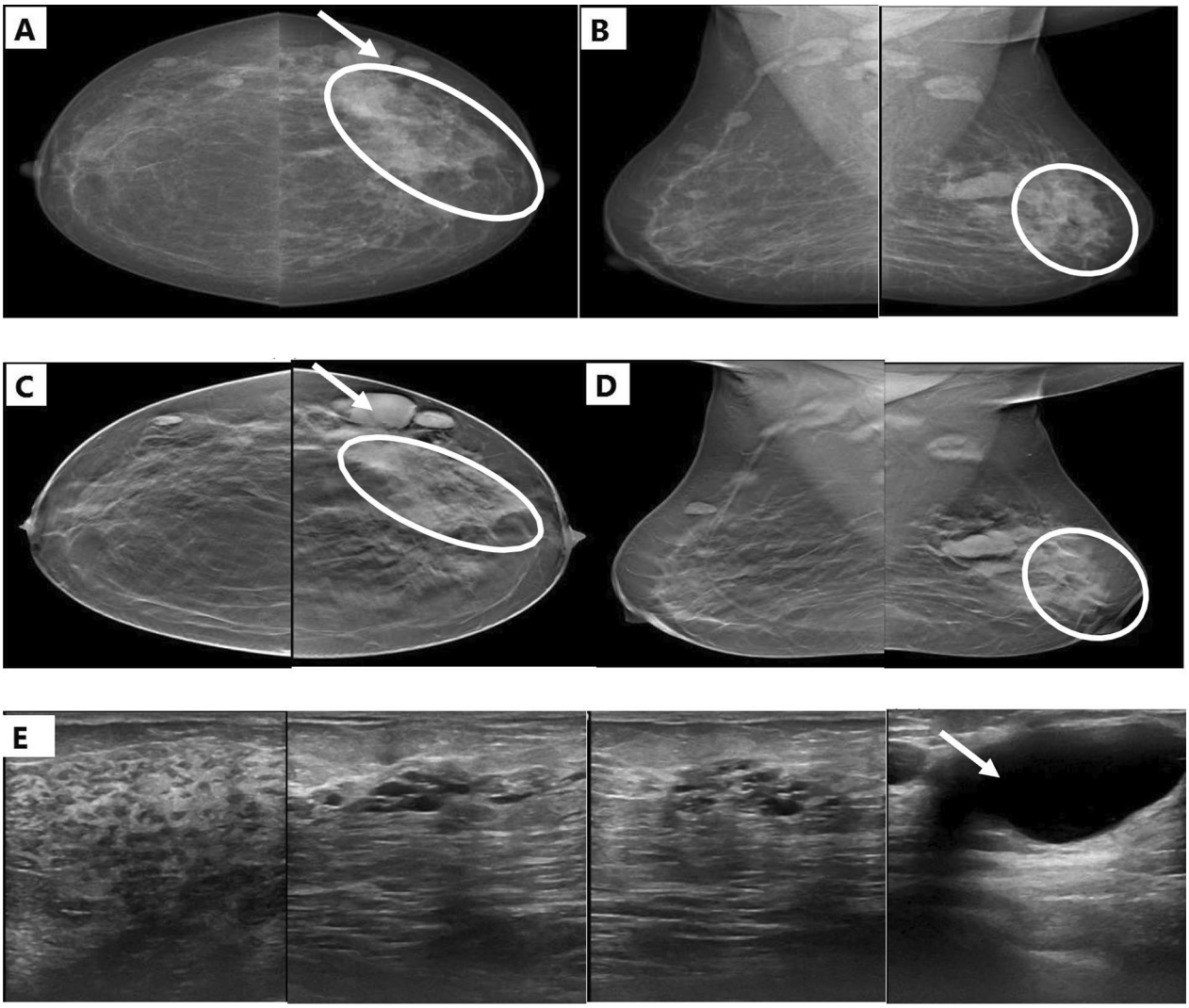

Fig. 6 Global asymmetry in a 33-year female patient complaining from left breast lump. (**A**) CC and (**B**) MLO mammography views of both breasts revealed global asymmetry of the left breast (ellipses) with multiple well defined superficially located dense oval shaped masses at UOQ (arrow in A). (**C**) CC and (**D**) MLO 3 D tomosynthesis views of both breasts better delineated the margins of the masses (arrow in C) yet did not add to the mammographic findings in characterisation of the asymmetry (ellipses) (BIRADS 3). Ultrasound images on (**E**) revealed corresponding increased parenchymal echogenicity with multiple scattered well defined anechoic cysts with clear content (largest of them marked by the arrow) (BIRADS 2). The findings suggested fibrocystic changes in the breast

combined US, DBT, and FFDM screening mammography in our study.

Our research is consistent with that published by Thigpen et al. [15], who found that adding ultrasound screening can boost the rate of breast cancer detection in women with dense breasts who have a higher risk of developing the disease as well as lower sensitivity to mammography alone by 1.9–4.2%.

According to Nam et al. [16], combination screening identified extra 4.2 malignancies per 1000 women at high risk for breast cancer, according to a multicentre trial of combined screening with mammography and the US.

Additionally, we agree with Kim et al. [14] who discovered that using ultrasound as a supplement to mammography properly increases the sensitivity and specificity of breast cancer diagnosis, especially in younger and women with dense breasts.

We are consistent with Abousamra et al. [13] findings, which compared the sensitivity, specificity, positive and negative predictive values, and diagnostic accuracy of mammography, sonography, and their combination. He discovered that the combined sensitivity and specificity of sono-mammography were 100% and 91.3%, respectively.

Our research has few limitations. The small sample size comes first (80 patients). Second, we did not emphasise on Doppler role in our study, and this may be attributed to the nature of most of the asymmetric breast lesions which are due to summation of normal glandular tissue.

Third, the combined DM and DBT strategy may have drawbacks due to its cost-effectiveness and the additional radiation exposure.

As a result, when there is still uncertainty in the BI-RADS category after conducting DM alone, we recommend that the combined protocol be restricted to doubted lesions.

Conclusions

Ultrasound outperformed tomosynthesis in the assessment of asymmetric breast densities as it showed higher sensitivity, specificity, positive and negative predictive values compared to the digital breast tomosynthesis, and shown to be more precise at the diagnostic setting in characterisation of lesions underlying asymmetric breast density.

Abbreviations

2D	Two-dimensional
3D	Three-dimensional
US	Ultrasonography
DBT	Digital breast tomosynthesis
SD	Standard deviation
CC	Cranio-caudal
MLO	Medio-lateral oblique
LCD	Liquid–crystal display
FFDM	Full-field digital mammography
DM	Digital mammography
BI-RADS	Breast imaging reporting and data system
B-mode	Brightness mode
n	Number
ACR	American College of Radiology
LN	Lymph node

Acknowledgements

Not applicable.

Author contributions

(1) RO wrote the manuscript and collected patient data and is responsible for correspondence to the journal. (2) MA is the author of the research idea. (3) NC participated in the design and review of the study. (4) ST participated in the design and review of the study. All authors have read and approved the manuscript.

Funding

No funding sources.

Availability of data and materials

The datasets used and analysed during the current study are available from the corresponding author on reasonable request.

Declarations

Ethics approval and consent to participate

The study was approved by the Department of Radiology, Faculty of Medicine Ain Shams University, Research Ethics Committee, Egypt, (Ethics Committee reference number: is not available. Our committee is going to settle a number in the future, but now it is not available). A written consent was obtained from each patient involved in this research before performing the study.

Consent for publication

Images included in the study are entirely unidentifiable and there are no details on individuals reported within the manuscript.

Competing interests

The authors declare that they have no competing interests.

Received: 10 December 2022 Accepted: 14 June 2023
Published online: 21 June 2023

References

1. Gurando AV, Babkina TM, Dykan IM, Kozarenko TM, Gurando VR, Telniy VV (2021) Digital breast tomosynthesis and full- field digital mammography in breast cancer detection associated with four asymmetry types. Wiad Lek 74(4):842–848
2. Chesebro AL, Winkler NS, Birdwell RL, Giess CS (2016) Developing asymmetries at mammography: a multimodality approach to assessment and management. Radiographics 36(2):322–340
3. Price ER, Joe BN, Sickles EA (2015) The developing asymmetry: revisiting a perceptual and diagnostic: radiology. Radiology 274(3):642–651
4. Pesce K, Orruma MB, Hadad C, Cano YB, Secco R, Cernadas A (2019) BI-RADS terminology for mammography reports: what residents need to know. Radiographics 39(2):319–320
5. Helvie M (2010) Digital mammography imaging: breast tomosynthesis and advanced applications. Radiol Clin N Am 48(5):917–929
6. Mokhtar O, Abd Elsalam S, Gamal G, Naguib E, Gomaa M (2020) 3D digital breast tomosynthesis versus US in evaluating breast asymmetries. Egypt J Radiol Nuc Med 51(1):1–10
7. Wessam R, Gomaa MMM, Fouad MA, Mokhtar SM, Tohamey YM (2019) Added value of contrast-enhanced mammography in assessment of breast asymmetries. Br J Radiol 92(1098):20180245
8. Zidan M, Saad SA, Abo Elhamd E, Galal HE, Elkady R (2020) Role of diffusion-weighted magnetic resonance imaging in assessment of mammographically detected asymmetric densities. Egypt J Radiol Nuc Med 51(1):1–10
9. Peppard HR, Nicholson BE, Rochman CM, Merchant JK, Mayo RC III, Harvey JA (2015) Digital breast tomosynthesis in the diagnostic setting: indications and clinical applications. Radiographics 35(4):975–990
10. Aragon LNS, Soto-Trujillo D (2021) Effectiveness of tomosynthesis versus digital mammography in the diagnosis of suspicious lesions for breast cancer in an asymptomatic population. Cureus 13(3):e13838. https://doi.org/10.7759/cureus.13838
11. Waheed H, Masroor I, Afzal S, Alvi MI, Jahanzeb S (2020) Digital breast tomosynthesis versus additional diagnostic mammographic views for the evaluation of asymmetric mammographic densities. Cureus 12(8):e9637
12. Bahl M, Mercaldo S, Dang PA, McCarthy AM, Lowry KP, Lehman CD (2020) Breast cancer screening with digital breast tomosynthesis: are initial benefits sustained? Radiology 295(3):529–539
13. Abousamra MF, Adel NM, Hanna MMN (2019) The role of digital mammography in the evaluation of asymmetric breast findings: in correlation with ultrasound. Minia J Med Res 30(3):277–283
14. Kim SJ, Park YM, Jung HK (2015) Non mass like lesions on breast sonography: comparison between benign and malignant lesions. J Ultras Med 33(3):421–430
15. Thigpen D, Kappler A, Brem R (2018) The role of ultrasound in screening dense breasts—a review of the literature and practical solutions for implementation. Diagnostics 8(1):20
16. Nam KJ, Han BK, Ko ES, Choi JS, Ko EY, Jeong DW, el al. (2015) Comparison of full-field digital mammography and digital breast tomosynthesis in ultrasonography-detected breast cancers. Breast 24(5):640–655

Publisher's Note