Agarwal *et al. Egypt J Radiol Nucl Med* (2023) 54:115
https://doi.org/10.1186/s43055-023-01059-0

Egyptian Journal of Radiology and Nuclear Medicine

CASE REPORT

Open Access

# A case report of Y-shaped bi-directional Fontan procedure: promising long-term outcomes for single ventricle physiology patients

Abhimanyu Agarwal[1†], Marc Cribbs[2†], Asmaa Naguib Ahmed[3†] and Mostafa Abozeed[3*†]

## Abstract

**Background** Achieving optimal hepatic factor distribution and total cavopulmonary resistance is crucial for long-term outcomes in single ventricle palliation patients. Y-shaped Gore-Tex Fontan procedure redirects hepatic drainage to both the right and left pulmonary arteries. The aim of this approach is to achieve bilateral pulmonary distribution of hepatic factors and reduce the risk of arteriovenous malformations that can develop in single-ventricle patients.

**Case presentation** We present a unique case of a 20 years old female with symptoms of heart failure, who has a history of complex heterotaxy with polysplenia, interrupted Inferior vena-cava, and double outlet right ventricle with unbalanced atrio-ventricular septal defect, d-malposed great arteries, and pulmonary atresia. Fenestrated Y-shaped Gore-Tex Fontan procedure was successfully done which was confirmed by performing cardiac CT angiography.

**Conclusions** Studies have shown that achieving balanced hepatic factor distribution and low resistance in the Fontan pathway can improve long-term outcomes. This procedure has demonstrated positive results in terms of oxygen saturation and reduced asymmetric blood flow distribution.

**Level of Evidence** Level 4, Case Report.

**Keywords** Y-shaped bidirectional Fontan graft, Cavopulmonary resistance, Multiplanar reconstructions, Arteriovenous malformation, Case report

## Background

Single ventricle congenital heart disease presents unique and complex management challenges. To alleviate volume overload on the ventricle as well as improve oxygen saturations, Fontan operation has become the mainstay of surgical palliation resulting in flow of all systemic venous flow directly to the lungs without first passing through the ventricle. It is used to treat a variety of complex congenital heart defects (tricuspid atresia, pulmonary atresia with intact ventricular septum, hypoplastic left heart syndrome, and double-inlet ventricle) [1]. It is a multi-stage procedure beginning with a connection of the SVC to the RPA (known as Glenn operation or partial cavopulmonary connection) around the age of 6 months and is followed by connection of the IVC to the pulmonary arteries (Fontan operation or total cavopulmonary connection) [2] at 2–3 years of age.

[†]Abhimanyu Agarwal, Marc Cribbs, Asmaa Naguib Ahmed and Mostafa Abozeed have contributed equally to this work.

*Correspondence:
Mostafa Abozeed
mostafaabozeed@uabmc.edu
[1] S. P. Medical College, Bikaner, Rajasthan 334001, India
[2] Department of Medicine, Division of Cardiovascular Disease, University of Alabama at Birmingham, Birmingham, AL 35233, USA
[3] Department of Radiology, University of Alabama at Birmingham, Birmingham, AL 35233, USA

Classic or atrio-pulmonary Fontan involves a direct connection of the right atrium to the main pulmonary artery. Modified Fontan utilizes a cavopulmonary anastomosis along with a lateral tunnel in the right atrium or extracardiac Gore-Tex tube to allow IVC flow to pass to the pulmonary arteries. This helps to minimize increasing atrial dilatation and accompanying problems, such as arrhythmias and thrombus formation. Fontan operation requires ideal physiologic and anatomical factors including normal pulmonary vascular resistance and adequately-sized pulmonary arteries [3].

## Case presentation

A 20-year-old female admitted with COVID, heart failure, AKI, transaminitis, and abdominal swelling, has a history of complex heterotaxy with polysplenia, interrupted IVC, and DORV with unbalanced AVSD, d-malposed great arteries, and pulmonary atresia most recently s/p Fontan using a 20 mm bifurcated and fenestrated Y-shaped Fontan, common AV valve repair, and RPA patch augmentation on 3/23/2015. Her history is also notable for sinus node dysfunction s/p dual-chamber pacemaker placement on 3/31/2015 and Fontan fenestration occlusion using an Amplatzer device.

Upon admission, initial evaluation demonstrated significant iron-deficiency anemia, particularly as it relates to a single ventricle patient with chronic desaturation, possible pacemaker-mediated tachycardia, moderate to severe AV valve regurgitation, and mild to moderate ventricular dysfunction.

Inpatient care and management of COVID were recommended and electrophysiology consultation was requested to ensure normal pacemaker function. Iron repletion and pRBCs with a goal Hb of 12 mg/dl, CXR, KUB, and Abdominal US were ordered.

Cardiac CTA revealed left-sided isomerism with bilateral left-sided bronchial anatomy and mild to moderately depressed univentricular (UV) systolic function (EF 40%). The SVC, which received venous drainage from an azygous continuation of the interrupted IVC, was seen to be baffled to the proximal RPA. Hepatic venous flow to both the RPA and LPA was accomplished through the Y-shaped extracardiac Fontan (Figs. 1, 2).

These connections were noted to be wide open without evidence of obstruction. Multiple venovenous collaterals were noted within the mediastinum.

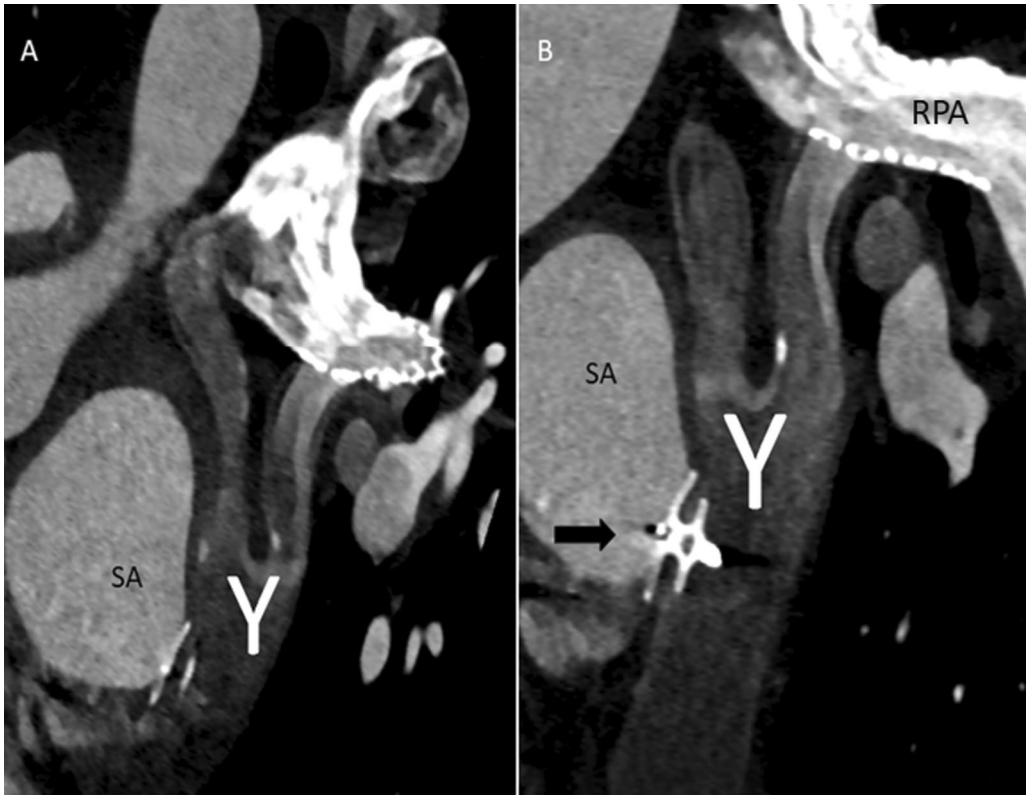


**Fig. 1** Cardiac CTA curved MPR demonstrate Y-type Gore-Tex Fontan graft (Y letter) which appears patent (**A** & **B**). Single atrium (SA) receives venous drainage from fenestration occlusive device (arrow) within Fontan graft. Patent RPA and stent (**B**)

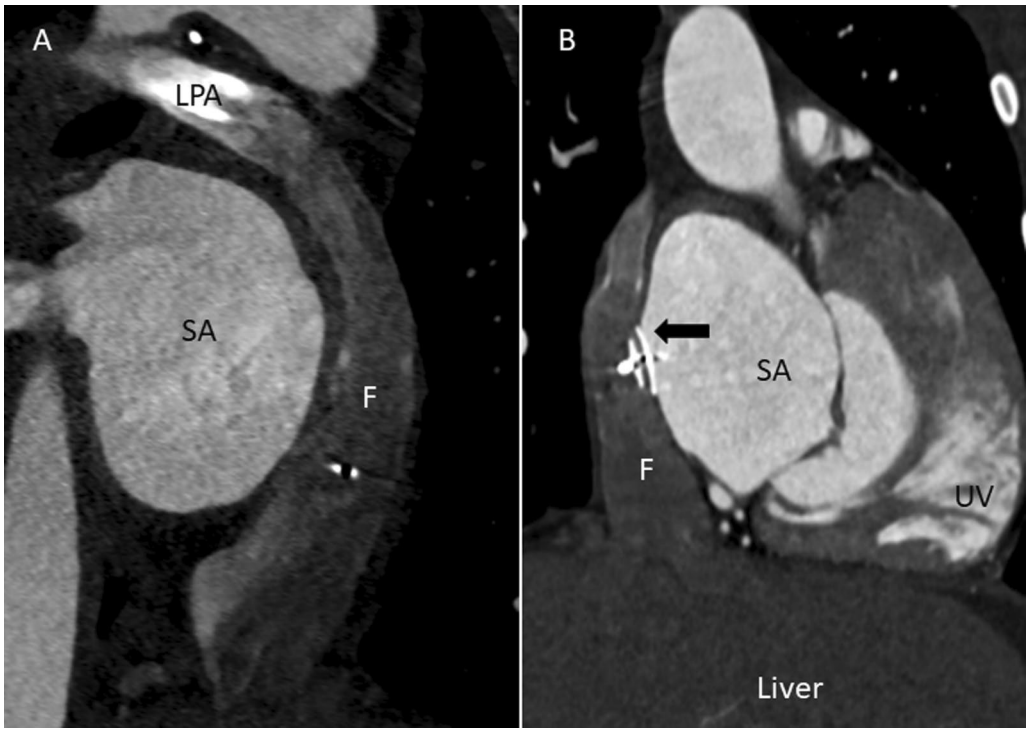


**Fig. 2** Cardiac CTA Curved MPR with (**A**) patent Fontan graft to LPA. (**B**) curved MPR with fenestration occlusive device (arrow) from Fontan to the single atrium (SA). F: Fontan graft. UV: univentricle

## Discussion

The unique concept of this case is the fenestrated Y-shaped Gore-Tex Fontan that redirects hepatic drainage to both the RPA and LPA. This unique approach has sparked interest among medical researchers who have been studying the various Fontan modifications that have been attempted in the past. Previous studies had suggested that there were no substantial differences in overall prognosis between different Fontan modifications. However, recent research [4] has shown that the Y-shaped graft may be more beneficial than previously thought.

One of the key long-term ramifications of a total cavopulmonary link, created during a Fontan procedure is the distribution of hepatic factors and total cavopulmonary resistance. The liver produces the precursors of angiotensin II and endostatin, which are respectively an agonist and antagonist of angiogenesis. In the normal cardiac system, the lungs are not exposed to high levels of angiotensin II. However, as per Hoffman's demonstration [5], lungs of single ventricle patients are exposed to high angiotensin II, which can lead to development of AVM in the lungs. Furthermore, Field-Ridley et al. [6] discovered that collagen XVIII, an endostatin precursor, is destroyed in the lungs. Because the pulmonary circulatory system suppresses endostatin production from collagen XVIII, collagen XVIII levels rise while endostatin levels fall in FSV patients, resulting in angiogenesis. AVMs can cause right-to-left shunting, which can be detrimental to a patient's health.

To prevent the development of AVMs, it is crucial to achieve bilateral pulmonary distribution of hepatic factors to both lungs. Achieving this balance is essential for the long-term success of single-ventricle palliation. Furthermore, the total cavopulmonary resistance within the Fontan pathway is of utmost importance. The pathway that has the lowest resistance will reduce energy loss and ultimately result in a better prognosis for the patient [7].

One of the risk factors for developing a pAVM is a congenital cardiac defect, such as left isomerism or exclusion of the hepatic vein blood flow to the pulmonary circulation. Additionally, even after a Fontan procedure has been performed, a pAVM can still develop if the hepatic flow is unevenly distributed. Therefore, it is essential to ensure that hepatic factors are distributed evenly to both lungs, and that the Fontan pathway has low resistance to prevent energy loss.

Kanter et al. [8], Haggerty et al. [9], and Yang et al. [10] have reported positive results with the Y-graft Fontan operation. Patients who underwent a Y-graft Fontan

revision had higher oxygen saturation at discharge, and asymmetric blood flow distribution was reduced. In addition, a quantitative simulation using CT and MRI showed positive hemodynamic results in patients who underwent a Y-graft Fontan operation. These findings suggest that the Y-shaped Gore-Tex Fontan is a promising technique that can lead to improved long-term outcomes for patients with a functional single ventricle.

According to Tobin et al.'s simulation experiment on T-shaped and three Y-shaped grafts [11], they discovered that the 12-mm Y-graft was the most energy-efficient. An 8-mm graft had reduced wall shear stress distribution, which suggests a lower risk of thrombosis and endothelial injury due to shorter residence duration. Furthermore, the 8 mm Y graft had a more even split of the pulmonary flow.

Ten children with single ventricle physiology were participating in an investigation by Javadi et al. [12] to explore the flow dynamics using a computational flow dynamics model. When compared to a traditional T graft, scientists discovered that a Y-shaped graft had much lower power loss and more evenly distributed hepatic flow.

Pre-surgical simulations carried out on 9 individuals in Lashkarinia et al.'s Y transplant fontan study [13] revealed that flow from the hepatic veins (HEP) was not reaching the target lung. The HEP flow to the target lung was dramatically increased by the innovative Y-graft template. Depending on how HEP is positioned in relation to the azygos direct shunt, the flow pattern can change, going from 38% in the caudally situated direct shunt to 3% in the cranial configuration with dramatically reversed flow. In a one-year follow-up, postoperative measures show that oxygen saturation rose significantly to normal levels.

## Conclusions

- The Y-shaped Gore-Tex Fontan technique, which is a novel idea, redirects hepatic drainage to both the right and left pulmonary arteries.
- Previous research has found no significant differences in overall prognosis between various Fontan modifications. Recent study, however, suggests that the Y-shaped graft may be more advantageous than previously assumed. It is critical for the long-term effectiveness of single-ventricle palliation and the prevention of AVMs to achieve bilateral pulmonary distribution of hepatic components to both lungs.
- The distribution of hepatic components and total cavopulmonary resistance is two of the most important long-term consequences of a total cavopulmonary connection generated after a Fontan surgery.
- By minimizing unequal blood flow distribution and boosting oxygen saturation at discharge, the Y-shaped Gore-Tex Fontan technique has demonstrated encouraging results in improving long-term prognosis for patients with a functioning single ventricle. More study is needed to properly comprehend the procedure's potential advantages.

**Abbreviations**

| | |
|---|---|
| SVC | Superior vena cava |
| DORV | Double-outlet right ventricle |
| AVSD | Atrio-ventricular septal defect |
| RPA | Right pulmonary artery |
| LPA | Left pulmonary artery |
| MPR | Multiplanar reconstructions |
| IVC | Inferior vena cava |
| AKI | Acute kidney injury |
| AV | Atrio-ventricular |
| RBC | Red blood cell |
| Hb | Hemoglobin |
| KUB | Kidney, ureter, bladder |
| US | Ultrasound |
| CXR | Chest X-ray |
| AVM | Arterio-venous malformation |
| FSV | Functional single ventricle |
| HEP | Hepatic veins |

**Acknowledgements**
No acknowledgements required.

**Authors' contributions**
All authors contributed equally to this work and all authors have read and approved the manuscript.

**Funding**
This study was not supported by any funding.

**Availability of data and materials**
Data sharing is not applicable to this article as no datasets were generated or analysed during the current study. As we don't do any analysis it is just a case report.

## Declarations

**Ethics approval and consent to participate**
All procedures performed in studies involving human participants were in accordance with the ethical standards of the institutional and/or national research committee and with the 1964 Helsinki declaration and its later amendments or comparable ethical standards. For this type of study participation consent is not required.

**Consent for publication**
For this type of study consent for publication is not required.

**Competing interests**
The authors declare that they have no competing interests.

Received: 21 April 2023 Accepted: 15 June 2023
Published online: 04 July 2023

**References**

1. Tyler BF, Tiffanie RJ, Mervyn DC (2011) The Fontan procedure: anatomy, complications, and manifestations of failure. Radiographics 31:453–463. https://doi.org/10.1148/rg.312105027
2. Ahmed AN, Abozeed M, Aziz MU, Singh SP (2021) Role of computed tomography in adult congenital heart disease. J Med Imaging Radiat Sci 52(3):S88–S109. https://doi.org/10.1016/j.jmir.2021.08.008
3. Rychik J, Atz AM, Celermajer DS, Deal BJ, Gatzoulis MA, Gewillig MH (2019) Evaluation and management of the child and adult with Fontan circulation: a scientific statement from the American Heart Association. Circulation. https://doi.org/10.1161/cir.0000000000000696
4. Trusty PM, Wei Z, Sales M, Kanter KR, Fogel MA, Yoganathan AP, Slesnick TC (2019) Y-graft modification to the Fontan procedure: Increasingly balanced flow over time. J Thorac Cardiovasc Surg 159(2):P652-661. https://doi.org/10.1016/j.jtcvs.2019.06.063
5. Hoffman JI (2013) Normal and abnormal pulmonary arteriovenous shunting: occurrence and mechanisms. Cardiol Young 23(5):629–641. https://doi.org/10.1017/S1047951113000140
6. Field-Ridley A, Heljasvaara R, Pihlajaniemi T, Adatia I, Sun C, Keller RL, Gong WH, Datar S, Oishi P, Fineman JR (2013) Endostatin, an inhibitor of angiogenesis, decreases after bidirectional superior cavopulmonary anastamosis. Pediatr Cardiol 34(2):291–295. https://doi.org/10.1007/s00246-012-0441-2
7. Ming-Sing Si MD, Sood MDM, Bove MDE (2020) Commentary: why use the Y-graft? J Thorac Cardiovasc Surg 159(2):662–664. https://doi.org/10.1016/j.jtcvs.2019.08.054
8. Kanter KR, Haggerty CM, Restrepo M, de Zelicourt DA, Rossignac J, Parks WJ, Yoganathan AP (2012) Preliminary clinical experience with a bifurcated Y-graft Fontan procedure—a feasibility study. J Thorac Cardiovasc Surg 144(2):383–389. https://doi.org/10.1016/j.jtcvs.2012.05.015
9. Haggerty CM, Kanter KR, Restrepo M, de Zélicourt DA, Parks WJ, Rossignac J, Fogel MA, Yoganathan AP (2013) Simulating hemodynamics of the Fontan Y-graft based on patient-specific in vivo connections. J Thorac Cardiovasc Surg 145(3):663–670. https://doi.org/10.1016/j.jtcvs.2012.03.076
10. Yang W, Chan FP, Reddy VM, Marsden AL, Feinstein JA (2015) Flow simulations and validation for the first cohort of patients undergoing the Y-graft Fontan procedure. J Thorac Cardiovasc Surg 149(1):247–255. https://doi.org/10.1016/j.jtcvs.2014.08.069
11. Tobin N, Good BC, Plasencia JD, Fogel MA, Weiss WJ, Manning KB (2022) Computational Investigation of Anastomosis Options of a Right-Heart Pump to Patient Specific Pulmonary Arteries. Ann Biomed Eng 50(8):929–940. https://doi.org/10.1007/s10439-022-02969-2
12. Javadi E, Laudenschlager S, Kheyfets V, Di Maria M, Stone M, Jamali S, Powell AJ, Moghari MH (2022) Predicting hemodynamic performance of Fontan operation for Glenn physiology using computational fluid dynamics: ten patient-specific cases. J Clin Images Med Case Rep 3(6):1916. https://doi.org/10.52768/2766-7820/1916
13. Lashkarinia SS, Cicek M, Kose B, Rezaeimoghaddam M, Yılmaz EH, Aydemir NA, Rasooli R, Ozkok S, Yurtseven N, Erdem H, Pekkan K, Sasmazel A (2022) A novel Fontan Y-graft for interrupted inferior vena cava and azygos continuation. Interact Cardiovasc Thorac Surg 34(6):1095–1105. https://doi.org/10.1093/icvts/ivac001

## Publisher's Note