Mansour *et al. Egypt J Radiol Nucl Med* (2023) 54:122
https://doi.org/10.1186/s43055-023-01063-4

Egyptian Journal of Radiology and Nuclear Medicine

RESEARCH

Open Access

Imaging of HER2 detected receptor expression positive breast cancer: from detection to interpretation

Sahar Mansour[1,2*], Engy Abdullah[2], Eman Hosny Mohamed[2] and Mohammed Mohammed Mohammed Gomaa[2,3]

Abstract

Background Aggressive invasion, high recurrence rate, and poor prognosis are common features of the human epidermal growth factor receptor-2 (HER2)-enriched breast cancer, yet on the other side, it shows significantly reduced activity in response to therapy. We aimed to find combinations of features at imaging modalities that could predict breast cancer HER2-enriched molecular subtype in a sample of screening and symptomatic patients.

Methods The study is a retrospective analysis including breast lesions proved to be cancer with HER2 detected receptor expression positive ($n = 346$) whether pure or expressed with other receptors (i.e., luminal B subtype). All carcinomas were examined by digital mammography and high-resolution breast ultrasound. Some cases ($n = 148$, 48.5%) were considered for further evaluation by contrast enhanced mammography or dynamic post-contrast MR imaging ($n = 116$, 33.5%) in case there was a diagnosis debate and/or a precise estimation of cancer multiplicity is needed.

Results Six features were suggestive of HER-enriched carcinoma on mammogram and/or ultrasound; (1) irregular shape mass, (2) indistinct margin, (3) associate fine pleomorphic microcalcifications, (4) asymmetry of global distribution, (5) hypoechoic pattern on ultrasound and (6) enlarged pathological nodes. There was a significant correlation between HER2-enriched subtype and presence of fine pleomorphic calcifications ($p = < 0.02$) of segmental distribution ($p = < 0.002$) and asymmetry of global distribution ($p = < 0.001$).

Contrast-based studies' dominant feature was the non-mass appearance of regional/diffuse distribution. Medium initial contrast uptake and wash out fate were the common curve pattern ($p = < 0.001$).

Conclusions Luminal B and HER2 enriched are both HER 2 overexpression breast cancer subtypes, yet there are certain key features more specific for HER2 enriched subtype in conventional and contrast-based imaging. Knowledge of such features could help interpretation and differentiation between HER2 positive subtypes to benefit from the early stratification of management and aid the therapeutic decisions in case receptor testing is not readily available.

Keywords Breast cancer, Cancer subtypes, HER-enriched, Luminal B, Breast imaging, Indistinct masses, Non-mass enhancement, Microcalcifications

*Correspondence:
Sahar Mansour
sahar_mnsr@yahoo.com
Full list of author information is available at the end of the article

Background

Recent studies have been concerned with breast cancer and the use of imaging as an adjunct in the preliminary diagnosis of the molecular subtypes of breast cancer molecular subtypes [1].

HER2-positive disease has a very aggressive clinical behavior, and nowadays, it has been considered as a single breast cancer subtype and treated accordingly, particularly in case of early presentation of breast cancer [2].

HER2-enriched appears to be associated with higher pathological complete response rates following anti-HER2-based regimens [3].

Several imaging features relate to HER2 overexpression, which may correlate with the cancer behavior and thus, improve breast cancer prognostication beyond non-specific features such as the cancer size for instant [4].

Enhancement of the performance of radiology is required since it could be used as a noninvasive less resource-intensive method for prediction of breast cancer subtypes. Radiologic imaging could be used as an adjunct to genetic profiling and so can assist in pre-treatment planning [5].

Most studies concerned with breast cancer subtypes have focused on triple negative and HER2-enriched subtypes as they represent a poor prognosis. However, the luminal B cancer (HER2 positive) has not been thoroughly investigated although it has a higher proportion of local recurrence and bone metastasis than the non-luminal groups [6].

In the current work, we studied the various descriptors of HER2 positive cancers—luminal B and HER2enriched—through conventional and contrast-based breast imaging modalities (digital mammogram, ultrasound, contrast enhanced mammogram, MR imaging) to settle the predictive features of these aggressive breast cancer subtypes that could establish tailored and effective therapy options for the screening and diagnostic breast cancer's populations.

Methods

Patient selection criteria

The study was a retrospective analysis that had been approved by the ethical committee of the Radiology department, and a waiver of the informed consent was applied for all the included patients. Included lesions were proved breast cancer of HER2 detected receptor expression positive whether pure or expressed with other receptors (i.e., luminal B subtype; estrogen positive, progesterone positive and HER positive).

Total included carcinomas with positive HER2-receptor expression were 346 in number; out of them, 89 were pure HER2 subtype (i.e., HER2-enriched).

Exclusion criteria

- Luminal A and triple negative breast cancer subtypes that are characterized by negative HER2-receptor.
- Proved breast carcinoma with unavailable immunohistochemistry analysis.
- Proved benign pathologies.

All cases were examined by digital mammography supported by complementary high-resolution breast ultrasound. Further evaluations were considered either by contrast enhanced mammography ($n = 148$, 48.5%) or dynamic post-contrast MR imaging ($n = 116$, 33.5%) in case of: (i) diagnosis debate to confirm or exclude malignancy, (ii) and precise estimation of multicentricity and/or bilaterality.

The sample included consecutive patients with histologically proven HER2 positive breast carcinoma that were examined during the period from April 2021 to April 2022.

The age of the patients ranged from 40 to 73 years (mean age 43.89 ± 5.99).

All the included lesions were biopsied by 14 G needle for tissue diagnosis.

Equipment

- Digital mammogram with dual energy contrast enhanced mammography (CEM) unit (Senographe Prestina 3D, GE healthcare Full Field Digital Mammography machine, UK). Non-ionic iodinated contrast agent was used in the form of one-shot injection of 1.5 ml/kg body weight at the rate of 2–3 ml/s.

  The standard mammographic views were taken (cranio-caudal and mediolateral oblique views), then visualization of contrast uptake was achieved by subtracting low energy image form high energy ones so that leave only those areas with pooling contrast medium. At CEM, this subtraction image is called the recombination image. Reduction of the background parenchymal contrast uptake is required to increase the conspicuity of the enhancing breast abnormalities against the normally enhancing glandular tissue.
- Hand-held superficial ultrasound using a high-frequency linear probe 7–12 MHz (Samsung RS85 and Cannon I700 ultrasound machines).
- MR imaging was performed by 1.5 Tesla scanner (Siemens machine Magnetom Aera, Siemens Medical Systems, Erlangen, Germany). Patients were

scanned in the prone position by a double-dedicated breast coil. Acquisition was done using axial T2- and T2 fat suppression weighted fast spin echo, dynamic post contrast sequence over 8 min duration.

Image analysis and interpretation

According to the BI-RADS lexicon [7], breast lesions were described differently by each modality.

Mammographic abnormalities were categorized into masses (descriptors: shape, margin, density) calcifications (descriptors: shape, distribution), distortion and asymmetries (descriptors: developing, focal and global).

At ultrasound breast abnormalities (descriptors: shape, margin, and texture) and lymph nodes (descriptors: size, shape cortical thickness and state of fatty hilum) features were evaluated.

MR Imaging presented breast abnormalities as mass (descriptors: shape, margin, and internal enhancement) and non-mass (descriptors: distribution and enhancement) and kinetics curves (types: progressively rising, plateau and early wash out).

Contrast enhanced abnormalities were divided into three categories: (I) "No enhancement" for lesions noted at low energy images and showed no contrast uptake and so termed "negative" and was described according to the BI-RADS ACR atlas for contrast enhanced mammography (A supplement to ACR BI-RADS mammography 2013) [8]. (II) Lesions presented as enhancement on subtracted contrast images only were described as mass (descriptors: shape, margin, and internal enhancement), non-mass enhancement (descriptors: distribution and internal enhancement). Lesion conspicuity (lesion enhancement relative to background) which was described as low, moderate, or high (subjective). (III) For masses detected at the low energy images and showed contrast uptake in the subtracted contrast images; the extent of enhancement was added to the CEM descriptors in their analysis which included: 1. partial enhancement, 2. complete enhancement, 3. presence of enhancement beyond the mammographic lesion, 4. enhancement of the surrounding tissue adjacent to the lesion.

All included imaging modalities (mammogram, ultrasound, contrast enhanced mammography and MR imaging) were reviewed retrospectively, and diagnosis made in consensus by two radiologists (with 25 years and 20 years of experience in breast imaging),

Statistical analysis

Nominal Data were expressed as frequency and relative frequencies (percentage). Mammography, ultrasound, contrast mammography and MR imaging descriptive results were correlated using the Pearson Chi-Square. Probability values (p-value) less than 0.05 were considered significant.

Results

The current work included 344 females; two of them presented with bilateral carcinoma ($n=346$ carcinomas); 89 (25.7%) were HER-enriched, and 257 (74.3%) were luminal B subtypes. One-Hundred-one (29.4%) cases were detected via breast screening, while 243 (70.6%) were referred clinically for diagnostic mammogram.

Positive family history was not known in 43.7% of the cases, confirmed in 4.5% of the cases and negative in 51.8% cases.

The history of contraceptive pills administration was found in only 14.8% ($n=51$).

The low breast density (ACR a and b) was the more common category on mammogram, and it had been noted in 64.0% of the HER2-enriched ($n=57/89$) and

Table 1 Mammographic features of HER subtype (pure and luminal B) of breast cancer

Mammography features		Luminal B, $n=222/257$		HER2-enriched, $n=56/89$	
		Count	*N* %	Count	*N* %
Mass, $n=278$					
Shape	Round/oval	191	68.7	4	1.4
	Irregular	31	11.2	52	18.7
Margin	Lobulated	28	10.1	8	2.9
	Speculated	121	43.5	10	3.6
	Indistinct	73	26.3	38	13.6
Density	Equal	54	19.4	6	2.2
	High	168	60.4	50	18
Associate calcifications, $n=77$					
Shape	Amorphous	33	42.8	3	3.9
	Coarse	13	16.9	6	7.8
	Fine pleomorphic	7	9.1	15	19.5
Distribution	Segmental	20	26	15	19.5
	Linear	5	6.5	2	2.6
	Regional	2	2.6	3	3.9
	Diffuse	18	23.3	12	15.6
Asymmetries, $n=68$					
Distortion, $n=28$		27	96.4	1	3.6
Distribution	Developing	4	2.2	2	0.0
	Focal	23	32.6	7	8.2
	Global	8	28.5	24	28.5

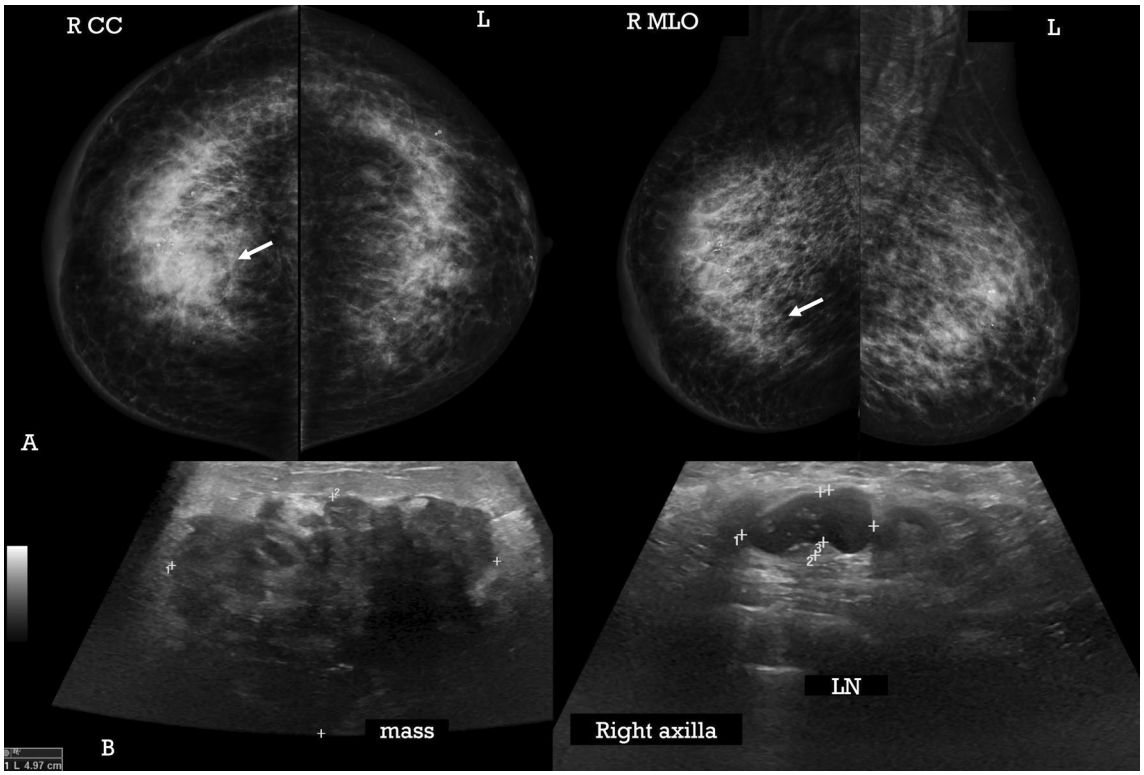

Fig. 1 Right breast HER2 enriched subtype breast carcinoma in a 56- year-old female presented with right breast lower inner palpable lump. **A** Bilateral digital mammogram that showed right breast lower inner indistinct mass (arrow), associated inflammatory changes in the form of coarsened trabeculae and diffuse dermal thickening. **B** Breast ultrasound, left image showed solid irregular mass of the right breast that measured 5 cm in max. dimensions. The right axillary nodes were pathologically looking at the right image seen displaying asymmetrical cortical thickening of 0.8 cm and eccentric fatty hilum

in 68.5% of the luminal B ($n=176/257$) carcinoma subtypes.

Mammography (Table 1)

The dominant morphology descriptors for mass were irregular shape (58.4%, $n=52/89$), indistinct margin (42.7%, $n=38/89$) for HER2-enriched (Fig. 1), while rounded/oval shape (74.3%, $n=191/257$) and spiculated margin (47.1%, $n=121/257$) for luminal B. High density went with both types (HER2-enriched, 56.2%, $n=50/89$ and luminal B, 65.4%, $n=168/257$).

Asymmetries was the presenting feature for 13.6% of luminal B, ($n=35/257$) and 37.1% of the HER2-enriched, ($n=33/89$) (Fig. 2). Associate distortion was noted in 10.5% of luminal B, ($n=27/257$) and in 1.1% of the HER2-enriched, ($n=1/89$).

Calcifications presented in 22.2%, $n=77/346$; detected in association with other features such as mass, distortion, or asymmetry. The commonest morphology was the amorphous pattern in 43% of luminal B ($n=33/77$) and fine pleomorphic in 19.5% of HER2-enriched ($n=15/77$). Segmental distribution was the highest percentage shown in 26% of luminal B ($n=20/77$) and 19.5% of HER2-enriched ($n=15/77$) subtypes (Figs. 1 and 3).

There was a significant correlation between HER2-enriched subtype and presence of fine pleomorphic calcifications ($p=<0.02$) of segmental distribution ($p=<0.002$) and asymmetry of global distribution ($p=<0.001$).

Ultrasound (Table 2)

The commonest features for HER cancer subtypes masses were the irregular shape (21.7%, $n=75/89$), and indistinct margin (14.2%, $n=49/89$) in HER2-enriched (Figs. 1 and 2) while the rounded /oval shape (69.7%, $n=241/257$) and spiculated margin (31.8%, $n=110/257$) were in luminal B subtype (Fig. 3).

Lesions showed dominant hypoechoic texture (luminal B in 68%, $n=235$ and HER2-enriched in 15%, $n=52$).

The associate lymphadenopathy was commonly showing enlarged size (luminal B in 49.4%, $n=171$ and HER2-enriched in 20.5%, $n=71$), pathological of rounded

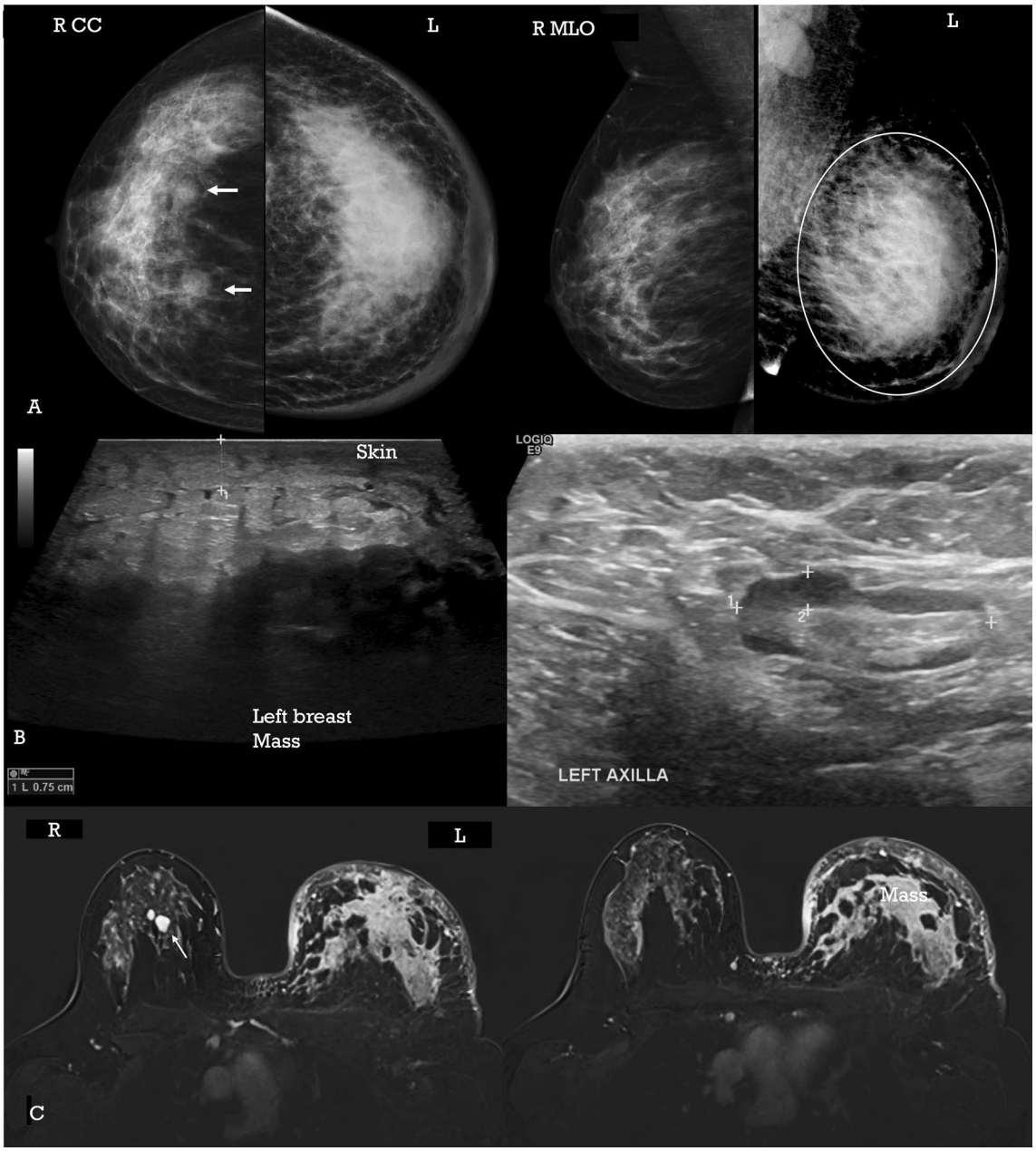

Fig. 2 This is a 47-year-old female presented with left breast erythema and peau d'orange of 6 months duration proved to be HER2 enriched subtype breast carcinoma. **A** Right breast deeply seated masses of partly obscured margins (arrows). Left breast global/diffuse asymmetry (circle), marked coarsened trabeculation, nipple retraction and diffuse dermal thickening seen on digital mammogram; note the left axillary enlarged nodes obvious at the mediolateral oblique view. **B** Breast ultrasound, the left image showed infiltrative solid mass of the left breast measured 11 cm in max. length and indeterminate ipsilateral axillary nodes, that showed asymmetrical uniform cortical thickening of 0.3 cm, yet with preserved central fatty hilum. **C** Subtraction post-contrast MR imaging showed the right breast masses with evident benign features of oval shape, circumscribed border, and homogenous contrast uptake (arrow). A full demonstration of the left breast disease was presented by a locally advanced breast carcinoma in the form of diffuse soft tissue infiltration (mass). Concomitant markedly thickened skin which is less enhancing than the breast carcinoma suggesting eczematous inflammatory changes rather than dermal infiltration as confirmed by mastectomy

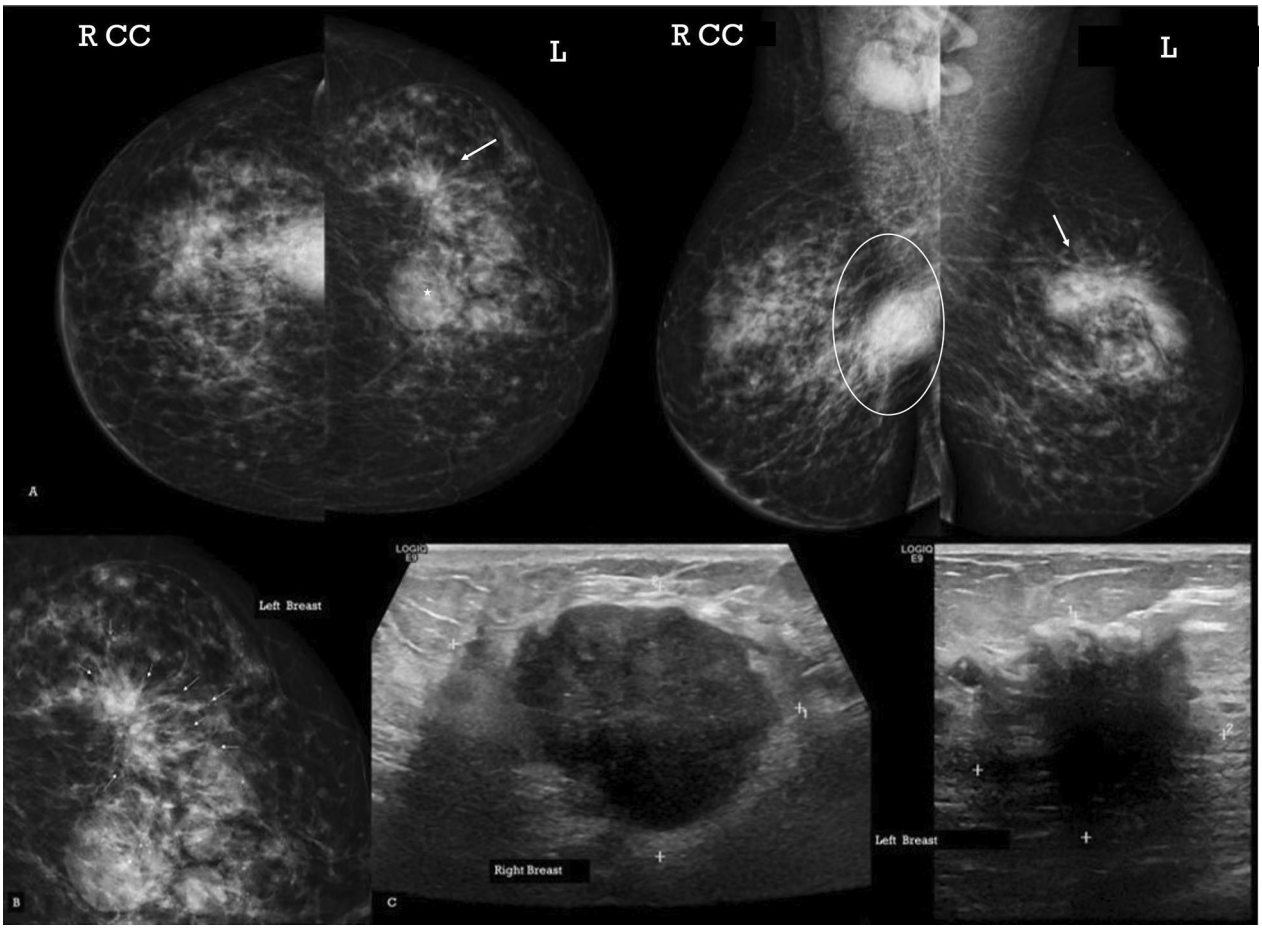

Fig. 3 A 73-year-old female presented with bilateral breast lumps found to be bilateral breast carcinoma, right HER2 enriched and left luminal B subtypes. **A** Bilateral digital mammogram showed upper outer deeply seated right breast mass (circle. The left breast showed upper outer indistinct mass (arrow) and multicenter grouped calcifications. Note, deeply seated lobulated mass (star) found to be cyst on ultrasound. **B** The left side showed upper outer segmental and lower inner focal grouped amorphous microcalcifications (arrows). **C** Breast ultrasound, left image showed round-shaped indistinct solid mass max. length 5 cm and right image showed irregular-shaped spiculated solid mass of the left breast of max. dimension 3.5 cm

appearance (luminal B in 56.3%, $n=195$ and HER2-enriched in 21.7%, $n=75$), effaced hilum (luminal B in 56.3%, $n=195$ and HER2-enriched in 21.7%, $n=75$) and diffuse cortical thickening (luminal B in 48.8%, $n=169$ and HER2-enriched in 19.4%, $n=67$).

There was a significant correlation between HER2-enriched subtype and indistinct margin of detected abnormalities on the ultrasound imaging ($p=<0.001$).

All the included cases that performed contrast-based study whether by using contrast enhanced mammogram or MR imaging (264/346, 76%) showed contrast uptake of the presented breast cancer (48.5% on contrast enhanced mammogram and 33.5% on MR imaging).

Contrast enhanced mammography (Table 3)

HER2 cancers demonstrated non-mass enhancement in 92 lesions (62%) more often than mass lesions ($n=56$, 38%). The distribution in luminal B was mainly segmental ($n=43/92$, 46.7%), linear ($n=18/92$, 19.6%) while was regional ($n=14/92$, 15.2%) in HER2-enriched (Fig. 4). Mass enhancement was seen in 38% ($n=56/148$) of HER2 subtype carcinoma; irregular shape noted in HER2-enriched (24.5%, $n=14/55$), while luminal B showed rounded/oval shape (25.8%, $n=24/93$). Both showed an indistinct margin that was seen in 66% ($n=37/56$).

Heterogeneous/rim enhancement was most seen in Her2 enriched 28.6%, $n=16/56$) and both subtypes displayed mainly complete enhancement, which was 66.1% in luminal B and 21.4% in HER2 enriched.

MR imaging (Table 4)

The non-mass was the dominant pattern presented in 53% ($n=65/116$) of HER2 enriched cancers (Fig. 2).

Table 2 Ultrasound features of HER subtype (pure and luminal B) of breast cancer

Ultrasound features, $n = 346$	Luminal B, $n = 257$		HER2-enriched, $n = 89$	
	Count	Row *N* %	Count	Row *N* %
Shape				
Round/oval	241	69.7	14	4.0
Irregular	16	4.6	75	21.7
Margin				
Angular	87	25.1	21	6.1
Speculated	110	31.8	15	4.3
Indistinct	14	4.0	49	14.2
Lobulated	46	13.3	4	1.2
Texture				
Hypoechoic	235	68	52	15
Heterogeneous	22	6.3	37	10.7
Lymph nodes				
Shape				
Preserved	86	24.9	18	5.2
Rounded	171	49.4	71	20.5
Fatty Hilum				
Preserved	62	18	14	4.0
Effaced	195	56.3	75	21.7
Cortical thickening				
None	2	0.6	–	0.0
Diffuse	169	48.8	67	19.4
Focal	86	24.9	22	6.3
Size				
Normal	100	29	21	6.1
Enlarged	157	45.4	68	19.6

Distribution pattern was mainly segmental ($n = 33/42$, 51%) in luminal B and diffuse ($n = 13/23$, 56.5%) in HER2 enriched. The common kinetic pattern for HER2- breast cancers was the medium initial phase (59%) and the washout fate pattern (75%).

Medium initial peak of contrast uptake and wash out curve pattern was significantly correlated with the diagnoses of HER2-enriched subtype ($p = < 0.001$).

The minimal-mild pattern of background contrast uptake was the most common among both types of HER2 groups (73.1% luminal B and 87.3% HER2-enriched at contrast enhanced mammography and 77% luminal B and 50% HER2-enriched at MR imaging).

Large tumor size (> 2 cm) was one of the common features of HER2-enriched (60% for HER-enriched versus 40% for luminal B) as reported by the complete pathology specimen.

The size of the cancers detected on screening mammograms was smaller (mean size, 1.55 cm vs. 4.4 cm; $P = 0.01$) than those detected on diagnostic ones.

Discussion

Breast cancer presents different patterns of invasion progression and distribution that are influenced by the biological behavior, affecting the morphology of the tumor on the different breast imaging modalities whether they were conventional, or contrast based.

HER2-enriched-specific imaging can help in the screening of the appropriate patients for HER2-targeted therapies [9].

Previous work studied the different breast cancer subtypes and stated correlation between them, yet the HER2 overexpression carcinoma has not been the focus of concern, although HER2-positive breast cancer presents a big challenge in the upcoming years with regard individualization of the anti-HER2 therapy to achieve optimal utilization of the possible options of treatment. This work reports the imaging features of human epidermal growth factor receptor type 2 (HER2) overexpression carcinomas which is considered as a marker of breast cancer aggressiveness to help in the choice of management therapy and pre-therapy suggested imaging-guided interventional procedures as clip insertion and wire localization.

Analysis revealed six features on mammogram and/or ultrasound suggestive of HER-enriched carcinoma; (1) irregular shape mas, (2) indistinct margin, (3) associate fine pleomorphic microcalcifications, (4) asymmetry of global distribution, (5) hypoechoic pattern on ultrasound and (6) enlarged pathological nodes.

The presence of micro-calcifications in conjunction of HER-enriched tumors was justified by the concept that the central necrosis and rapid growth of poorly differentiated tumors result in ductal distribution of calcium deposition which is an indicator of the aggressive behavior invasive cancers and rather explain the rapid kinetics of these tumors [10].

Luminal B cancers display a desmoplastic reaction result into spiculated margin of these tumors on breast imaging [11]. The more cellular are the tumors; the rapidly they grow and the less expected it is to demonstrate a desmoplastic reaction from the surrounding healthy breast tissue [12]. So, the margin of the detected breast carcinomas may favor aggressive subtypes as HER enriched over than luminal B tumors.

Nie et al. [13] found that large tumor size (more than 2 cm), non-spiculated mass and associated extensive calcification for more than 2 cm are features that can potentially be used to predict breast cancer HER2-enriched subtype before surgery.

The current work presented masses more than 2 cm in size at 60% of the HER-enriched subtypes that were found at the surgical specimen.

On ultrasound, pathological lymphadenopathy of malignant pattern was noted in luminal B (56.3%), while

Table 3 The contrast enhanced mammogram morphology descriptors and contrast uptake features in the study

Descriptors	Luminal B, *n* = 93/257		HER2-enriched, *n* = 55/89		Total (*n* = 148/346)
	Count	*N*%	Count	*N*%	
Mass (*n* = 77, 52%)					
Shape					
Rounded/oval	24	42.8	5	9.0	29
Irregular	13	23.2	14	25.0	27
Margin					
Circumscribed	4	7.1	3	5.4	15
Indistinct	12	21.4	16	28.6	37
Spiculated	21	37.5	–	–	4
Internal enhancement					
Homogenous	28	50.0	3	5.4	31
Heterogeneous/rim	9	16.0	16	28.6	25
Extend of enhancement					
Partial enhancement	–	–	1	1.8%	1
Complete enhancement	37	66.1	12	21.4%	49
Enhancement beyond the lesion	–	–	2	3.6%	2
Enhancement of the surrounding tissue	–	–	4	7.1%	4
Non-mass (*n* = 71, 48%)					
Distribution					
Focal	10	10.9	1	1.1	11
Linear	3	3.3	18	19.56	21
Segmental	43	46.7	3	3.3	46
Regional	–	–	14	15.2	14
Enhancement					
Yes	44	100	48	100	92
No	–	–	–	–	–

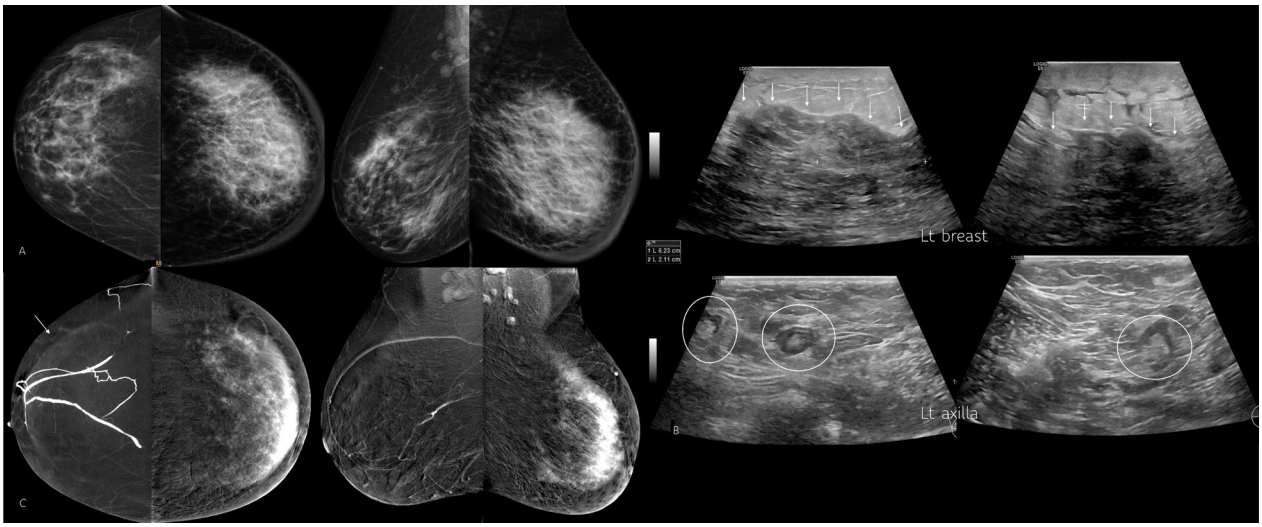

Fig. 4 A 62-year-old female presented with left breast rapid increase in size, edema, erythema and peau d'orange. Locally advanced breast carcinoma HER2 enriched subtype. **A** Digital mammogram showed left breast diffuse asymmetry and marked edematous changes. **B** Ultrasound images showed indistinct tissue infiltration and liquefaction of the left breast (arrows upper row). The left axilla showed indeterminate nodes which were reactionary presented average size, uniform cortical thickening less than or equal to 0.3 cm and preserved fatty hilum (circles at lower row). **C** Heterogeneous complete enhancement of left breast regional non-mass at contrast enhanced mammogram that confirmed the whole extent of the disease. Note, right breast upper outer background contrast uptake (arrow)

Table 4 The MR morphology descriptors and contrast uptake features in the study

Descriptors	Luminal B, *n* = 82/257		HER2-enriched, *n* = 34/89		Total (*n* = 116/346)
	Count	*N*%	Count	*N*%	
Mass (*n* = 51, 44%)					
Shape					
Rounded/oval	12	30	8	72.7	20
Irregular	28	70	3	27.3	31
Margin					
Indistinct	19	47.5	8	72.7	29
Spiculated	21	52.5	3	27.3	22
Internal enhancement					
Homogenous	13	32.5	8	72.7	21
Heterogeneous/rim	27	67.5	3	27.3	30
Non-mass (*n* = 65, 56%)					
Distribution					
Diffuse	–	–	13	56.5	13
Segmental	33	78.6	4	17.4	37
Regional	9	21.4	6	26.1	15
Enhancement					
Yes	44	100	48	100	92
No	–	–	–	–	–
Kinetics curve					
Initial phase					
Fast	25	30.4	9	26.5	34
Medium	51	62.2	17	50	68
Slow	6	7.4	8	23.5	14
Fate					
Wash out	70	85.4	17	50	87
Plateau	4	4.9	9	26.5	13
Progressive	8	9.7	8	23.5	16

reactionary looking, or non-specific axillary nodes were the common pattern for the HER2 enriched subtype (21.7%).

Bilateral breast carcinoma is a rare condition especially if the condition was synchronous. The positive family history of breast cancer, negative estrogen receptor expression, and HER2-positive carcinomas are factors associated with the occurrence of contralateral malignancy. The current work included two cases presented by bilateral carcinoma (Fig. 3). It was believed that whether synchronous or metachronous, both cancers often belong to the same histology. Risk assessment of such condition and close monitoring are required [14].

It was believed that HER2-breast carcinomas were considered as a single entity especially at the early stages. Yet, updated data demonstrated rates of different response to neoadjuvant therapy for hormone-receptor negative versus those-receptor positive tumors and consequently imaging experience and monitoring early response to therapy eliminates the chance of improper or over-treatment. Pathological complete response is strongly correlated with the HER2-enriched [15].

A recent study in 2022 confirmed that segmental distribution, clustered-ring enhancement, wash-out dynamic curve were associated with HER2 enriched subtype on MR imaging [16]. The imaging features of contrast enhanced mammogram could contribute to distinguishing breast cancer molecular subtypes; non-mass enhancement pattern that noted at the high energy images ± extensive calcification at the low energy images were suggestive of the HER2-enriched subtype of breast cancers [17].

At the current work, features at contrast-based studies included non-mass appearance of regional/diffuse distribution in the contrast enhanced mammogram or MR imaging, respectively. Medium initial contrast uptake and wash out fate were the common features of kinetic curve patterns for HER 2 cancer subtypes.

The limitation of the study lay in being a retrospective analysis conducted at a single institute, so could be subjected to selection bias. However, the selected cases were consecutive patients within a certain period and the readers were blinded about the histology results.

Conclusions

Although luminal B and HER2 enriched are HER 2 overexpression breast cancer subtypes, there are certain key features more specific with HER2 enriched subtype in conventional and contrast-based imaging. Knowledge of such features could help interpretation and differentiation between HER2 positive subtypes to benefit from the early stratification of management and aid the therapeutic decisions in case receptor testing is not readily available.

Abbreviations

HER2	Human epidermal growth factor receptor 2
BI-RADS	Breast Imaging Reading and Data System
ACR	American College of Radiology
CEM	Contrast enhanced mammography
CC	Cranio-caudal view
MLO	Medio-lateral oblique view

Acknowledgements

Not applicable.

Author contributions

SM is the guarantor of integrity of the entire study. MMMGand SM contributed to the study concepts and design. SM, EHM, and EA contributed to the literature research. SM, MMMG, EA and EHM contributed to the clinical studies. SM and MMMG contributed to the experimental studies/data analysis. SM, EA and EHM contributed to the statistical analysis. SM, EA, and EHM contributed to the manuscript preparation. SM, MMMG, EA, and EHM contributed to the manuscript editing. All authors have read and approved the final manuscript.

Funding
No source of funding.

Availability of data and materials
The corresponding author is responsible for sending the used data and materials upon request.

Declarations

Ethics approval and consent to participate
The study was approved by the ethical committee of the Radiology Department of Baheya foundation of early breast cancer detection and treatment which is non-profitable and non-governmental highly specialized multidisciplinary breast focused organization. A waiver of informed consent was obtained.

Committee's reference number
202111290040.

Consent for publication
All patients included in this research were legible, above 16 years of age. The study was waived to get written informed consent from the included patients.

Competing interests
The authors declare that they have no competing interests.

Author details
[1]Women's Imaging Unit, Radiology Department, Kasr ElAiny Hospital, Cairo University, Cairo, Egypt. [2]Baheya Foundation for Early Breast Cancer Detection and Treatment, ElAhram, Cairo, Egypt. [3]National Cancer Institute, Cairo University, Manial, Cairo, Egypt.

Received: 26 May 2023 Accepted: 24 June 2023
Published online: 14 July 2023

References

1. Ian TWM, Tan EY, Chotai N (2021) Role of mammogram and ultrasound imaging in predicting breast cancer subtypes in screening and symptomatic patients. World J Clin Oncol 12(9):808–822
2. Harbeck N (2015) Insights into biology of luminal HER2 vs. enriched HER2 subtypes: therapeutic implications. Breast 24(2):S44-48
3. Schettini F, Pascual T, Conte B et al (2020) HER2-enriched subtype and pathological complete response in HER2-positive breast cancer: a systematic review and meta-analysis. Cancer Treat Rev 84:101965
4. Elias SG, Adams A, Wisner DJ et al (2014) Imaging features of HER2 overexpression in breast cancer: a systematic review and meta-analysis. Cancer Epidemiol Biomarkers Prev 23(8):1464–1483
5. Rashmi S, Kamala S, Murthy SS et al (2018) Predicting the molecular subtype of breast cancer based on mammography and ultrasound findings. Indian J Radiol Imaging 28:354–361
6. Dayan D, Ernst K, Aktas B et al (2022) Resemblance of the recurrence patterns in primary systemic, primary surgery and secondary oncoplastic surgery. Curr Oncol 29(11):8874–8885
7. D'Orsi CJ, Sickles EA, Mendelson EB et al (2013) ACR BI-RADS® Atlas, the fifth edition, Breast imaging reporting and data system. American College of Radiology, Reston
8. Magny SJ, Shikhman R, Keppke AL (2023) Breast imaging reporting and data system [Updated 29 Aug 2022]. In: StatPearls. StatPearls Publishing, Treasure Island. PMID: 29083600
9. Du S, Luo C, Yang G et al (2020) Developing PEGylated reversed D-peptide as a novel HER2-targeted SPECT imaging probe for breast cancer detection. Bioconjug Chem 31(8):1971–1980
10. Karsch-Bluman A, Feiglin A, Arbib E et al (2019) Tissue necrosis and its role in cancer progression. Oncogene 38:1920–1935
11. Ramírez-Galvana YA, Uribe-Martinez MC, Ponce-Camacho MA et al (2022) Spiculated margin on ultrasound is associated with tumor grade and immunohistochemical profile in breast cancer. J Mex Fed Radiol Imaging 1(2):119–125
12. Robin X, Turck N, Hainard A et al (2011) pROC: an open-source package for R and S+ to analyze and compare ROC curves. BMC Bioinformatics 12:77
13. Nie Z, Wang J, Ji X (2021) Retracted: microcalcification-associated breast cancer: HER2-enriched molecular subtype is associated with mammographic features. Br J Radiol. https://doi.org/10.1259/bjr.20170942
14. Singla A, Kaur N, Walia DS et al (2018) Bilateral metachronous breast carcinoma: a rare case report. Int J Appl Basic Med Res 8(2):126–128
15. Kay C, Martínez-Pérez C, Meehan J et al (2021) Current trends in the treatment of HR+/HER2+ breast cancer. Future Oncol 17(13):1665–1681
16. Liu G, Li Y, Chen SL et al (2022) Non-mass enhancement breast lesions: MRI findings and associations with malignancy. Ann Transl Med 10(6):357
17. Wang S, Wang Z, Li R et al (2022) Association between quantitative and qualitative image features of contrast-enhanced mammography and molecular subtypes of breast cancer. Quant Imaging Med Surg 12(2):1270–1280

Publisher's Note