Ali *et al. Egypt J Radiol Nucl Med* (2023) 54:124
https://doi.org/10.1186/s43055-023-01067-0

Egyptian Journal of Radiology and Nuclear Medicine

RESEARCH

Open Access

Efficiency of whole-body positron emission tomography/computed tomography using ^{18}F-Fluorodeoxyglucose in detecting the cause of elevated cancer antigen 125 serum level in treated ovarian cancer patients

Susan Adil Ali[1*], Moustafa Mahmoud Abdelkawi[2], Darine Amin[3], Mohamed Metkees[3] and Samar Ramzy Ragheb[1]

Abstract

Background Ovarian cancer is one of the leading causes of death in females worldwide. Early diagnosis and accurate staging are mandatory for proper management. Anatomic imaging and serum cancer antigen 125 (CA 125) measurement have been widely used for follow up of treated ovarian cancer patients to detect residual or recurrent neoplasia. The aim of this study was to assess the value of whole-body positron emission tomography/computed tomography using ^{18}F-Fluorodeoxyglucose (^{18}F-FDG PET/CT) in follow up of ovarian cancer patients presented with elevated CA 125 serum level.

Results The current study was performed over a period of 2 years between March 2019 and March 2022. Seventy-six patients were included with history of treated ovarian cancer (underwent either surgical resection and/or received radio/chemotherapy) but were subsequently presented rising tumor marker CA-125 serum level (more than 35 U/ml). All patients underwent a ^{18}F-FDG PET/CT scanning on whole body. The FDG-PET results were correlated with histological findings, radiological or tumor marker/clinical follow-up. The patients with inconsistent findings were followed up with U/S, post contrast pelviabdominal CT, MRI or PET/CT 3–6 months later. The ^{18}FDG PET/CT scan was positive in 62 patients, and it was negative in 14 patients. Specificity, sensitivity, negative predictive value, as well as positive predictive value and diagnostic accuracy of integrated PET/CT, were found to be 92.3%, 96.3%, 96.1%, 85.7% and 98.4%, respectively.

Conclusions ^{18}F-FDG PET/CT is a valuable imaging tool for assessment of ovarian cancer patients presented with elevated CA-125 tumor marker serum level.

Keywords FDG PET/CT, Treated ovarian cancer, CA 125

*Correspondence:
Susan Adil Ali
dr.susanadil@hotmail.com
[1] Radiodiagnosis Department, Ain Shams University, Cairo, Egypt
[2] Radiodiagnosis Department, Helwan University, Cairo, Egypt
[3] Biological Anthropology Department, Medical Research Division, National Research center, Giza, Egypt

Background

Ovarian cancer is one of the leading causes of death in females worldwide and is the most fatal gynecologic malignancy due to its silent nature and delayed presentation in the course of the disease in the advanced stage [1–3]. It is also the fifth most common cause of mortality from cancer in women after bronchopulmonary,

colorectal, breast and pancreatic cancer. So, early diagnosis and accurate staging is mandatory for proper management and to improve the 5-year survival rate [4]. Also, anatomic imaging and serum cancer antigen 125 (CA 125) measurement have been widely used for follow up of ovarian cancer patients [5]. Therefore, improving diagnostic methods are needed for better estimation of tumor load, as well as residual or recurrent disease [6]. Positron emission tomography using ^{18}F-Fluorodeoxyglucose (^{18}F-FDG PET) is a diagnostic procedure which assesses the accumulation of radioactive glucose in cancer cells. Recently, PET has been widely used for the assessment of cancer and diagnosis of recurrence [7–9]. Integrated Positron emission tomography/computed tomography (PET/CT) is an emerging hybrid modality that has many advantages as it can differentiate pathologic from physiologic processes, increase lesion detection with accurate anatomical localization and survey the entire body [10].

Therefore, the goal of this study was to evaluate the potential role of ^{18}F-FDG PET/CT in follow up of ovarian cancer patients in a random sample of ovarian cancer Egyptian patients with rising tumor marker CA 125 serum level.

Methods

Patients

The study is prospective, conducted from March 2019 to March 2022 and included 76 female patients (> 18 years old) with history of treated ovarian cancer [histopathological subtypes: 56 serous papillary adenocarcinoma, 6 granulosa cell tumor, 4 carcinosarcoma, 10 clear cell adenocarcinoma], who underwent either surgical resection and/or received radio/chemotherapy), but were subsequently presented rising tumor marker CA125 serum level (more than 35 U/ml) after complete remission with negative contrast enhanced computer tomography (CE CT) or contrast enhanced magnetic resonance imaging (CE MRI). They all referred for combined ^{18}F-FDG PET/CT scanning [using routine Torso protocol from the skull base to mid-thighs]. Patients with history of another gynecological malignancy, bad general condition, high blood glucose level > 150 mg/dl, high serum creatinine > 2 mg/dl and patients known to have severe allergy to contrast material were excluded. The ^{18}F-FDG-PET results were correlated with histological findings, radiological or tumor marker/clinical follow-up. The patients with inconsistent findings were followed up with CT, MRI or PET/CT 3–6 months later. Lesions increasing in size with clinical evidence of progression were considered recurrent lesions even if a histological/cytological diagnosis was unavailable. This study was approved by the Institutional Review Board and written informed consent was obtained from each enrolled patient.

PET/CT acquisition and processing

Combined PET/CT scan using a hybrid PET/CT system (Philips® Ingenuity TF128 multi slice PET/CT scanner; USA) was performed for all patients. The rules of patient preparation were followed strictly. Complete fasting except for glucose-free hydration for about 6–8 h before the study and their blood glucose value was kept less than 150 mg/dl at the time of the tracer injection. The scan was performed 45–60 min after IV injection of 0.1 mCi of ^{18}F-FDG/kg adjusted according to patient's weight. To avoid physiologic muscle uptake of FDG, the patients were instructed to remain calm and avoid any intense exercise prior to the examination (for at least 24 h) and following the radiotracer administration. A warm environment with controlled temperature should be provided for the patients before the 18F-FDG injection to reduce brown fat uptake. The patients were advised to have a low carbohydrate, high fat, protein diet before the examination. The usual study was done with patient in supine position on the body from the skull base down to the mid thighs.

A PET emission scan with several bed positions (5–7 in number) was performed and each with approximately 15 cm axial field of view per bed position with 4 mm in-plane spatial resolution and was covering the same field of view of the CT. The time of acquisition emission data was about 2 min for each bed position and in time range between 13 and 17 min.

A diagnostic contrast-enhanced CT (CECT) transmission scan immediately after PET scanning covering the identical transverse field of view using the following parameters: 350 mA, 120 kV, 0.5 s tube rotation time, 5 mm slice thickness and 8-mm table feed. Incremental reconstruction about 3 mm. Iodinated non-ionic contrast agent (Omnipaque 350) was administrated IV (100 ml) using an injector, with an injection flow of 5 ml/s just before the beginning of the scan.

A Philips advanced workstation [IntelliSpace Portal] was used to view All CT, PET and PET/CT images and they were reconstructed in multi-planar reformation and viewed in different planes for all as well as "3D maximum intensity projection images (MIP)" PET images in a video mode.

Data analysis

A team including a nuclear medicine physician and a radiologist (of 10 and 15 years of experience) reviewed and interpreted the PET, CT and the fused PET/CT images and final diagnosis was reached by consensus. They were aware of the full patient's history and relevant clinical data. Reviewing older scans in some cases was done as well to correlate the recorded lesions. The results

were confirmed by biopsy or by other follow-up imaging modalities (e.g., post contrast pelviabdominal MRI) within 1 month of PET/CT study.

All active lesions both visually and with abnormally high FDG uptake that exceeded the physiological mediastinal and hepatic background activity (used as an internal references), were recorded, and accurately assessed quantitatively by the measurement of the "maximum standardized uptake value (SUV max)" using automated 3D VOI technique that was independently measured by using region of interest (ROI) drawn on the area of maximal metabolic activity for every lesion in PET images. Different lesions that were detected in the CT portion of study were evaluated and recorded, then each of the lesions in the fused images of PET/CT was evaluated. Histopathologic examination and imaging data of other follow up study were the standard of reference. A suspected lesion was considered as a true positive if the lesions were positive histologically or by other follow up imaging modality. Lesions were considered false positive when proved to be negative histologically or not verified on follow up study. When no abnormality was detected on FDG-PET/CT the result was considered to be a true-negative, if no disease was identified by other follow up imaging modalities, within 1 month of the FDG-PET/CT examination. A false negative lesion was considered when it was missed by the PET/CT study [due to small volume, mucinous or low-grade pathological types] and was positive histologically or detected on other follow-up imaging modality, within 1 month of the FDG-PET/CT examination.

Statistical analysis

All data were collected, tabulated and analyzed using SPSS 20.0 for windows (SPSS Inc., Chicago, IL, USA). Quantitative data were expressed as the mean ± SD and median (range). Percent of categorical variables were compared using ANOVA. All tests were two sided. P-value < 0.05 was considered statistically significant (S), and P-value ≥ 0.05 was considered statistically insignificant (NS).

Results

The included 76 female patients, were ranging in age between 38 and 78 years with a mean age of about 55 ± 6.8 years. The serum CA-125 levels were ranging between 10.4 and 510.2 U/ml, with a mean level of about 125.8 ± 117 U/ml (Table 1).

The sites of recurrence were 132 sites (Fig. 1); identified in the evaluated six regions (pelvic local recurrence, $n = 46$; peritoneum, $n = 35$; pelvic lymph nodes, $n = 16$; para-aortic lymph nodes, $n = 15$; distant lymph nodes, $n = 11$; and metastatic disease, $n = 9$).

Table 1 Demographic data of the studied patients

Patient number (n)	76
Age range	36–77
Mean age	55 ± 6.8
CA 125 level	10.4–510.2 U/ml
Mean level	125.8 ± 117 U/ml

The ^{18}FDG PET/CT scan was positive in 62/76 patients, and it was negative in 14/76 patients. 13/76 proved to be disease free during follow-up time (true negative), they were having normal CA-125 serum levels and there was no disease recurrence on any further imaging, while PET/CT missed recurrence in 2/14 patient (false negative), one of them due to small size of lesion which was detected in follow up imaging when it became larger enough to be identifiable and another one confirmed to be a mucinous histologic subtype. One patient of sixty-two patients (1/62) was (false positive) as the detected hypermetabolic nodes were just due to inflammation. The recurrence was confirmed in the (true positive) 61 cases histologically by biopsy or with second look surgery in 17/61, whereas 44/61 were confirmed on clinical/radiological follow up (ranging from 3 to 6 months) or by response to chemotherapy on subsequent imaging.

As regard detection at regional level, six regions were identified (Table 2, Fig. 2); local recurrence (detected in 46 patients), pelvic lymphadenopathy (16 patients), para-aortic lymph nodes (in 15 patients), distant lymphadenopathy (in 11 patients), peritoneal implants (in 35 patients) and distant metastasis (in 9 patients) including 4 organs; liver (in 4 patients), lung (in 3 patients), pleura (in 21 patients) and bone (in 1 patient) (Figs. 3, 4, 5 and 6).

Specificity, sensitivity, negative predictive value, as well as positive predictive value and diagnostic accuracy of integrated PET/CT, were found to be 92.3%, 96.3%, 96.1%, 85.7% and 98.4%, respectively.

Discussion

Whole-body ^{18}F-FDG PET/CT has been shown to be an efficient imaging modality for the detection, staging and post-treatment follow-up of many malignant tumors [11–13]. It represents one of the most valuable imaging modalities used in the management of ovarian cancer (OC) [14–16]. Detection of recurrence at early stages is important due to its close relation with prognosis and the choice of appropriate treatment, and although there is effective treatment for OC and complete response, the recurrence rate is 50–80% [17–20]. No different follow up regimen according to the histological subtypes. Tumor makers are more important than regular imaging.

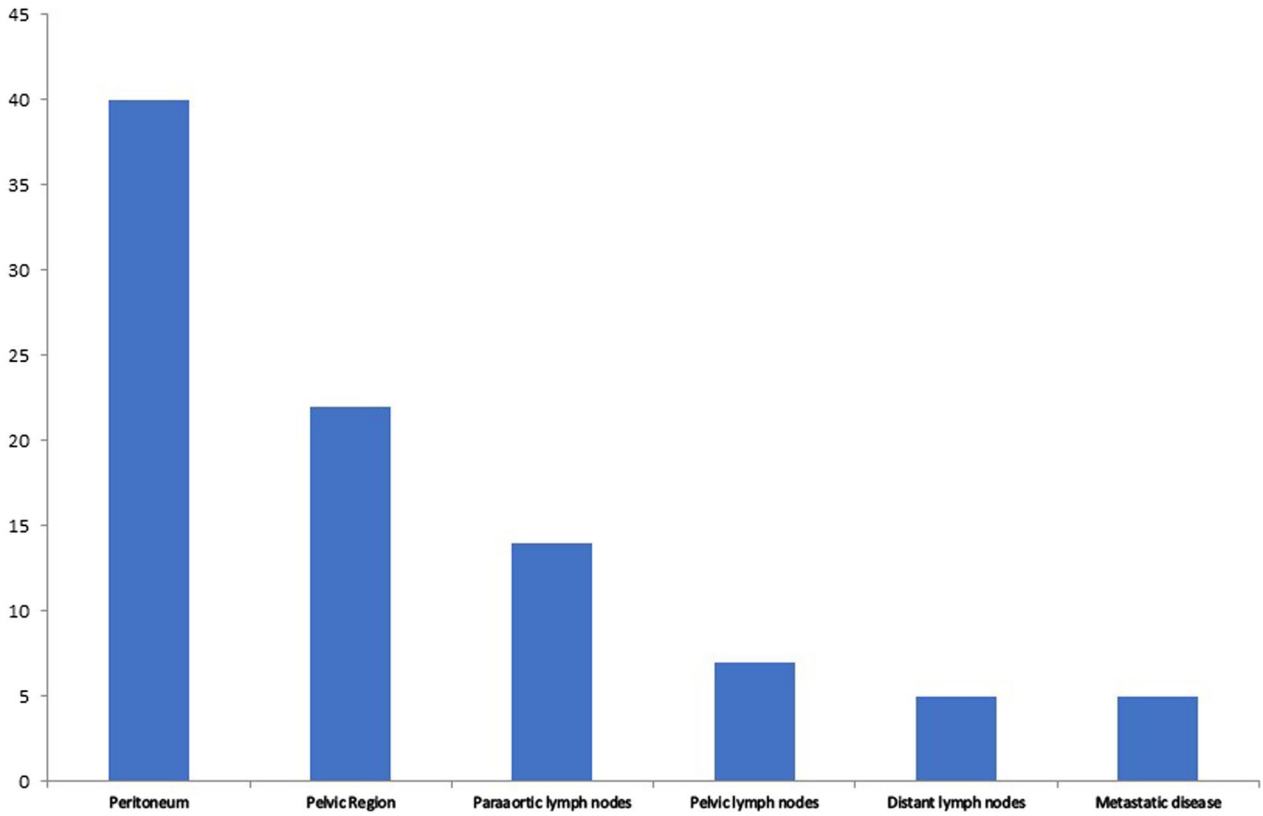

Fig. 1 A column chart shows the sites of recurrence per site

Table 2 The recurrence sites in all studied patients

Recurrence site per patient	*n*
Local	46
Peritoneal	35
Pelvic LNs	16
Para-aortic LNs	15
Distant LNs	11
Distant metastasis	10
Liver	4
Lung	3
Pleura	2
Bone	1

Follow up by gynecological oncologist usually performed 3–4 months for the 1st 2 years then every 6 months for the subsequent 3–5 years. But follow up schemes may be individualized according to the prognostic factors and treatment modalities [21].

Detection of recurrence at early stages is important due to its close relation with prognosis and the choice of appropriate treatment, and although there is effective treatment for OC and complete response, the recurrence rate is 50–80% [22].

The CA 125 marker is expressed by epithelial types of ovarian neoplasia and different other pathological subtypes, as well as normal tissues of Müllerian origin. The function of the CA 125 remains unclear. The highest serum levels of CA 125 are found in ovarian cancer whether in the initial diagnosis or postoperative recurrence, but elevation of serum CA 125 can also be associated with other malignancies [like endometrial carcinoma] and benign condition [like endometriosis]. CA 125 monitoring may be a prognostic indicator for disease recurrence [23].

The aim of current study was to assess the value of whole body 18F-FDG PET/CT using ^{18}F-FDG in follow up of 76 female patients with history of treated ovarian cancer (underwent either surgical resection or received radio/chemotherapy) but were subsequently presented with rising tumor marker CA-125 serum level (more than 35 U/ml) after complete remission with negative pelviabdominal CT or magnetic resonance imaging

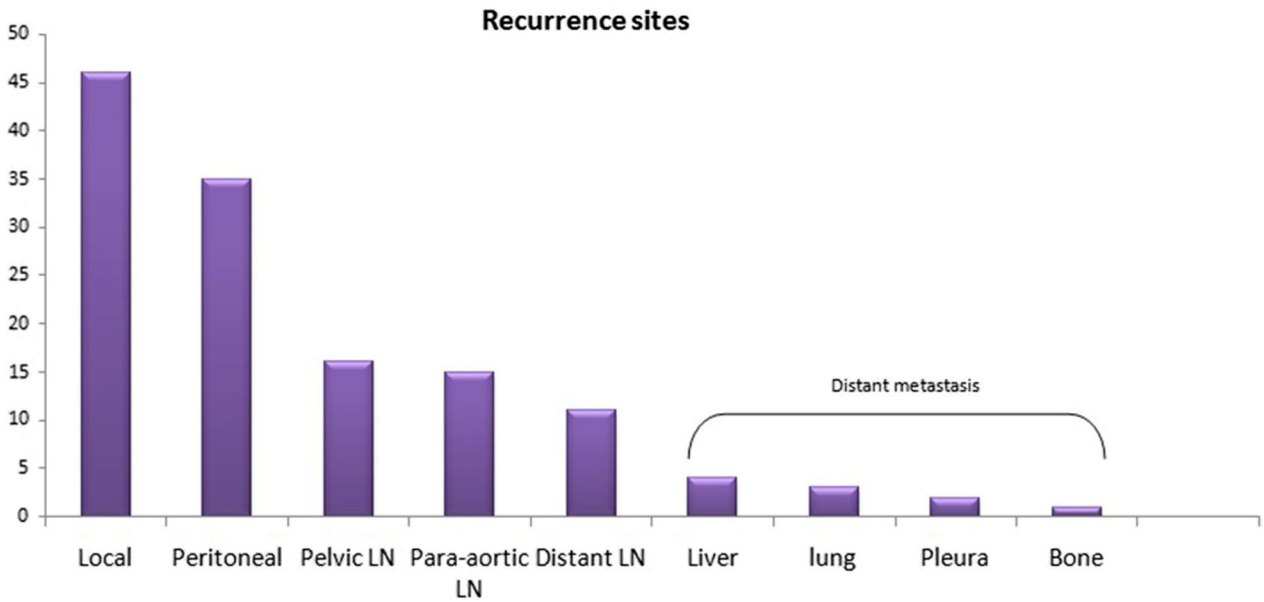

Fig. 2 A column chart shows the sites of recurrence in the studied patients

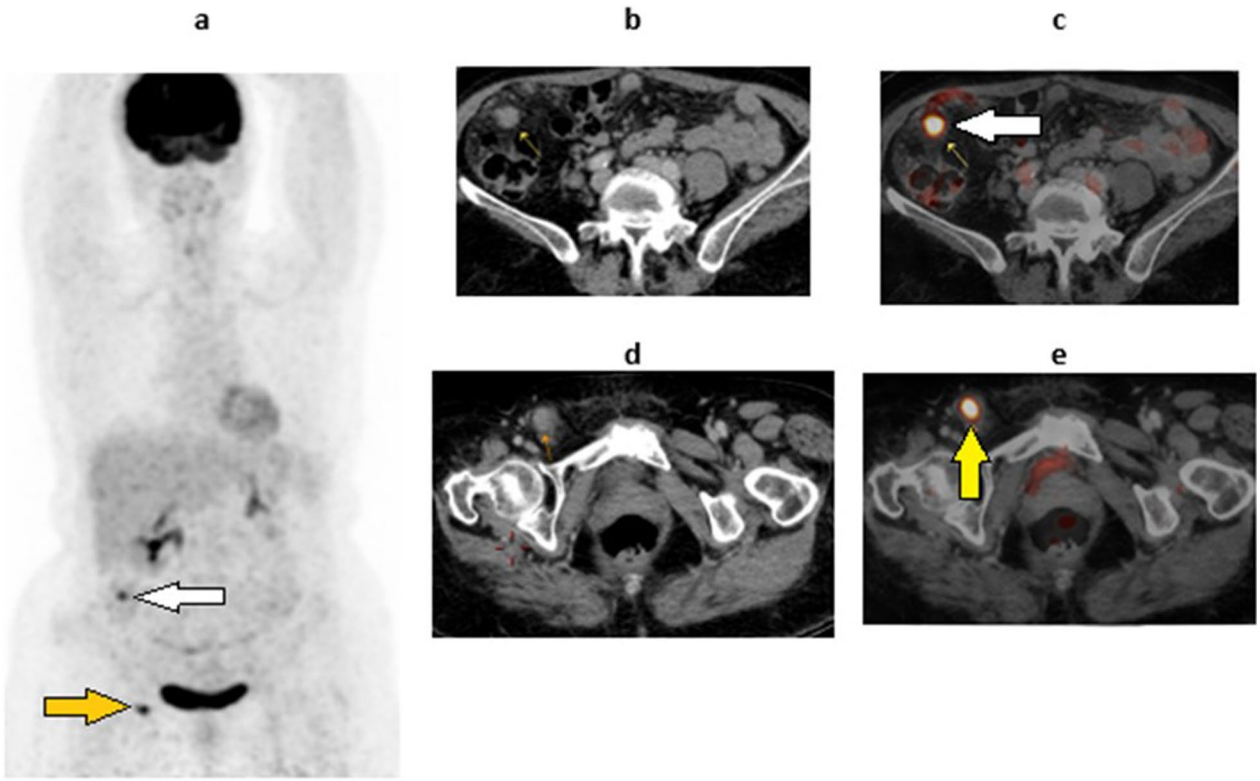

Fig. 3 A 63-year-old female patient, with history of right ovarian serous cystadenocarcinoma, underwent TAH BSO 3 wks ago. (**a**) Whole body PET MIP image revealed two hypermetabolic lesions at right iliac fossa [white arrow] and at right inguinal [yellow arrow] regions. Axial CECT (**b**) and fused PET CT (**c**) images: revealed hypermetabolic metastatic peritoneal soft tissue nodule [white arrow] at the right iliac fossa posterior to the lower right anterior abdominal wall, achieving 7.9 SUVmax. Axial CECT (**d**) and fused PET CT (**e**) images revealed enlarged hypermetabolic right inguinal metastatic nodal deposit [yellow arrow] achieving 9.2 SUVmax

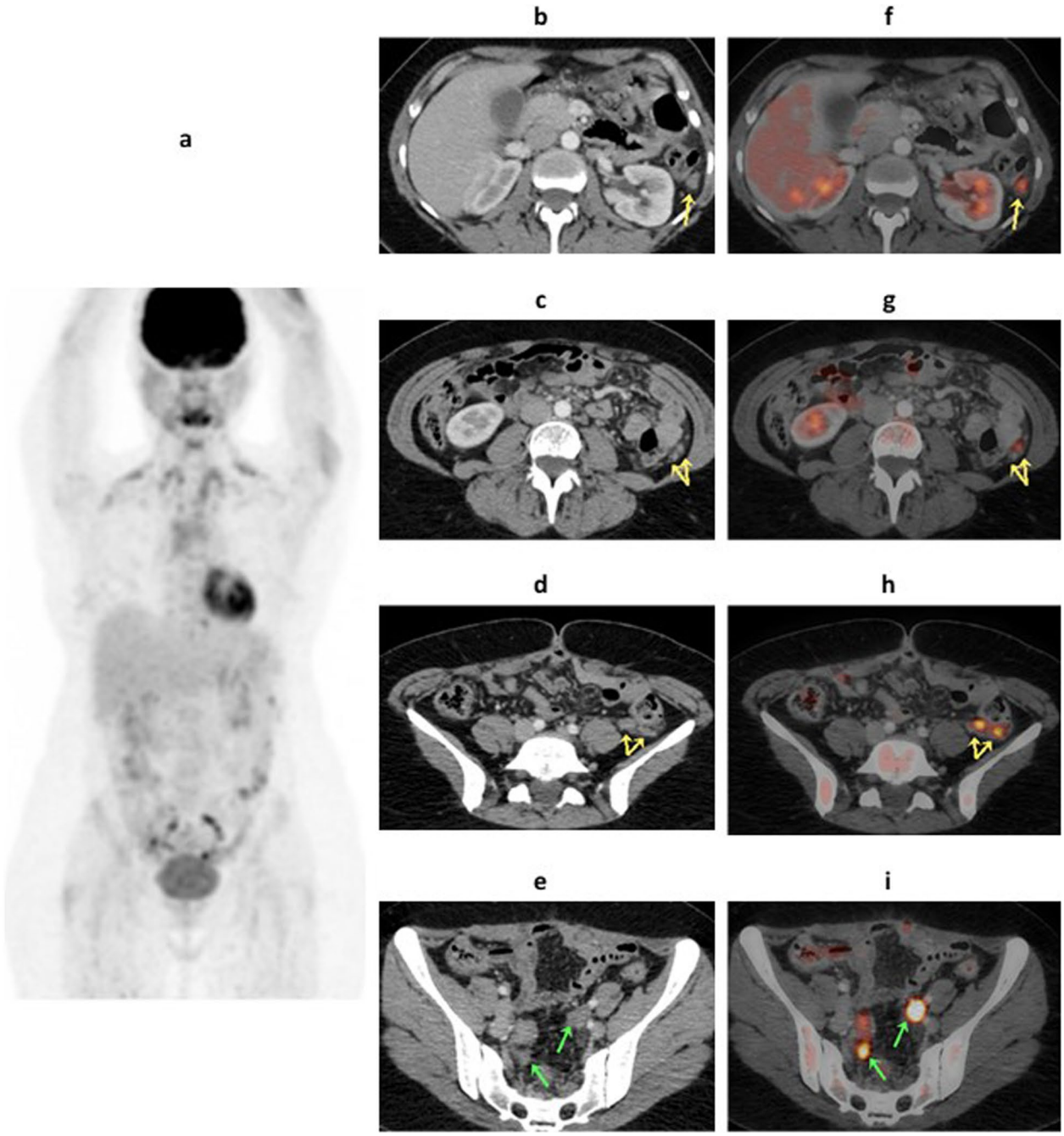

Fig. 4 A 45-year-old female patient with history of bilateral ovarian cancer, submitted for TAH BSO, followed by CTH 1 year ago, presented with recently elevated CA 15.3 and CA 125 serum levels. (**a**) Whole body PET MIP image revealed multiple metabolically active scattered abdominal and pelvic lesions. CECT (**b**, **c**, **d** and **e**) and corresponding fused PET/CT (**f**, **g**, **h** and **i**) images revealed newly developed multiple peritoneal discrete soft tissue nodules unevenly distributed in the peritoneal cavity more appreciated in the paracolic reflections (yellow arrows), achieving up to 5.5 SUVmax, representing peritoneal deposits. Other de novo left external and right internal iliac FDG avid LNs (green arrows), achieving up to 9.2 SUVmax, denoting nodal deposits

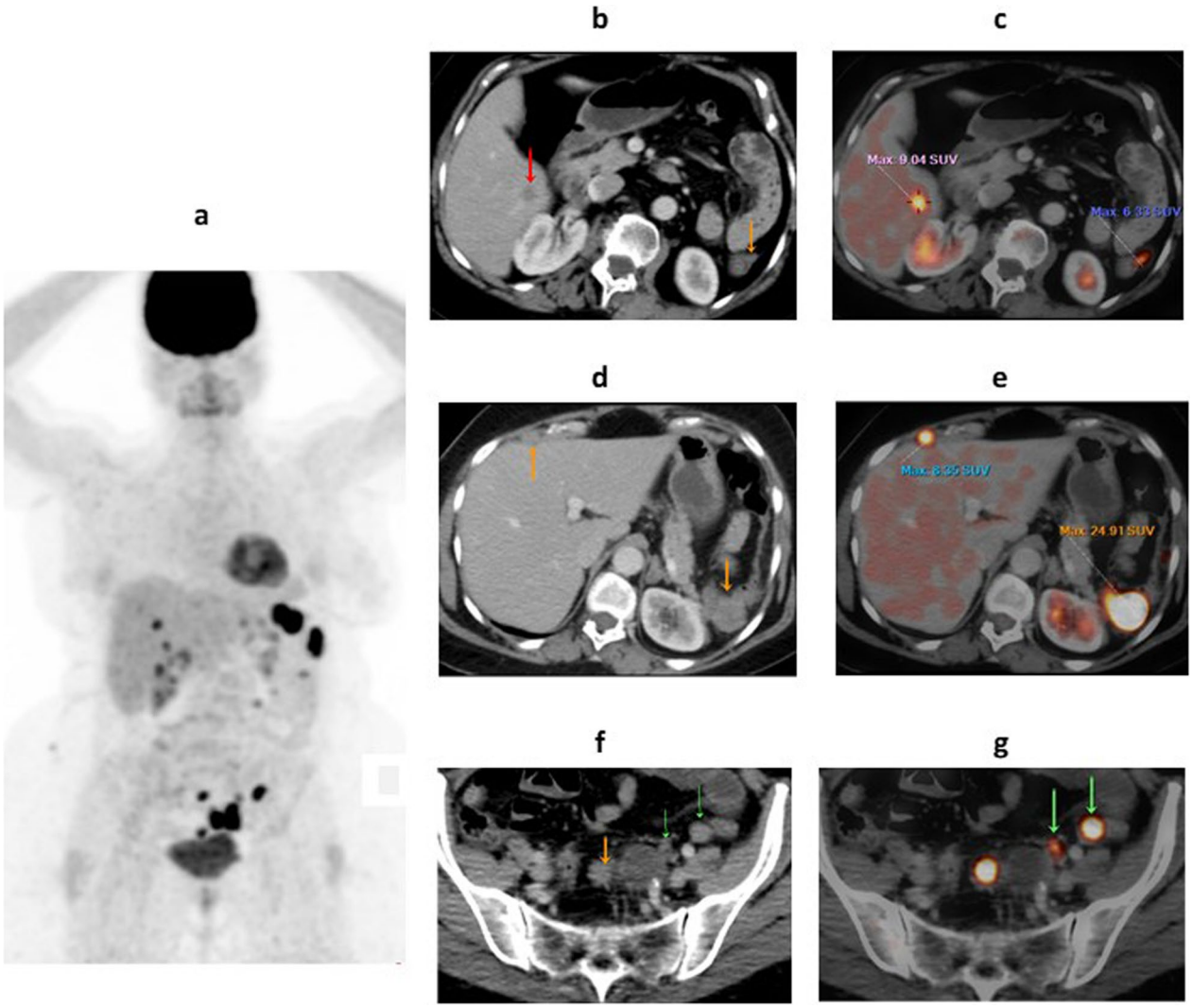

Fig. 5 A 64-year-old female patient with history of bilateral ovarian cancer, submitted for TAH BSO, followed by CTH and hormonal treatment, presented with recently elevated CA 15.3 and CA 125 serum levels. (**a**) Whole body PET MIP image revealed multiple metabolically active scattered abdominal and pelvic lesions. CECT (**b**, **d** and **f**) and corresponding fused PET/CT (**c**, **e** and **g**) images revealed multiple variable-sized peritoneal discrete soft tissue nodules unevenly distributed in the peritoneal cavity (orange arrows), the largest and most active is seen at the left hypochondrial region (achieving 24.9 SUVmax). Other hypermetabolic metastatic hepatic deposit (red arrow) and left external iliac LNs (green arrows) are noted, achieving up to 9 and 14.1 SUVmax, respectively

(MRI). The PET/CT was found to detect recurrence in 61/76 patients with sensitivity and specificity of 96.3% and 92.3% while the PPV and accuracy was 85.7% and 98.4% (Fig. 7).

The study results are generally concordant with those of prior studies in which researchers investigated the value of PET/CT as a surveillance tool in patients suspected with ovarian cancer recurrence.

Cengiz et al. [22] used non-contrast CT in their PET/CT report and had a sensitivity of 94% and specificity of 75% for PET/CT in the detection of ovarian cancer recurrence.

Other study by ElHariri et al. [24], conducted on thirty-six patients with suspicion of ovarian cancer recurrence using CECT in their PET/CT studies, revealed accuracy, sensitivity and specificity of 95.77%, 85.7% and 97.89%, respectively.

Also, Wang et al. [25] conducted a systematic review and Meta analysis to summarize 17 studies and evaluate the accuracy and application value of 18F-FDG PET/CT in the diagnosis of recurrence of epithelial ovarian cancer. It was found that the sensitivity, specificity of 18F-FDG PET/CT for the diagnosis of epithelial ovarian cancer recurrence were 88% and 94% respectively.

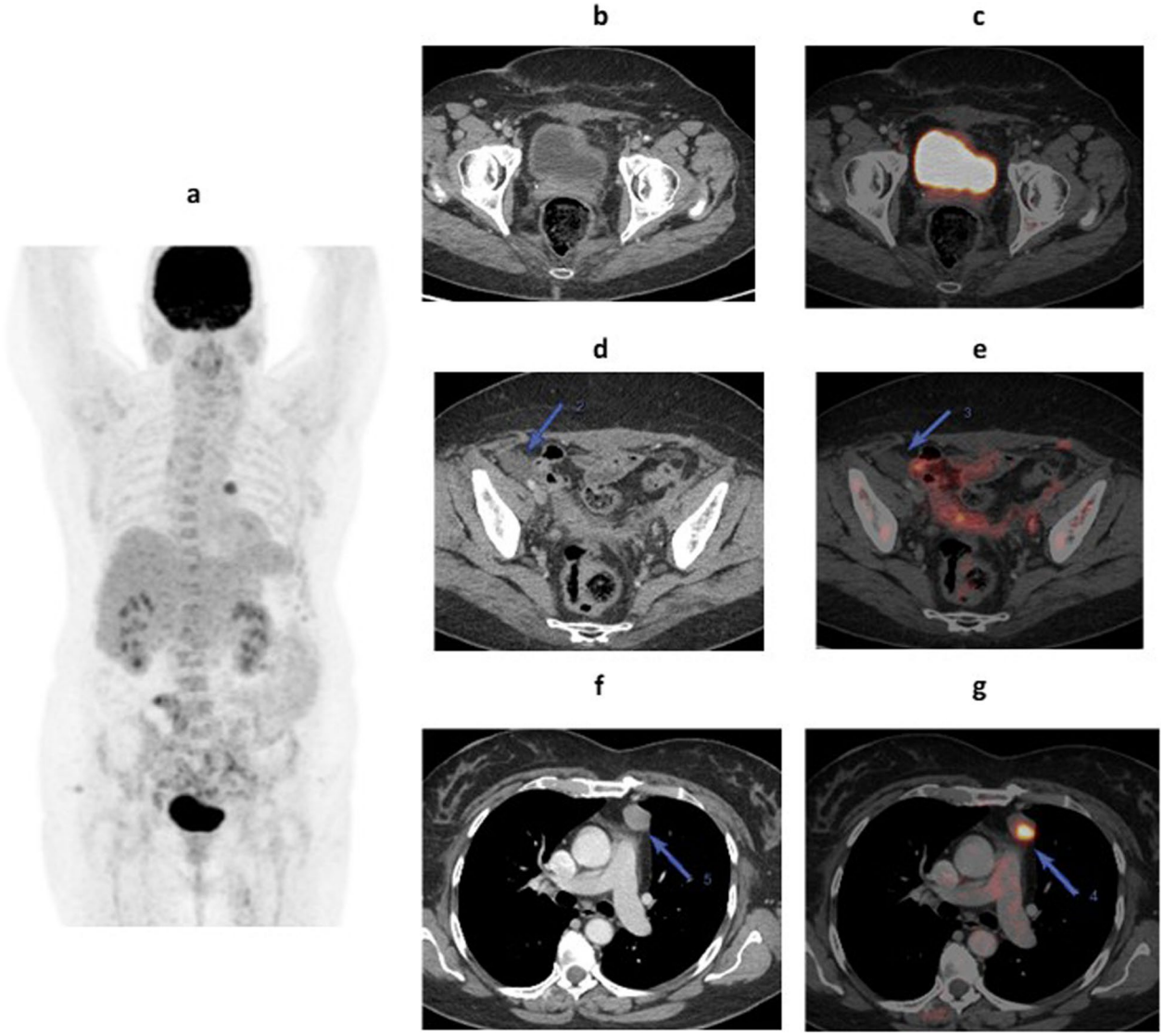

Fig. 6 A 58-year-old female patient, with history of left ovarian invasive mucinous adenocarcinoma grade III, submitted for TAH BSO, presented with recently elevated CA 15.3 and CA 125 serum levels. (**a**) Whole body PET MIP image revealed metabolically active mediastinal lesion. CECT (**b**, **d** and **f**) and corresponding fused PET/CT (**c**, **e** and **g**) images revealed clear pelvic operative bed and no evidence of local recurrence, with hypodense FDG starved necrotic right external iliac nodal lesion, yet, with distant hypermetabolic anterior mediastinal nodal deposit (achieving 7.3 SUVmax)

On the other hand, old studies as Sala et al. [26], showed low sensitivity (59–75%) but high specificity (88–94%) due to very small sample size ($n = 35$).

Regarding the recurrence sites, local pelvic recurrence was the most common site and hepatic was the commonest distant metastasis as found by Rusu et al. and Ye et al. [20, 27].

The current study had some limitations: first, the gold standard (pathological confirmation) could not be achieved in all areas of FDG uptake as that was not ethically possible, and the second limitation was the small study cohort number.

Conclusions

^{18}F FDG PET/CT is a valuable imaging tool for follow up of previously treated ovarian cancer patients presenting with rising tumor marker serum levels [whether due to postoperative regional pelvic recurrence, nodal,

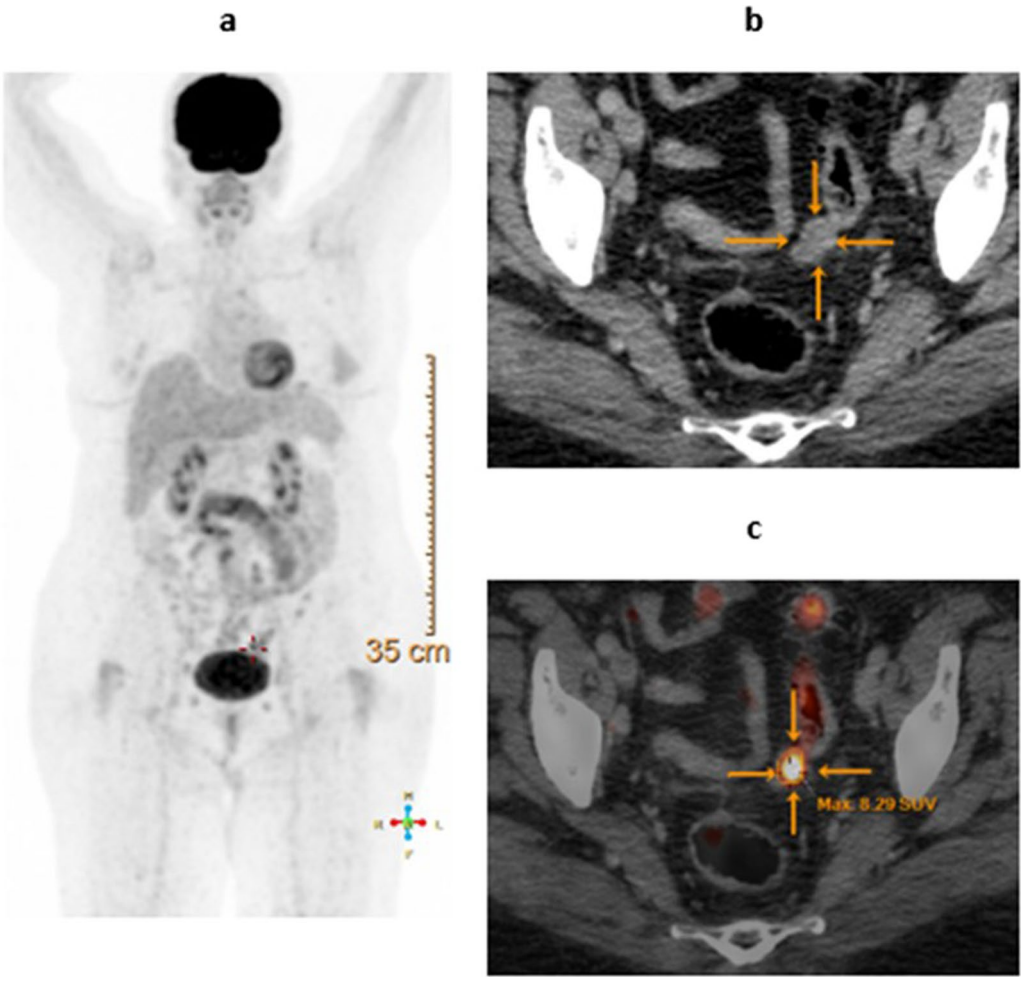

Fig. 7 A 62-year-old female patient, with history of left ovarian cancer, underwent TAH BSO 6 months ago. (**a**) Whole body PET MIP image revealed tiny active focus at left iliac fossa. Axial CECT (**b**) and fused PET CT (**c**) images: revealed small irregular hypermetabolic metastatic peritoneal soft tissue nodule [yellow arrows] at the left iliac fossa inseparable from the serosal surface of the sigmoid colon, achieving 8.2 SUVmax

peritoneal or distant visceral deposits] that has a great impact on management. Also, it can be a basal study for the post treatment further follow up using PERCIST criteria.

Abbreviations

^{18}F-FDG	^{18}F-Fluorodeoxyglucose
PET/CT	Positron emission tomography/computed tomography
CT	Computed tomography
MRI	Magnetic resonance imaging
CA-125	Cancer antigen 125
SUVmax	Maximum standardized uptake value
TAH BSO	Total abdominal hysterectomy with bilateral salpingo-oophorectomy

Acknowledgements
Not applicable

Author contributions
SA carried out the PET/CT studies and collected the data. SA, MM and SR participated in the design of the study. SR and MM performed the statistical analysis and SA and DA drafted the manuscript. All authors read and approved the final manuscript.

Funding
This work has not received any funding.

Availability of data and materials
All data generated or analyzed during this study are included in this article.

Declarations

Ethics approval and consent to participate
The study protocol was approved by the Research Ethics Committee (REC) of Ain Shams University, Faculty of Medicine (FMASU R 28/2019) and written informed consent was obtained from all patients to participate in the study.

Consent for publication
Written informed consent was obtained from all patients for publication of the study.

Competing interests
The authors declare that they have no competing interests.

Received: 4 February 2023 Accepted: 6 July 2023
Published online: 18 July 2023

References

1. Siegel RL, Miller KD, Jemal A (2017) Cancer statistics. CA Cancer J Clin 67:7–30
2. Mapelli P, Incerti E, Fallanca F (2016) Imaging biomarkers in ovarian cancer: the role of 18F-FDG PET/CT. Q J Nucl Med Mol Imaging 60:93–102
3. Ferlay J, Soerjomataram I, Dikshit R (2015) Cancer incidence and mortality worldwide: sources, methods and major patterns in GLOBOCAN 2012. Int J Cancer 136:359–386
4. Surveillance, Epidemiology, and End Results (SEER) Program (www.seer.cancer.gov) Research Data (1973–2014), National Cancer Institute, DCCPS, Surveillance Research Program (2017) Based on the November 2016 submission. Available at: https://seer.cancer.gov/statfacts/html/ovary.html.
5. NCCN Clinical Practice Guidelines in Oncology. National Comprehensive Cancer Network. http://www.nccn.org/professionals/physician_gls/f_guidelines.asp. Accessed 1 Feb 2011.
6. Petru E, Lück HJ, Stuart G (2009) Gynecologic Cancer Intergroup (GCIG) proposals for changes of the current FIGO staging system. Eur J Obstet Gynecol Reprod Biol 143(2):69–74
7. Palomar A, Nanni C, Castellucci P (2012) Value of FDG PET/CT in patients with treated ovarian cancer and raised CA125 serum levels. Mol Imaging Biol 14:123–129
8. Evangelista L, Palma M, Gregianin M (2015) Diagnostic and prognostic evaluation of fluorodeoxyglucose positron emission tomography/computed tomography and its correlation with serum cancer antigen125 (CA125) in a large cohort of ovarian cancer patients. J Turk Ger Gynecol Assoc 16:137–144
9. Fularz M, Adamiak P, Czepczynski R et al (2015) Utility of PET/CT in the diagnosis of recurrent ovarian cancer depending on CA 125 serum level. Nuklearmedizin 54:158–162
10. Pannu HK, Bristow RE, Cohade C, Fishman EK, Wahl RL (2004) PET-CT in recurrent ovarian cancer: initial observations. Radiographics 24(1):209–223
11. Sarhan EA, El Gohary MI, El Moneim LA, Ali SA (2020) Role of 18 fluorine-fluorodeoxyglucose positron emission tomography/computed tomography in assessment of neoadjuvant chemotherapy response in breast cancer patients. EJRNM 51:116
12. Tawfik MM, Monib AM, Yassin A, Ali SA (2020) Comparison between RECIST and PERCIST criteria in therapeutic response assessment in cases of lymphoma. EJRNM 51:82
13. Ali SA, Hamed MA (2017) The diagnostic efficacy of whole body 18F FDG PET CT in detection of unexpected second primary malignancy in cancer patients. EJRNM 48(3):671–676
14. Armstrong DK (2002) Relapsed ovarian cancer: challenges and management strategies for a chronic disease. Oncologist 7:20–28
15. Marcus CS, Maxwell GL, Darcy KM, Hamilton CA, McGuire WP (2014) Current approaches and challenges in managing and monitoring treatment response in ovarian cancer. J Cancer 5:25–30
16. Kim HJ, Kim JK, Cho KS (2004) CT features of serous surface papillary carcinoma of the ovary. AJR Am J Roentgenol 183(6):1721–1724
17. Qayyum A, Coakley FV, Westphalen AC, Hricak H, Okuno WT, Powell B (2005) Role of CT and MR imaging in predicting optimal cytoreduction of newly diagnosed primary epithelial ovarian cancer. Gynecol Oncol 96(2):301–306
18. Gu P, Pan LL, Wu SQ (2009) CA 125, PET alone, PET–CT, CT and MRI in diagnosing recurrent ovarian carcinoma: a systematic review and meta-analysis. Eur J Radiol 71:164–174
19. Ak I, Stokkel MP, Pauwels EK (2000) Positron emission tomography with FDG inoncology: the clinical value in detecting and staging primary tumors. J Cancer Res Clin Oncol 126:560–574
20. Rusu G, Achimaș-Cadariu P, Piciu A, Căinap SS, Căinap C, Piciu DA (2021) Comparative study between 18F-FDG PET/CT and conventional imaging in the evaluation of progressive disease and recurrence in ovarian carcinoma. Healthcare 9(6):666
21. Fotopoulou C (2017) British Gynaecological Cancer Society (BGCS) epithelial ovarian/fallopian tube/primary peritoneal cancer guidelines: recommendations for practice. Eur J Obstet Gynecol Reprod Biol 213:123–139
22. Cengiz A, Koç ZP, Özcan Kara P, Yürekli Y (2019) The role of 18F-FDG PET/CT in detecting ovarian cancer recurrence in patients with elevated CA-125 levels. Mol Imaging Radionucl Ther 28(1):8–14
23. Mohamed G, Mohamed S, Ismail M (2022) Validity of estimation of IL-6 level over cancer antigen-125 (CA-125) with sonographic criteria in the prediction of ovarian cancer in patients with adnexal mass. AIMJ 3(7):70–75
24. ElHariri MA, Harira M, Riad MM (2019) Usefulness of PET–CT in the evaluation of suspected recurrent ovarian carcinoma. EJRNM 50:2
25. Wang X, Yang L, Wang Y (2022) Meta-analysis of the diagnostic value of 18F-FDG PET/CT in the recurrence of epithelial ovarian cancer. Front Oncol 12:1003465
26. Sala E, Kataoka M, Pandit-Taskar N (2010) Recurrent ovarian cancer: use of contrast-enhanced CT and PET/CT to accurately localize tumor recurrence and to predict patients' survival. Radiology 257(1):125–134
27. Ye S, Liu S, Xiang L et al (2019) 18F-FDG PET/CT-based metabolic metrics in recurrent tumors of ovarian clear cell carcinoma and their prognostic implications. BMC Cancer 226

Publisher's Note