Kosinepalli *et al. Egypt J Radiol Nucl Med* (2023) 54:123
https://doi.org/10.1186/s43055-023-01069-y

Egyptian Journal of Radiology and Nuclear Medicine

CASE REPORT

Open Access

Case series of identity: renal lymphangiectasia mistaken for non-functional hydronephrotic kidney

Sai Siddartha Kosinepalli[1*], Sudha Kiran Das[1], Balasubramanian Gurumurthy[1], T. Sachin[2] and Swathi Hassan Dharmaraju[1]

Abstract

Background Renal lymphangiectasia also referred to as renal lymphangiomatosis is a rare, but benign condition is characterized by the ectatic of lymphatic channels and is characterized by ectasia of peripelvic, perirenal and/or intrarenal lymphatic vessels. It can mimic the appearance of hydronephrosis or cystic renal lesions on imaging**.** As radiologists, to avoid therapeutic misadventure, it becomes critical to make an accurate diagnosis.

Case presentation The clinical presentation of renal lymphangiectasia is typically asymptomatic, but it can be complicated by infection or bleeding. We report two cases, who presented with loin pain, diagnosed as hydronephrosis on ultrasound, one of whom had a nephrectomy done for a hydronephrotic and non-functioning right kidney.

Conclusions Hence, this case series brings to light a short review of the literature on renal lymphangiectasia, including its pathophysiology, clinical presentation, imaging findings, complications and differential diagnosis.

Keywords Renal lymphangiectasia, Hydronephrosis, Perinephric space, Peripelvic space

Background

Cystic renal lesions are frequently encountered on abdominal imaging studies, and while most of these lesions are benign simple cysts, complex and multifocal cystic renal diseases can also be seen. These conditions can have a wide range of differentials, making accurate diagnosis challenging. It is often mistaken for peripelvic cysts, renal cysts or hydronephrosis [1]. One rare condition that can mimic the appearance of cystic renal lesions is renal lymphangiectasia. The key to accurately diagnosing renal lymphangiectasia is for radiologists to be aware of the imaging findings associated with this condition, which can help guide physicians in making the appropriate treatment decisions.

Renal lymphangiectasia is a very rare benign disorder of the renal lymphatics seen in both children and adults. Less than 50 cases have been reported in the literature till date [2]. It may be unilateral or bilateral, focal or diffuse involvement and has no gender predilection. Overall, the pathophysiology of this condition is not understood. It has been proposed that renal lymphatic vessels and large retroperitoneal lymphatics do not communicate. The differentials of renal lymphangiectasia include other cystic renal diseases such as simple cysts, polycystic kidney disease and cystic nephroma. These two cases illustrate different anatomical presentation patterns, varying from cortical to perihilar to perinephric involvement, and highlight how the diagnostic approach can be incredibly challenging.

*Correspondence:
Sai Siddartha Kosinepalli
drsaisiddarthak@gmail.com
[1] Department of Radiodiagnosis, JSS Medical College, JSS Academy of Higher Education and Research, Mysuru, Karnataka 570004, India
[2] Department of Radiodiagnosis, Hassan Institute of Medical College, Hassan, Karnataka, India

Case presentation

Case 1

A 42-year-old female patient presented with left loin pain for 3-month duration, solitary left kidney, post-right nephrectomy status for hydronephrosis and non-functioning kidney. Physical examination revealed left flank pain and tenderness. Sonography done elsewhere was reported as left hydronephrosis. Laboratory revealed normal renal function tests. Patient was referred to our institute for contrast-enhanced computed tomography (CECT) and further management. CECT was performed on Philips Ingenuity 128-slice CT machine using 75 ml iohexol (300 mg I/ml) (Omnipaque 300) as intravenous contrast media. CT revealed multiple, non-enhancing, thin-walled hypodensities with plain CT attenuation of 9–11 HU in the left renal sinus and along the calyces with no calyceal distortion (Fig. 1). Non-enhancing lesion with similar attenuation values was noted in the aortocaval window at the level of L1–L2 vertebra (Fig. 2). A diagnosis of renal lymphangiectasia was made, and corroborative magnetic resonance imaging (MRI) was performed using a 3 T MRI machine (Ingenia Philips 3 T medical systems, the Netherlands). Ectatic pericalyceal lymphatics were seen as hyperintensities on T2W and T2-SPAIR images (Fig. 2). The patient was managed conservatively.

Fig. 1 Axial contrast-enhanced CT image showing multiple, non-enhancing, thin-walled, low-attenuation hypodense cysts in renal sinus and corticomedullary junction of left kidney with no significant compression over the pelvicalyceal system

Case 2

A 35-year-old male patient presented with bilateral loin pain for 6-month duration. Past medical and family history was unremarkable. Physical examination revealed bilateral flank pain and tenderness. Laboratory revealed normal renal function tests. Ultrasonography was performed using Philips iU22 ultrasound machine with 1–5 MHz curvilinear transducer which revealed normal-sized kidneys with preserved corticomedullary differentiation, multiple, anechoic peripelvic and perinephric cystic lesion insinuating into the renal sinuses and splaying the pelvicalyceal system on both sides (Figs. 3, 4). CECT was performed using a Philips Ingenuity 128-slice CT machine using 70 ml iopromide (300 mg I/ml) (Ultravist) as intravenous contrast media. CT revealed multiple, non-enhancing, thin-walled hypodense cystic lesions which appeared to be intercommunicating with attenuation values in the range of 5–10 HU. Striated pyelogram with distortion and splaying of renal pelvis and calyces were noted in the delayed phases. Perinephric component caused scalloping of the renal cortex. (Figs. 5, 6). Renal function was preserved bilaterally with prompt nephrogram and excretion (Fig. 7). A diagnosis of bilateral renal lymphangiectasia was made. Another lesion with similar imaging characteristics was imaged in the mesentery in the left iliac fossa coursing along the distal segment of

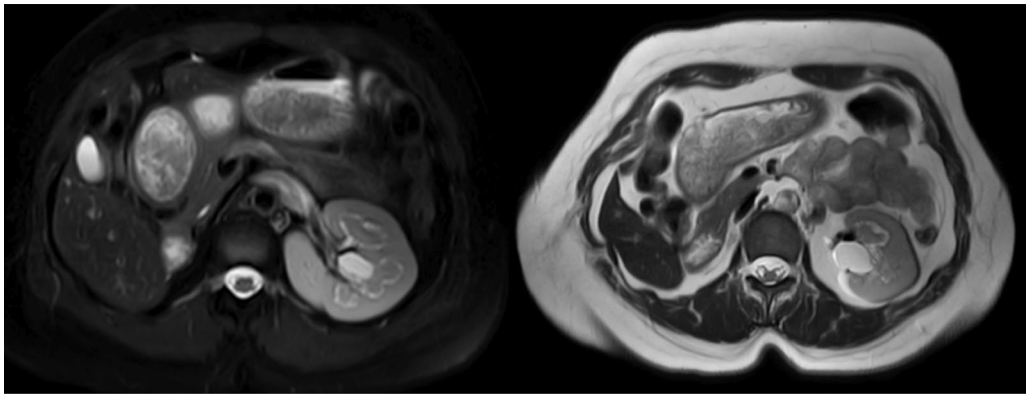

Fig. 2 MRI T2 SPAIR and T2W image showing multiple tiny hyperintense cysts in the renal sinus and at corticomedullary junction of left kidney

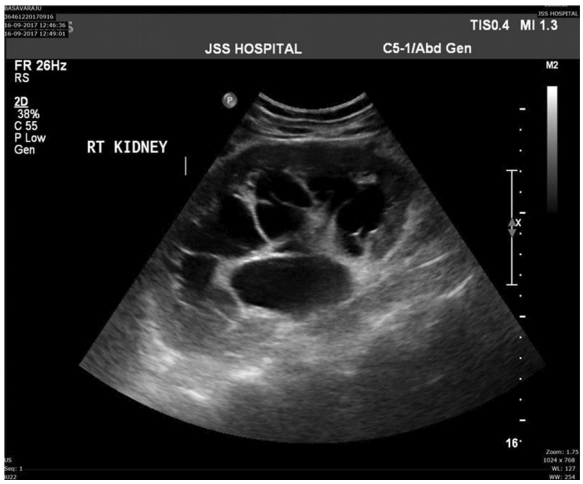

Fig. 3 Longitudinal ultrasound image showing enlarged right kidney with multiseptated anechoic fluid-filled hypoechoic cysts in the peripelvic spaces splaying the pelvicalyceal system. The corticomedullary differentiation is maintained

Fig. 5 Axial contrast-enhanced CT image showing multiple, non-enhancing, thin-walled, low-attenuation hypodense cysts in peripelvic and perinephric spaces compressing the pelvicalyceal system and scalloping of both renal contour

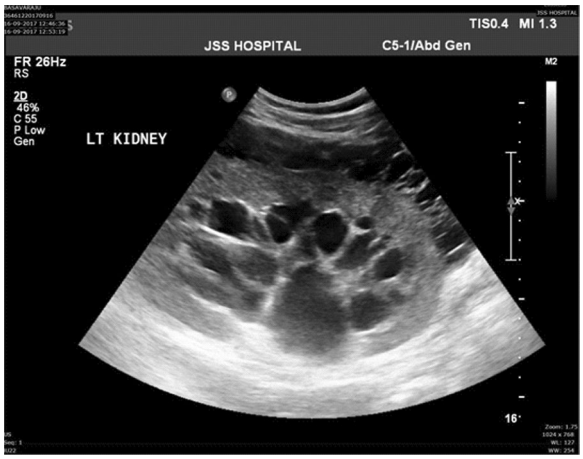

Fig. 4 Longitudinal ultrasound image showing enlarged left kidney with multiseptated anechoic fluid-filled hypoechoic cysts in the peripelvic and perinephric spaces

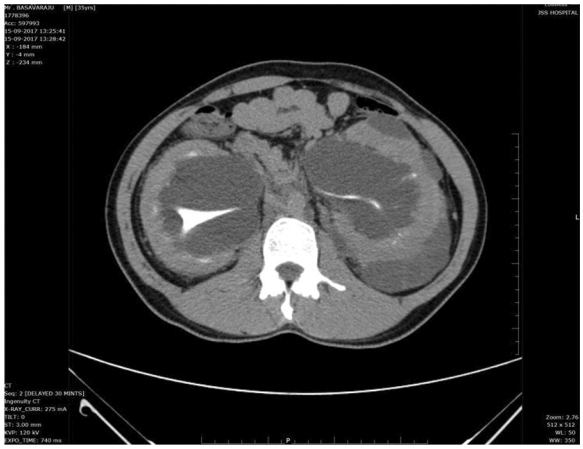

Fig. 6 Delayed axial contrast-enhanced CT image showing bilateral peripelvic and perirenal cysts with splayed pelvicalyceal system

inferior mesenteric vein. There was marked dilatation of the retroperitoneal lymphatics, encompassing and compressing the IVC at the level of renal vein confluence. Proximal lymphatics were also ectatic, coursing along the paravertebral region to thoracic area in the sections imaged (Fig. 8). Magnetic resonance imaging (MRI) was performed using a 3 T MRI machine (Ingenia Philips 3 T medical systems, the Netherlands). High-resolution, half-Fourier, T2W turbo spin echo (TSE), T1W imaging was performed in the axial and coronal planes. MRI confirmed the CT findings and diagnosis of renal lymphangiectasia. Imperceptible wall, intercommunicating cysts, associated ectasia of retroperitoneal lymphatics, cisterna chyli and thoracic duct were observed on MRI (Figs. 9, 10). The patient was managed conservatively.

Discussion

With the normal lymphatic drainage of the kidney and its capsule, perinephric tissues intercommunicate through multiple lymphatic trunks within the renal sinus. These lymphatics drain through larger trunks in the renal pedicle to the pericaval, para-aortic and aortocaval lymph nodes [3]. Renal lymphangiectasia is a rare, benign developmental malformation in which the developing lymphatic tissue fails to establish communication with the

Fig. 7 CT urography with 3D recon image showing bilateral splayed pelvicalyceal system and absent hydroureteronephrosis

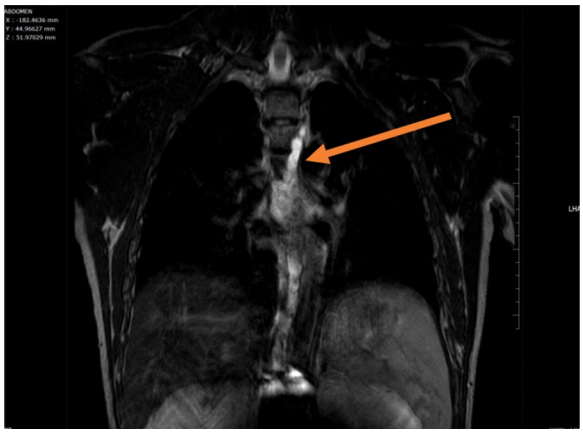

Fig. 8 Coronal T2 fat-suppressed image demonstrates dilatation of the cisterna chyli and thoracic duct (long arrow)

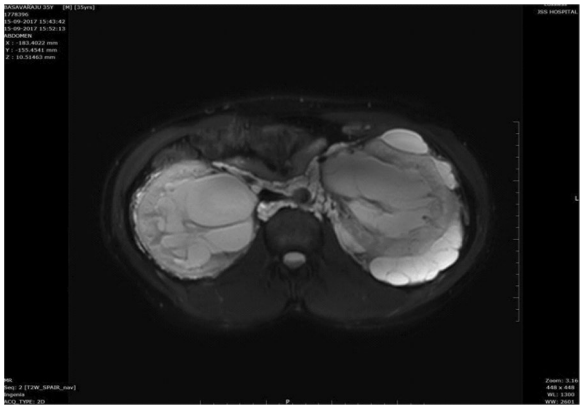

Fig. 9 T2W axial image showing hyperintense bilateral peripelvic and perirenal cysts

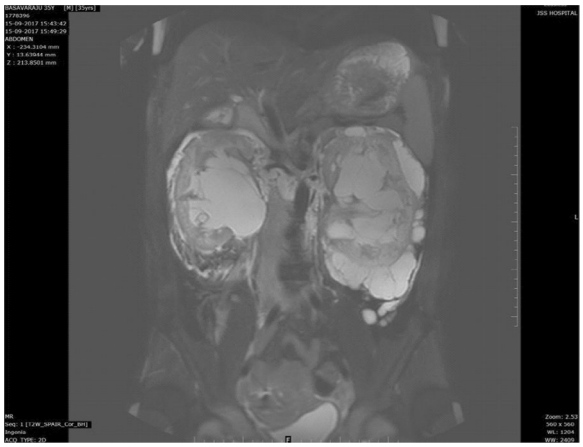

Fig. 10 T2W coronal image showing hyperintense bilateral peripelvic and perirenal cysts

remainder of the lymphatic system. As a result, abnormal lymphatic channels dilate to form localized or generalized cystic masses. The lesion may involve the renal sinus, renal parenchyma and perirenal fascia. Association with retroperitoneal perivascular lymphatic cysts has also been described [4].

The prevalence, etiopathogenesis and natural history have not been clearly known. The knowledge about its clinical presentation and imaging findings are derived from isolated case reports. Clinically, the condition may be asymptomatic and often detected incidentally. In symptomatic patients, flank pain is the most frequent complaint as in our case. Few of them may present with palpable abdominal mass, gross or microscopic hematuria, ascites, weight loss and hypertension [5].

The lymphatic malformation may be limited to the renal parenchyma, which, depending on the extent of involvement, either manifests as a solitary focal lymphangioma or diffuses renal enlargement on imaging [6]. The pathological process may be limited to the renal sinus, which may be usually mistaken for hydronephrosis [7]. The least common variant of retroperitoneal lymphangiectasia affects the entire kidney and retroperitoneal tissues, and is associated with significant enlargement of the kidneys [8].

On ultrasonography, they appear as multiple, thin-walled fluid-filled cystic collections seen in the perinephric and peripelvic spaces with normal renal parenchyma. The kidneys may be normal in size or enlarged with maintained corticomedullary differentiation. Some of the cases may show increased cortical echogenicity with loss of corticomedullary differentiation due to an increase through transmission of ultrasound by the collections. Ascites may be seen in some cases (Fig. 11).

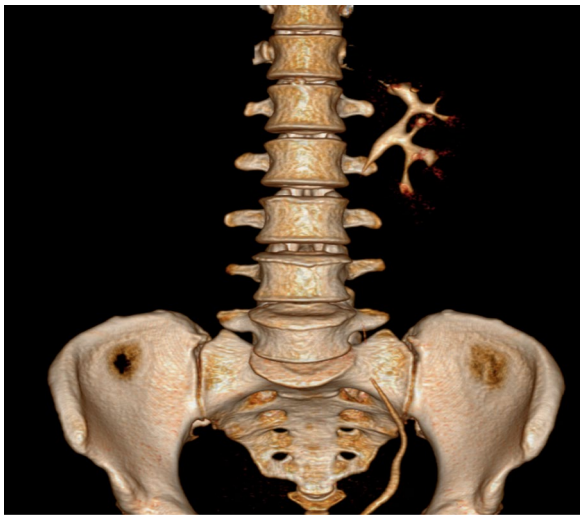

Fig. 11 CT urography with 3D recon image showing left splayed pelvicalyceal system and absent hydroureteronephrosis

Unenhanced CT examination reveals the presence of multiple low-attenuation cystic collections (5–10 HU) in the peripelvic and perinephric spaces, but the septations may not be delineated as clearly as in ultrasonography. On post-contrast study, there may be enhancement of the septations and splaying of pelvicalyceal system on delayed images. There is no evidence of cysts in other organs or adjacent local invasion [9].

MR imaging findings include low T1WI and high T2WI signal intensity of the peripelvic and perinephric cysts. The perirenal cysts may show thin septations. Additionally, the parenchyma may show increased cortical intensity and decreased medullary intensity on T2WI. This feature of corticomedullary reversal and increased medullary signal intensity may be secondary to obstructed intrarenal lymphatics and subsequent edema.

The main differential diagnosis for this condition includes polycystic kidney disease, nephroblastomatosis, multilocular cystic nephroma, urinoma, abscess and bilateral perirenal liposarcomas. Apart from the typical imaging findings and clinical history, laboratory analysis of the aspirated fluid also helps in differentiating lymphangiectasia from urinoma and abscess [10].

Conclusions

Renal lymphangiectasia is a rare benign condition which is usually asymptomatic and detected incidentally on routine imaging. Knowledge about imaging features of this condition helps in differentiating it from other cystic diseases of the kidney. If typical imaging findings on ultrasonography, CT and MRI are recognized, an accurate diagnosis can be made. In those cases where imaging findings are inconclusive, an image-guided fluid aspiration and laboratory analysis can help to establish the diagnosis and avoid unnecessary surgical procedures [10].

Abbreviations

MRI	Magnetic resonance imaging
CT	Computed tomography
HU	Hounsfield unit
KUB	Kidney ureter bladder

Acknowledgements

Not applicable.

Author contributions

SSK reported the case, drafted the manuscript and gave title along with information and research. SKD reported the case, drafted the manuscript and gave information. BG reported the case, drafted the manuscript and gave images. ST reported the case, drafted the manuscript and gave images. SHD reported the case and drafted the manuscript. All authors have read and approved the manuscript.

Funding

No funding was obtained for this study.

Availability of data and materials

Datasets generated and analyzed during the current study are available from the corresponding author on reasonable request.

Declarations

Ethics approval and consent to participate

Written consent was obtained and approved.

Consent for publication

Written consent was obtained and approved from participant subjects.

Competing interests

The authors declare that they have no competing interests.

Received: 7 April 2023 Accepted: 8 July 2023
Published online: 18 July 2023

References

1. Jorge MR, Juan LA, Natalia AS, Melissa UV, Mauricio M (2011) Renal lymphangiectasia: MDCT and MRI findings. Rev Colomb Radiol 22(3):1–8
2. Dawidek MT, Aquil S, Alogaili R (2020) Renal lymphangiectasia in the transplanted kidney: case series and literature review. Transplantation 104:172–175
3. Kabalin JN (1992) Surgical anatomy of the genitourinary tract. In: Wals PC, Retik AB, Stamey TA et al (eds) Campbell's urology, 6th edn. WB Saunders, Philadelphia, p 31
4. Varela JR, Bargiela A, Requejo I et al (1998) Bilateral renal lymphangiomatosis: US and CT findings. Eur Radiol 8:230–231
5. Upreti L, Dev A, Kumar PS (2008) Imaging in renal lymphangiectasia: report of two cases and review of literature. Clin Radiol 63:1057–1062
6. Kim JK, Ahn HJ, Kim K et al (2002) Renal lymphangioma manifested as a solid mass on ultrasonography and computed tomography. J Ultrasound Med 21:203–206
7. Sarikaya B, Akturk Y, Bekar U et al (2006) Bilateral renal lymphangiomatosis mimicking hydronephrosis: multidetector CT urographic findings. Abdom Imaging 31:732–734

8. Ratti M, Ammar L, Zennaro F et al (2004) Renal lymphangiectasia. Pediatr Radiol 34:669–670
9. Pandya VK, Shah MK, Gandhi SP, Patel HV (2016) Bilateral renal lymphangiectasia. J Clin Diagn Res JCDR 10(9):19475.8409
10. Singh SN, Sundar G, Satishchandra H (2014) An unusual case of bilateral renal lymphangiectasia. S Afr J Radiol 18(1):1–4

Publisher's Note