Abd-Elmageed *et al. Egypt J Radiol Nucl Med* (2023) 54:136
https://doi.org/10.1186/s43055-023-01086-x

Egyptian Journal of Radiology and Nuclear Medicine

RESEARCH

Open Access

Diagnostic accuracy of B-mode, Doppler ultrasound, strain elastography, and 2D shear wave elastography in differentiation between benign and malignant lymphadenopathy

Mohamed Kamel Abd-Elmageed[1], Sahar Gamal Ibrahim[1*] and Mohammed Salah Eldeen El Zawawi[1]

Abstract

Background Conventional ultrasound is used as an imaging modality for differentiation between benign and malignant lymph nodes, but with different accuracy, sensitivity, and specificity between different studies. A biopsy is the gold standard diagnosis modality but has a drawback due to its invasive nature. In general, metastatic lymph nodes present with a higher stiffness than benign lymph nodes, so ultrasound elastography could be used as an imaging modality for lymphadenopathy differentiation based on its ability to assess tissue stiffness. However, more studies should be done to assess its accuracy. Therefore, we aimed to assess the accuracy of B-mode, Doppler ultrasound, strain elastography, and 2D shear wave elastography criteria in differentiation between benign from malignant lymph nodes.

Methods A cross-sectional study included 60 patients with lymphadenopathy. B-mode, Doppler ultrasound, strain elastography, and 2D shear wave elastography criteria were assessed for accuracy, sensitivity, and specificity compared to the final histopathological diagnosis, whether by core biopsy, fine needle aspiration, or excision biopsy.

Results We assessed 60 patients in our study (20 benign and 40 malignant). Of these ultrasound criteria that achieved statistical significance, the highest accuracy was for elasticity ratio 88.9%, followed by strain ratio 83.8%. Also, the highest specificity was for an elasticity ratio of 80%, followed by strain score and strain ratio of 75% and 70%, respectively. Cortical asymmetry achieved the highest sensitivity, 100%, followed by strain ratio and elasticity ratio, with a sensitivity of 90% and 87.5%, respectively. However, cortical asymmetry had an extremely low specificity of 25%.

Conclusions Ultrasound elastography criteria achieved higher accuracy compared to conventional ultrasound. So it can be used as an effective imaging modality to differentiate between benign and malignant lymph nodes.

Keywords Lymphadenopathy, Accuracy, B-mode, Color Doppler, Ultrasound, Strain elastography, 2D shear elastography

*Correspondence:
Sahar Gamal Ibrahim
sahar.gamal1@med.menofia.edu.eg
[1] Department of Diagnostic, Interventional Radiology and Medical Imaging, Faculty of Medicine, Menofia University, Menofia 32511, Egypt

Background

Benign or malignant diseases can cause lymphadenopathy. Accurate diagnosis, whether by physical examination, imaging, or histopathological evaluation, should be

performed for planning the therapy and assessing prognosis, especially in malignancy [1].

A biopsy is the gold standard modality for differentiation between benign and malignant lymph nodes but with drawbacks due to its invasive nature. Ultrasound criteria, whether by B-mode or Doppler study, have been evaluated in lymphadenopathy differentiation aiming to reduce the number of needed biopsies; however, they revealed different accuracy, sensitivity, and specificity across different studies [2–4].

Ultrasound elastography (USE) is a noninvasive imaging modality that is sensitive to tissue stiffness with its two main types, strain elastography (SE) and shear wave elastography (SWE). Strain elastography (SE) is a qualitative technique that assesses the relative stiffness between one tissue and its surroundings. Shear wave elastography (SWE) is a quantitative method that estimates the value of tissue stiffness. It expresses it as meter/second or Kpa [5–8]. Malignant tissues become stiffer than the surroundings even in their early stages, so USE could be used for lymphadenopathy differentiation based on its ability to assess tissue stiffness. However, more studies should be done to assess its diagnostic accuracy [9, 10].

This study aimed to assess the diagnostic accuracy of B-mode, Doppler ultrasound, SE, and 2D SWE criteria in lymphadenopathy differentiation compared to the histopathological diagnosis.

Methods

Study population

A cross-sectional study included 60 patients in the Ultrasonography Unit at the Department of Diagnostic, Interventional Radiology, and Medical Imaging at Menofia University. The study was conducted from July 2021 to August 2022. Lymph nodes with any of these ultrasound criteria were included (short axis greater than 10 mm, cortical heterogenicity, lost central hilum, round-shaped lymph nodes or abnormal peripheral vascularity on Doppler study, lymphadenopathy that does not respond to medical treatment on clinician demand). In contrast, exclusion criteria were (massive lymphadenopathies larger than the screening area of the probe and cystic necrotic lymph nodes). The study was conducted after the faculty of medicine Ethical Committee for Human Research approval. Fully informed consent was taken from the patients after explaining the procedures.

Equipment and method

The ultrasound examination was performed by LOGIQ E10 (GE system) ultrasound machine using a linear transducer (9–12 MHz). It includes B-mode, Doppler ultrasound, SE, and 2D SWE. This was done by a radiologist of 20 years of experience in ultrasonography and 4 years of experience in elastography. The radiologist was blind about the final histopathological diagnosis.

B-mode ultrasound

Criteria assessed were long axis diameter, short axis diameter, long axis/ short axis ratio (L/S ratio), echogenic fatty central hilum whether present or lost, cortical echogenicity whether homogenous or heterogeneous, borders whether regular or irregular, cortical thickness and presence of cortical asymmetry (when its thickness was more than 3 mm).

Doppler ultrasound

The site of vascularity was assessed whether the peripheral, central, or mixed pattern on the power Doppler. The resistive index was also assessed on pulsed wave Doppler.

Strain elastography

It was performed by manual rhythmic compressions on the lymph node. The degree of compression was monitored on a scale of 1–7 on the device screen, and it was considered reliable when it reaches value of 6 or 7 which is an indicator of the adequate compression. Elastograms were examined in dual-mode with B-mode images. Region of interest included the entire lymph node and the surrounding tissues with a greater proportion than the node. Soft regions were coded with blue, hard regions with red, while regions with average stiffness were coded with green.

Strain score was assessed as followed:

- (score 1) hard red portion occupies less than 10% of the lymph node.
- (score 2) hard red portion occupies between 10 and 50% of the lymph node.
- (score 3) hard red portion occupies between 50 and 90% of the lymph node.
- (score 4) hard red portion occupies more than 90% of the lymph node.

Strain ratio (SR) was determined by the strain value of the surrounding (surrounding muscles or fat) divided by the strain value of the hardest red portion of lymph node at the same level. It was automatically calculated by the machine.

2D shear wave elastography

The transducer was lightly placed on the skin after using plenty of gel to acquire adequate-quality images. The probe was kept still until the color was constant in the color map for 5 s. The shear wave color code was similar to that used in strain elastography, as soft regions were coded with blue, while hard regions were red.

Three measurements of a 2-mm-diameter circle were recorded as follows:

- The first circle is upon the hardest red portion of the lymph node.
- The second circle is upon the rim of tissue surrounding the lymph node (perinodal rim tissue).
- The third circle is upon the surrounding fatty or muscular tissue.

The mean kpa and mean shear velocity of each of these three circles were automatically measured by the machine. The elasticity ratio was calculated by the Kpa of the intra-nodal hardest red portion divided by the Kpa of the surrounding tissues.

Final diagnosis by pathological analysis

The histopathological result was the reference standard for the final diagnosis of benign or metastatic lymph nodes. This was done with ultrasound-guided core biopsy, fine needle aspiration, or excision biopsy. This was performed by another radiologist of 15 years of experience.

Statistical analysis

Data were statistically analyzed using Statistical Package for the Social Sciences (SPSS) version 26 (SPSS Inc. Released 2018. IBM SPSS statistics for windows, version 26.0, Armnok, NY: IBM Corp). Qualitative data were expressed as Number (*N*) and percentage (%), while quantitative data were expressed as mean ($\bar{x}$), standard deviation (SD), and range (minimum–maximum). Analytic statistics were assessed by Student's t-test (*t*), Mann–Whitney's test (U), Chi-square test ($\chi 2$), and Fischer's Exact test. Receiver-operating characteristic (ROC) curves and the area under the curve (AUC) were constructed to illustrate various cut-off levels for quantitative parameters. AUC values are reported with a 95% confidence interval (CI). Significant test results were quoted as two-tailed probabilities. The significance of the obtained results was judged at 5%.

Results

This cross-sectional study included 60 patients (20 benign and 40 malignant). The mean age ranged from 6 to 83 years, with a mean of 49.8 ± 17.9. Regarding gender, there were 34 females (56.7%) and 26 males (43.3%). The mean age of patients with benign lymph nodes was lower than that of malignant lymph nodes (41.3 and 54.1 years, respectively) with statistical significance ($p = 0.014$). As regard gender, males constituted 55% of malignant lymph nodes, while females constituted 80% of benign lymph nodes, and this achieved statistical significance ($p = 0.010$).

Table 1 Histopathology of lymph nodes

		No	%
Benign			
Inflammatory		**8**	**13.3**
	Acute lymphadenitis	1	1.7
	TB	2	3.3
	Granulomatous non-caseating	5	8.3
Reactive	Non inflammatory, non-neoplastic	**12**	**20**
Malignant			
Lymphoma		**26**	**43.3**
	NHL	23	38.3
	HL	3	5
Metastasis		**14**	**23.4**
	Breast carcinoma	4	6.7
	Papillary thyroid carcinoma	2	3.3
	Bronchogenic carcinoma	1	1.7
	Squamous cell carcinoma	2	3.3
	Adenocarcinoma	1	1.7
	Undifferentiated carcinoma	4	6.7

The summation of numbers are shown in bold

Lymph nodes were at the cervical region in 37, the axilla in 14, and the inguinal region in 9 patients. Histopathological diagnosis was by core biopsy in 50, excision biopsy in 6, and fine needle aspiration in 4 lymph nodes. Different histopathological diagnoses are shown in Table 1

B-mode and Doppler ultrasound criteria between benign and malignant lymph nodes (Table 2)

B-mode and Doppler ultrasound criteria that achieved statistical significance were short axis, long axis/short axis ratio, cortical asymmetry, cortical thickness, and lost hilum: the mean short axis was 12.2 mm in benign lymph nodes. In contrast, malignant lymph nodes showed a significantly higher mean of 15.1 mm ($p = 0.013$). The L/S axis ratio was significantly higher in benign lymph nodes than malignant lymph nodes (1.9 vs. 1.7, $p = 0.034$). Cortical asymmetry was present in 75% of benign lymph nodes while in all malignant lymph nodes ($p = 0.003$). Mean cortical thickness was significantly higher in malignant lymph nodes compared to benign lymph nodes (13.7 mm and 8.1 mm, respectively, $p < 0.001$). Lost hilum was in 77.5% of malignant lymph nodes, which was higher than benign lymph nodes (45%) with ($p = 0.012$).

Table 2 Comparison between benign and malignant lymph nodes regarding B-mode and Doppler ultrasound criteria

		Benign (No = 20)		Malignant (No = 40)		Test of sig	*P*-value
		No	%	No	%		
Long axis (mm)	Mean ± SD	23.7 ± 9.6		24.9 ± 8.4		Mann–whitney 0.79	0.428
	Range	11.3–46.2		12.1–45.4			
Short axis (mm)	Mean ± SD	12.2 ± 4.4		15.1 ± 5.2		Mann–whitney 2.48	0.013*
	Range	6.1–23.1		7.0–28.7			
Long axis/short axis ratio	Mean ± SD	1.9 ± 0.6		1.7 ± 0.3		Mann–whitney 2.13	0.034*
	Range	1.2–3.7		1.2–2.5			
Cortical asymmetry	Present	15	75.0	40	100.0	10.91	[FE]0.003*
	Absent	5	25.0	0	0.0		
Cortical thickness	Mean ± SD	8.1 ± 4.6		13.7 ± 5.9		Mann–whitney 3.57	< 0.001**
	Range	2.5–19.0		4.0–28.7			
Borders	Regular	15	75	28	70	χ^2 0.16	0.685
	Irregular	5	25	12	30		
Homogenicity	Homogenous	11	55	18	45	χ^2 0.53	0.465
	Heterogeneous	9	45	22	55		
Hilum	Present	11	55	9	22.5	χ^2 6.34	0.012*
	Lost	9	45	31	77.5		
Vascularity	Central	5	25	4	10	χ^2 2.55	0.28
	Peripheral	9	45	24	60		
	Mixed	6	30	12	30		
Resistive index	Mean ± SD	0.7 ± 0.1		0.7 ± 0.1		*T* 1.42	0.161
	Range	0.51–0.76		0.55–0.84			

χ^2: Chi-square test, [FE]: Fischer's Exact test, *t*: student *t* test

* Significant ($P < 0.05$), **Highly significant ($P < 0.001$)

Table 3 Comparison between benign and malignant lymph nodes regarding ultrasound elastography criteria

		Benign (No = 20)		Malignant (No = 40)		Test of sig	*P*-value
		No	%	No	%		
Strain Elastography							
Strain score	Score 2	15	75	12	30	χ^2 11.827	0.003*
	Score 3	5	25	21	52.5		
	Score 4	–	–	7	17.5		
Strain ratio	Mean ± SD	2.1 ± 1.4		4.0 ± 1.4		Mann–whitney 4.24	< 0.001**
	Range	0.9–5.0		1.0–6.6			
Shear Wave Elastography							
Intra-nodal Kpa	Mean ± SD	106.9 ± 71.8		206.6 ± 100.2		Mann–whitney 3.638	< 0.001**
	Range	5.7–231.3		3.9–457.8			
Intra-nodal velocity (m/s)	Mean ± SD	5.5 ± 2.4		7.9 ± 2.3		Mann–whitney 3.646	< 0.001**
	Range	1.4–8.8		1.1–12.4			
perinodal rim Kpa	Mean ± SD	107.6 ± 70.0		159.9 ± 100.7		Mann–whitney 1.756	0.079
	Range	7.2–218.3		18.2–466.6			
perinodal rim velocity m/s	Mean ± SD	5.6 ± 2.3		6.9 ± 2.3		Mann–whitney 1.717	0.086
	Range	1.6–8.5		2.5–12.5			
Elasticity ratio	Mean ± SD	2.4 ± 3.4		11.3 ± 21.3		Mann–whitney 4.877	< 0.001**
	Range	0.2–16.3		1.1–125.3			

χ^2: Chi-square test, *Significant ($P < 0.05$), **Highly significant ($P < 0.001$)

Elastography criteria between benign and malignant lymph nodes (Table 3)

Strain elastography (SE) and shear wave elastography (SWE) criteria that achieved statistical significance were strain score, strain ratio, intra-nodal kpa, intra-nodal shear velocity, and elasticity ratio.

Strain score: scores 3 and 4 were present in 70% of malignant lymph nodes, which was higher than that of benign lymph nodes (25%, $p = 0.003$). The strain ratio mean was significantly higher in malignant lymph nodes compared to benign lymph nodes (4 and 2.1, respectively, $p < 0.001$) Figs. 1 and 2. The mean intra-nodal kpa in malignant lymph nodes was 206.6, significantly higher than in benign lymph nodes (106.9, $p < 0.001$). Intra-nodal velocity in malignant lymph nodes was 7.9 m/s, also higher than benign lymph nodes (5.5 m/s, $p < 0.001$). The elasticity ratio mean was significantly higher in malignant lymph nodes than benign lymph nodes (11.3 vs. 2.4, $p < 0.001$) Figs. 2 and 3.

Accuracy of B-mode, Doppler ultrasound, strain elastography, and 2D shear wave elastography criteria as predictors of malignancy (Table 4)

Those criteria that achieved statistical significance were assessed for accuracy, sensitivity, and specificity as follows:

The highest accuracy was for elasticity ratio (88.9%), followed by strain ratio (83.8%), then intra-nodal kpa or velocity achieved 79% accuracy, while the lowest accuracy was for L/S axis ratio (66.9%). The highest sensitivity was achieved by cortical asymmetry (100%), followed by strain ratio and elasticity ratio (90% and 87.5%, respectively), while the lowest sensitivity was for strain score (70%). The highest specificity was for elasticity ratio (80%)

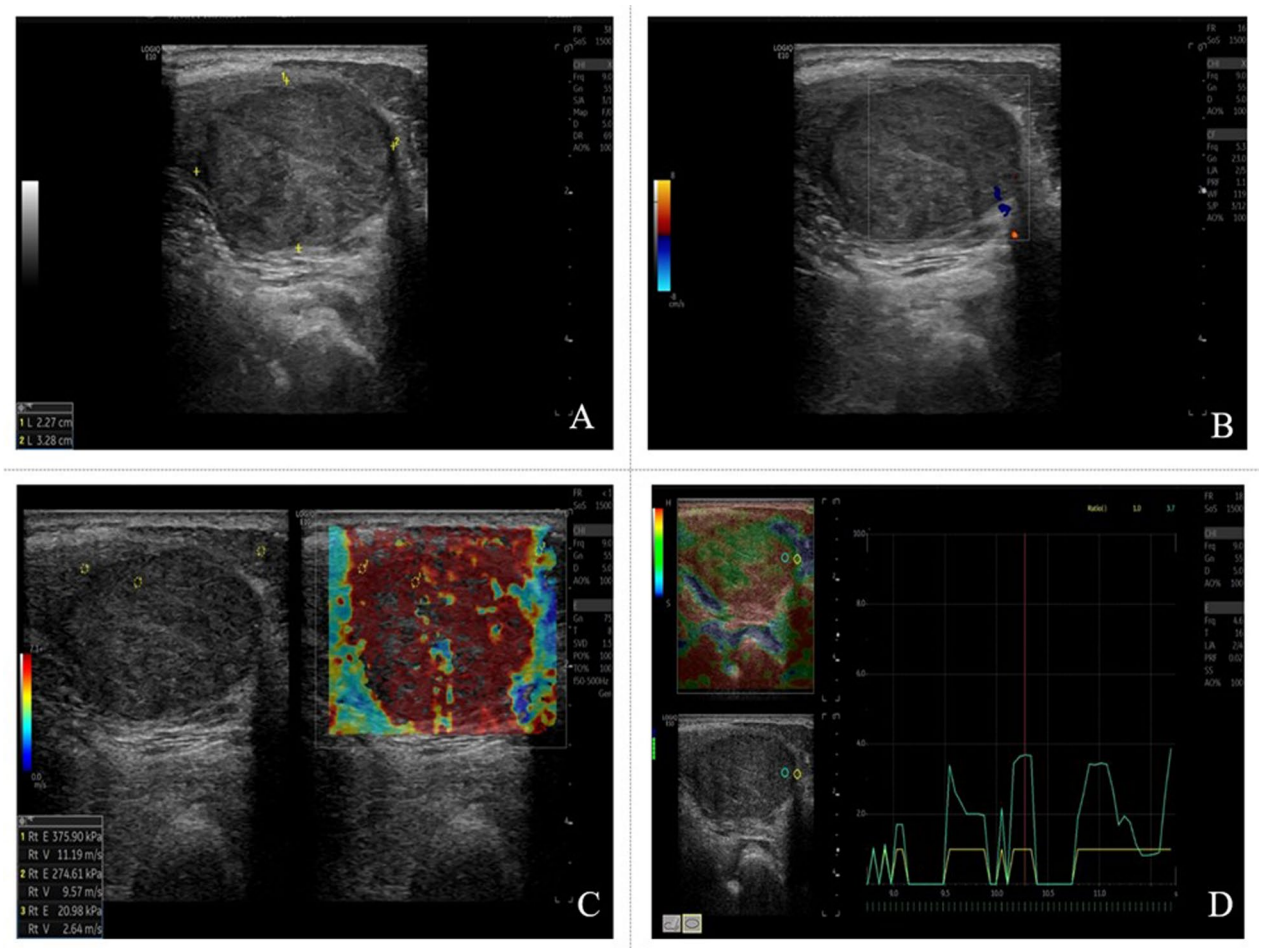

Fig. 1 **A** B-mode: the lymph node presented with heterogeneous echopattern, lost hilum and regular borders. It measured (32.8) mm in long axis, (22.7) mm in short axis and long axis/short axis ratio (1.44). **B** Doppler study, peripheral vascularity was noted. **C** Shear wave elastography: it presented with intra-nodal (375.9) kpa, intra-nodal velocity (11.19) m/s, perinodal rim tissue (274.61) kpa, perinodal rim tissue velocity (9.57) m/s and elasticity ratio (17.91). **D** Strain elastography: it showed strain score 2 and strain ratio (3.7). Pathology revealed metastatic undifferentiated carcinoma

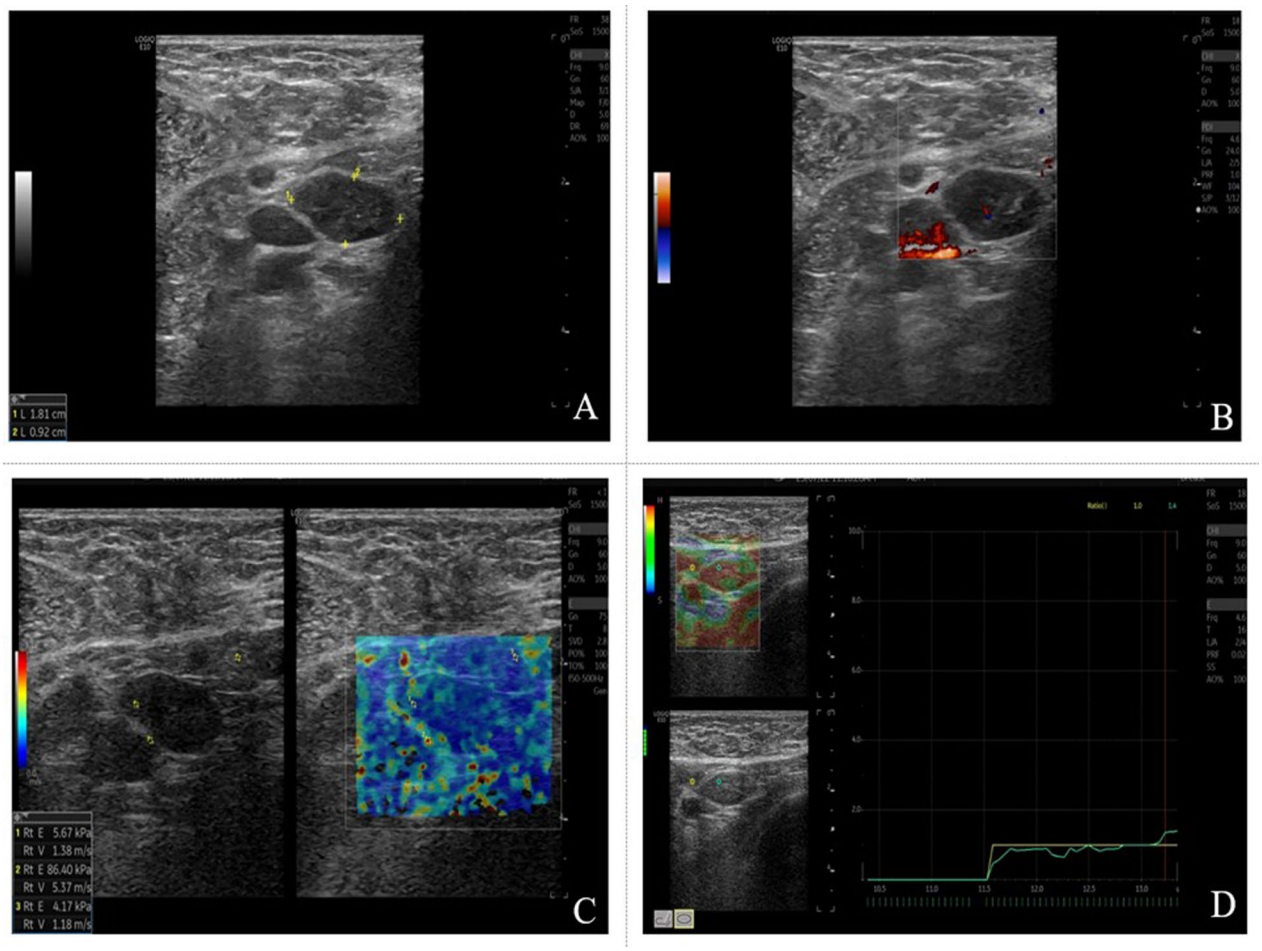

Fig. 2 **A** B-mode: it presented with heterogeneous echopattern, lost hilum and irregular borders. It measured (18.1) mm in long axis, (9.2) mm in short axis and long axis/short axis ratio (1.96). **B** Doppler study: central vascularity was noted. **C** Shear wave elastography: it presented with intra-nodal (5.67) kpa, intra-nodal velocity (1.38) m/s, perinodal rim tissue (86.4) kpa, perinodal rim tissue velocity (5.37) m/s and elasticity ratio (1.35). **D** Strain elastography: it showed strain score 3 and strain ratio (1.4). Pathology revealed reactive lymphoid hyperplasia

followed by strain score (75%) then strain ratio (70%), while the lowest specificity was for cortical asymmetry (25%). In summary, the elasticity ratio achieved the highest accuracy (88.9%) and the highest specificity (80%), while cortical asymmetry achieved the highest sensitivity, but it had extremely low specificity (25%). Receiver-operating characteristic (ROC) curve for quantitative data as a predictor of malignancy is shown in Figs. 4.

Discussion

Conventional ultrasound is frequently used as an initial noninvasive modality for assessing lymphadenopathy. However, its imaging criteria have different accuracy, sensitivity, and specificity in differentiating benign from malignant lymph nodes. A biopsy is the gold standard diagnosis investigation but has a drawback due to its invasive nature. In general, malignant tissue presents with a higher stiffness than benign one, so elastography could decrease the number of unnecessary biopsies based on its ability to detect tissue stiffness [4].

This study aimed to assess the diagnostic accuracy of B-mode, Doppler ultrasound, SE, and 2D SWE criteria in lymphadenopathy differentiation compared to the histopathological diagnosis.

In our study, males constituted 55% of malignant lymph nodes. This may be explained by our study's higher percentage of lymphoma (43.3% of patients). This was consistent with the previously reported higher incidence of lymphoma and also higher incidence of malignancy in males [11].

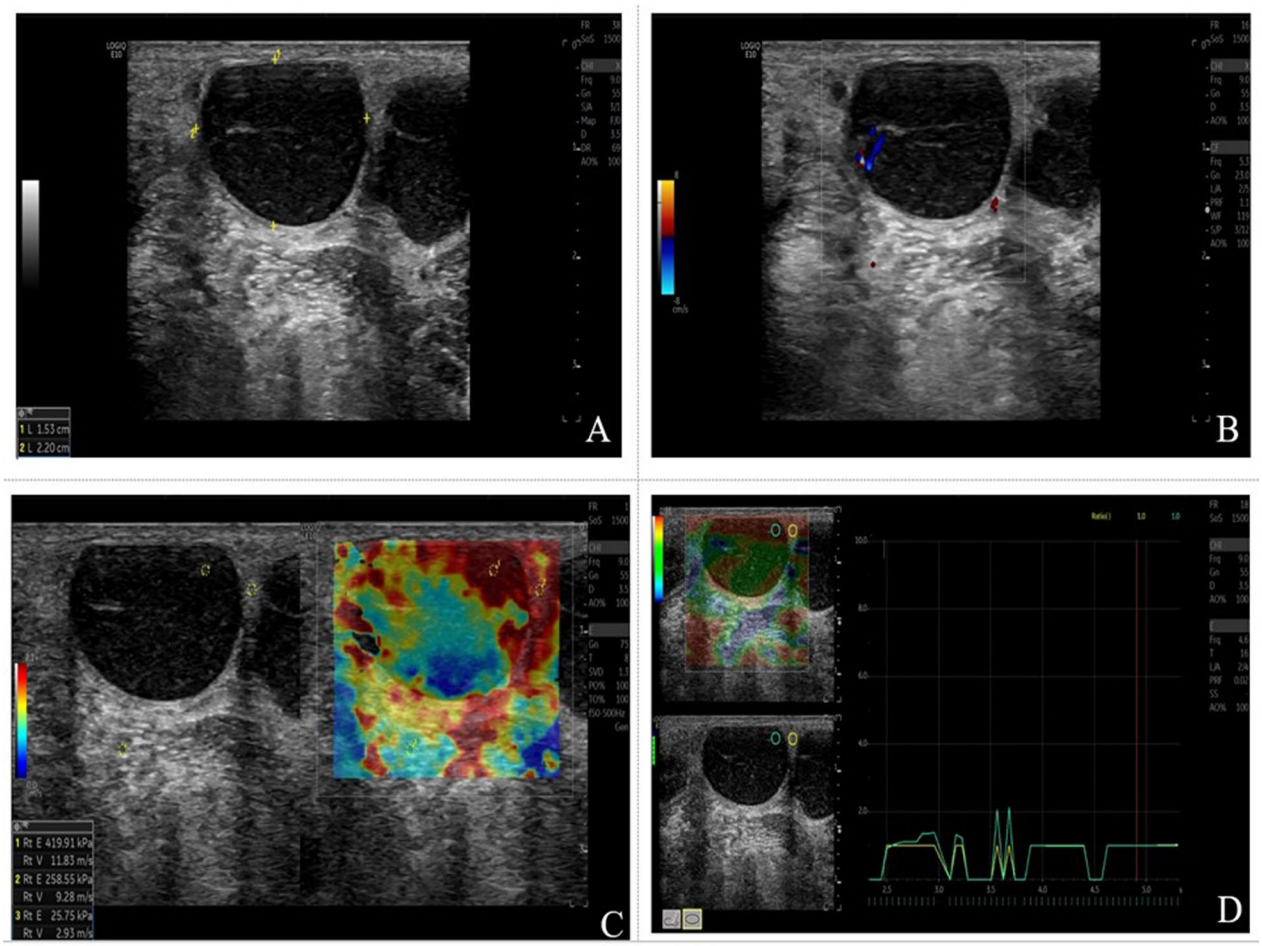

Fig. 3 **A** B-mode: it presented with homogenous echopattern, faint central hilum and regular borders. It measured (22) mm in long axis, (15.3) mm in short axis and long axis/short axis ratio (1.43). **B** Doppler study: central vascularity was noted. **C** Shear wave elastography: it presented with intra-nodal (419.91) kpa, intra-nodal velocity (11.83) m/s, perinodal rim tissue (258.55) kpa, perinodal rim tissue velocity (9.28) m/s and elasticity ratio (16.3). **D** Strain elastography: it showed strain score 2 and strain ratio (1). Pathology revealed Non-Hodgkin lymphoma

We assessed these criteria on B-mode and Doppler ultrasound (long axis, short axis, L/S axis ratio, cortical asymmetry, cortical thickness, borders, homogenicity, lost hilum, vascularity site, and resistive index).

Our study found a statistically significant ($P<0.001$) cortical thickness value with 78.4% accuracy. Consistent with our results, Gregory et al. found 70.1% accuracy ($P<0.0001$) and Monib et al. also reached 70.8% accuracy ($P=0.048$) [12, 13].

In the present study, we found that cortical asymmetry yielded the highest sensitivity (100%), but this had very low specificity (25%). Similar to our findings, Gregory et al. and Monib et al. reported low specificity (35.2%) and (33.3%), respectively [12, 13].

We found statistical significance ($P=0.012$) for lost hilum criteria with 70% accuracy. Matching our results, Rohan et al. and Kanagaraju et al. also stated 79.5% and 78% accuracy, respectively [2, 3]. Vineela et al. [14] inconsistent with our findings, achieved high diagnostic accuracy (73%) and high statistical significance ($P<0.0001$).

In this study, the L/S axis ratio reached 66.9% accuracy; however, low specificity was present (50%), and this had statistical significance ($P=0.034$). Vineela et al. [14] also found that its specificity was low at 38% as our results. Contrary to our results, Xu et al. and Kanagaraju et al. found no statistically significant difference [3, 15].

In the present study, we detected a statistically significant short-axis cut-off value of 10.5 mm ($P=0.013$) with

Table 4 B-mode, Doppler ultrasound, strain elastography and shear wave elastography criteria as predictors for malignant lymph nodes

	AUC	Cut-off point	Accuracy	P-value	Sensitivity	Specificity	PPV	NPV	95% CI
B-mode ultrasonography									
long axis (mm)	0.563	≥ 18.75	56.3%	0.428	80%	40%	72.7%	50%	0.40–0.73
Short axis (mm)	0.697	≥ 10.5	69.7%	0.013	82.5%	55%	78.6%	61.1%	0.55–0.85
Long axis/short axis ratio	0.669	≤ 1.96	66.9%	0.034	85%	50%	77.3%	62.5%	0.51–0.83
Cortical Asymmetry			75% (45/60)	0.003	100% (40/40)	25% (5/20)	72.7% (40/55)	100% (5/5)	
Cortical thickness	0.784	≥ 8.75	78.4%	< 0.001	82.5%	60%	80.5%	63.2%	0.66–0.91
Borders			45% (27/60)	0.685	30% (12/40)	75% (15/20)	70.6 (12/17)	34.9% (15/43)	
Homogenicity			55% (33/60)	0.465	55% (22/40)	55% (11/20)	71% (22/31)	37.9% (11/29)	
Hilum			70% (42/60)	0.012	77.5% (31/40)	55% (11/20)	77.5% (31/40)	55% (11/20)	
Doppler ultrasound									
Vascularity			68.3% (41/60)	0.145	90% (36/40)	25% (5/20)	70.6% (36/51)	55.6% (5/9)	
Resistive index	0.620	≥ 0.69	62.0%	0.132	70%	50%	73.7%	45.5%	0.48–0.76
Strain Elastography									
Strain score			71.7% (43/60)	0.003	70% (28/40)	75% (15/20)	84.8% (28/33)	55.6% (15/27)	
Strain ratio	0.838	≥ 2.25	83.8%	< 0.001	90%	70%	85.7%	77.8%	0.72–0.96
Shear Wave Elastography									
Intra-nodal Kpa	0.790	≥ 118.33	79.0%	< 0.001	82.5%	60%	80.5%	63.2%	0.67–0.91
Intra-nodal velocity (m/s)	0.790	≥ 6.28	79.0%	< 0.001	82.5%	60%	80.5%	63.2%	0.67–0.91
Elasticity shear ratio	0.889	≥ 2.59	88.9%	< 0.001	87.5%	80%	89.7%	76.2%	0.79–0.99
perinodal rim Kpa	0.640	≥ 122.18	64.0%	0.079	60%	60%	75%	42.9%	0.49–0.79
perinodal rim velocity m/s	0.637	≥ 6.35	63.7%	0.086	60%	50%	70.6%	38.5%	0.49–0.78

AUC: Area under the curve, CI: confidence interval, PPV: positive predictive value, NPV: negative predictive value

69.7% accuracy, 82.5% sensitivity, and 55% specificity. Vineela et al. [14] through using a short axis cut-off value of 8 mm, achieved high specificity 97% and statistical significance ($P = 0.0026$), but it had low sensitivity (30%) and 58% accuracy.

Contrary to our study, Xu et al. [15] showed no statistical difference.

We found no statistically significant difference when applying long-axis criteria as a predictor of malignancy. Gregory et al. [12] also found an extremely low sensitivity of 28%.

Regarding lymph node homogeneity, we found no statistically significant difference as a predictor of malignancy. Kanagaraju et al. [3] also stated similar results to ours with an accuracy of only 48%. Contrary to our results, Vineela et al. [14] achieved 67% accuracy with a statistically significant difference ($P = 0.0081$).

We found no statistically significant difference when applying border criteria as a predictor of malignancy. Similar to our observation, Xu et al. [15] found no statistical significance. Contrary to our study, Rohan et al. and Kanagaraju et al. found statistical significance ($P < 0.001$) [2, 3].

In the present study, neither site of vascularity in the Doppler study nor resistive reached a statistically significant difference. Contrary to our results, Kanagaraju et al. and Vineela et al. found statistical significance ($P = 0.010$ and 0.0004), respectively [3, 14]. Rohan et al. reached statistical significance ($P < 0.001$). However, low specificity (53%) was found [2].

Different findings between our study and previous studies could be related to the heterogenicity of diseases. Tanaka et al. [16] showed that the Doppler study in different lymph node pathologies presented different

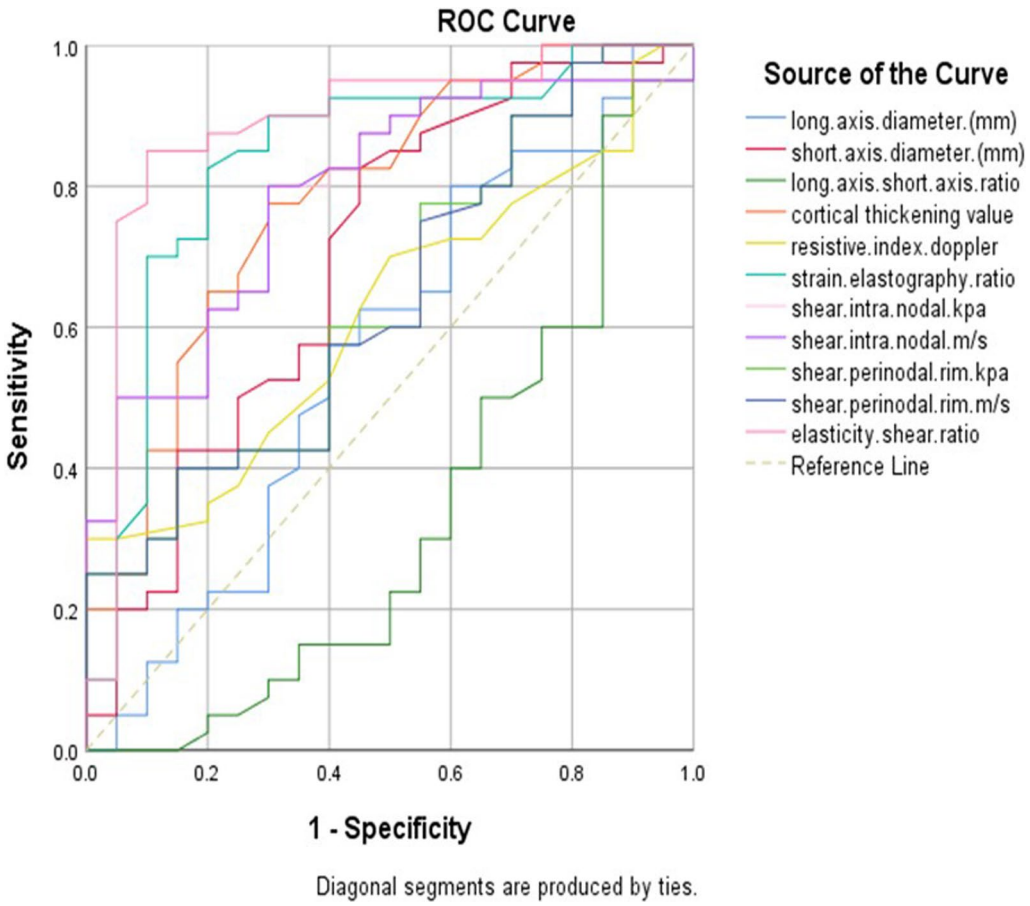

Fig. 4 ROC curve of all quantitative parameters as predictors for malignant lymph nodes

sensitivity, specificity, and accuracy. They reported accuracy (43%, 74%, and 76%) for Paget carcinoma, melanoma, and squamous cell carcinoma, respectively.

We assessed these criteria on SE and SWE (strain score, strain ratio, intra-nodal kpa or velocity, perinodal rim kpa or velocity, and elasticity ratio). The highest accuracy (88.9%) was for the elasticity ratio through using a statistically significant cut-off value ≥ 2.59 ($P < 0.001$).

Chanda et al. [17] inconsistent with our results, also showed a statistically significant difference ($P < 0.01$) for elasticity ratio using ≥ 1.5 as a cut-off value and with 74% accuracy. Youk et al. and Bae et al. also found statistical significance [9, 18].

In our study, the strain ratio reached 83.3% accuracy by applying a statistically significant cut of value ≥ 2.25 ($P < 0.001$).

Vineela et al. [14] found that strain ratio had statistical significance ($P < 0.00001$) with 94% accuracy through using cut-off value > 2. Also inconsistent with our results, Monib et al. and Xu et al. found statistical significance [13, 15].

Contrary to our findings, Ozel et al. found no statistically significant difference. This could be explained by the fact that the strain ratio is user dependent; it is also affected by the probe's degree of compression of tissues. The surrounding tissues selected as reference regions also affect the strain ratio. Different adjacent reference tissues are used as muscles in the neck, while fat is usually used in the axilla and inguinal regions [19].

A meta-analysis by Wang et al. [10] assessed different studies showed different accuracy between 75 and 95%.

In our study, shear wave intra-nodal kpa and velocity reached an accuracy of 79% when applying cut of value ≥ 118.33kpa and ≥ 6.28 m/s, respectively ($P < 0.001$).

Wang et al. meta-analysis assessed different studies and reported an accuracy range between 68.8 and 99% [10]. Li et al. published a meta-analysis including nine studies in which the pooled sensitivity and specificity of shear wave elastography were 87% and 88%, respectively. Different velocities between 1.9 and 4.6 m/s were used, which could be attributed to the heterogenicity of

involved lymph nodes, diseases, and different manufacturers [20].

In our study, using 4 point score, strain score (3 and 4) was a statistical significance parameter ($P = 0.003$) with 71.7% accuracy.

Different diagnostic accuracy of strain score was present between different studies as different score classifications were used. For this diversity, the accuracy range was between 64.1 and 88% [10].

Also, strain score accuracy varied between different diseases. Tanaka et al. study on different diseases in skin cancer found an accuracy of 100%, 82.6%, and 50% for squamous cell carcinoma, melanoma, and Paget carcinoma, respectively [16].

In our study, the assessment of kpa or velocity in the soft tissue rim around the lymph node periphery did not reach a statistically significant difference. This is contrary to the stiff rim sign used in diagnosing breast carcinoma [21].

There were limitations to our study: first, a larger sample size could improve the accuracy of results. Second, the diversity of diseases and different locations of examined lymph nodes were drawbacks. Another limitation was that different methods of elastography and different machines used in previous studies could alter the accuracy of results when comparing studies.

Conclusions

B-mode, Doppler ultrasound, SE, and 2D SWE criteria that achieved statistical significance were short axis, L/S axis ratio, cortical asymmetry, cortical thickness, lost hilum, strain ratio, strain score, intra-nodal kpa or velocity, and elasticity ratio. Among them, we found the highest accuracy for elasticity ratio followed by strain ratio, then intra-nodal kpa or velocity. So SWE and SE can be used as imaging modalities of higher accuracy than B-mode and Doppler ultrasound for differentiating between benign and malignant lymph nodes.

Abbreviations

USE	Ultrasound elastography
SE	Strain elastography
SWE	Shear wave elastography
L/S	Long axis/short axis
SR	Strain ratio
ROC	Receiver-operating characteristic
AUC	Area under curve

Acknowledgements

There is no acknowledgment.

Author contributions

MK, SG and MS contributed equally to study design, data collection, analysis, and interpretation of results. All authors read and approved the final manuscript.

Funding

There is no funding.

Availability of data and materials

Data will be available upon request via contacting the corresponding author.

Declarations

Ethics approval and consent to participate

All study procedures were conducted in accordance with the Declaration of Helsinki and were approved by the Ethical Committee of the Menofia faculty of medicine. All data were extracted after taking consent from patients involved in the study.

Consent for publication

Not applicable.

Competing interests

The authors declare that they have no competing interests.

Received: 28 March 2023 Accepted: 9 August 2023
Published online: 16 August 2023

References

1. Gaddey HL, Riegel AM (2016) Unexplained lymphadenopathy: evaluation and differential diagnosis. Am Fam Physician 94(11):896–903
2. Rohan K, Ramesh A, Sureshkumar S, Vijayakumar C, Abdulbasith KM, Krishnaraj B (2020) Evaluation of B-mode and color doppler ultrasound in the diagnosis of malignant cervical lymphadenopathy. Cureus. https://doi.org/10.7759/cureus.9819
3. Kanagaraju V, Rakshith AVB, Devanand B, Rajakumar R (2020) Utility of ultrasound elastography to differentiate benign from malignant cervical lymph nodes. J Med Ultrasound 28(2):92
4. Kartal Ö, Ataş E, Gürsel O (2020) Differentiation of benign from malignant cervical lymphadenopathy by ultrasonography in children. Archivos Argentinos de Pediatria 118(1):11–17
5. Sigrist RMS, Liau J, Kaffas AE, Chammas MC, Willmann JK (2017) Ultrasound elastography: review of techniques and clinical applications. Theranostics 7:1303–1329
6. Barr RG, Nakashima K, Amy D, Cosgrove D, Farrokh A, Schafer F et al (2015) WFUMB guidelines and recommendations for clinical use of ultrasound elastography: part 2: breast. Ultrasound Med Biol 41(5):1148–1160
7. Shiina T (2017) WFUMB guidelines and recommendations for clinical use of ultrasound elastography: part 1: basic principles and terminology. Ultrasound Med Biol 43:S191–S192
8. Ozturk A, Grajo JR, Dhyani M, Anthony BW, Samir AE (2018) Principles of ultrasound elastography. Abdominal. Radiology 43:773–785
9. Youk JH, Son EJ, Kim JA, Gweon HM (2017) Pre-operative evaluation of axillary lymph node status in patients with suspected breast cancer using shear wave elastography. Ultrasound Med Biol 43(8):1581–1586
10. Wang B, Guo Q, Wang JY, Yu Y, Yi AJ, Cui XW, Dietrich CF (2021) Ultrasound elastography for the evaluation of lymph nodes. Front Oncol. https://doi.org/10.3389/fonc.2021.714660
11. Siegel RL, Miller KD, Jemal A (2018) Cancer statistics. Cancer Surg 72(1):7–33. https://doi.org/10.3322/caac.21708
12. Gregory A, Denis M, Bayat M, Kumar V, Kim BH, Webb J et al (2020) Predictive value of comb-push ultrasound shear elastography for the differentiation of reactive and metastatic axillary lymph nodes: a preliminary investigation. Plos one 15(1):e0226994
13. Monib AM, Mikhail MKF, Mansour MG (2021) The role of ultrasound elastography in evaluation for axillary lymph nodes of patients with breast cancer. Med J Cairo Univ 89(June):519–527
14. Vineela E, Sakalecha AK, Suresh TN (2022) Role of sonoelastography in differentiating benign from malignant cervical lymph nodes and correlating with pathology. Cureus. https://doi.org/10.7759/cureus.22984

15. Xu Y, Bai X, Chen Y, Jiang L, Hu B, Hu B, Yu L (2018) Application of real-time elastography ultrasound in the diagnosis of axillary lymph node metastasis in breast cancer patients. Sci Rep 8(1):1–10
16. Tanaka T, Kamata M, Fukaya S, Hayashi K, Fukuyasu A, Ishikawa T et al (2020) Usefulness of real-time elastography for diagnosing lymph node metastasis of skin cancer: does elastography potentially eliminate the need for sentinel lymph node biopsy in squamous cell carcinoma. J European Academy Dermatol Venereol 34(4):754–761
17. Chanda R, Kandagaddala M, Moses V, Sigamani E, Keshava SN, Janakiraman R (2020) Role of ultrasound acoustic radiation force impulse in differentiating benign from malignant superficial lymph nodes. J Clin Imag Sci. https://doi.org/10.25259/JCIS_175_2019
18. Bae SJ, Park JT, Park AY, Youk JH, Lim JW, Lee HW et al (2018) Ex vivo shear-wave elastography of axillary lymph nodes to predict nodal metastasis in patients with primary breast cancer. J Breast Cancer 21(2):190–196
19. Özel D, Özel BD (2018) Evaluation of diagnostic value of conventional and color Doppler ultrasound with elastography strain ratios in differentiation between benign and malignant lymph nodes. Pol J Radiol 83:32–36
20. Li J, Chen M, Cao CL, Zhou LQ, Li SG, Ge ZK et al (2020) Diagnostic performance of acoustic radiation force impulse elastography for the differentiation of benign and malignant superficial lymph nodes: a meta-analysis. J Ultrasound Med 39(2):213–222
21. Xu YJ, Gong HL, Hu B, Hu B (2021) Role of "Stiff Rim" sign obtained by shear wave elastography in diagnosis and guiding therapy of breast cancer. Int J Med Sci 18(15):3615

Publisher's Note