Tantawy *et al. Egypt J Radiol Nucl Med* (2024) 55:11
https://doi.org/10.1186/s43055-024-01184-4

Egyptian Journal of Radiology and Nuclear Medicine

RESEARCH

Open Access

The diagnostic performance of ultrasound in the diagnosis of indeterminate adnexal masses based on the O-RADS US scoring system

Heba Fathy Ahmad Tantawy[1], Saeed Abdel Monem Ebrahim[1], Marwa Rashad Ahmad Kamal[2] and Rania Mostafa Hassan[1*]

Abstract

Background One of the most frequent reasons for gynecologic imaging is adnexal masses. The aim of the study is to assess the diagnostic performance of ultrasonography in the identification of ambiguous adnexal masses using the O-RADS US scoring system.

Methods This study included 108 cases and involved females with indeterminate adnexal masses, with any age group who were sent to the diagnostic ultrasonography department for evaluation of a worrisome adnexal mass lesion. We excluded patients who refused the examination despite informed discussion with the sonographer and patients with a previous history of operated adnexal lesion.

Results Based on the O-RADS US score, more than half masses (52.8%) were diagnosed as O-RADS 3, which is low-risk malignant, and 47.2% were diagnosed as O-RADS 4, being intermediate-risk malignant. Regarding US O-RADS categorization in relation to the reference results by pathology, 57 lesions were categorized as O-RADS 3 by the US, and 18 of them was diagnosed as malignant according to pathology. Out of 51 lesions categorized as O-RADS 4 by the US, 30 were diagnosed as benign by pathology. At cutoff 4, the O-RADS US score for malignancy gave a sensitivity of 93.13% (95% CI 25.13–80.78), specificity of 66.72% (95% CI 34.49–76.81), PPV of 93.18% (95% CI 26.07–58.16), and NPV of 75.42% (95% CI 52.13–81.17) with an overall accuracy of 92.56% (95% CI 38.10–72.06).

Conclusions In order to distinguish between benign and malignant neoplastic lesions, the US O-RADS classification system is a crucial non-invasive diagnostic tool for suspected ovarian tumors.

Keywords O-RADS, US, Indeterminate adnexal masses

Background

Adnexal masses are frequent, which leads to a heavy clinical workload for pathology, surgery, and diagnostic imaging. The majority of adnexal masses are benign and ultrasonography can reliably classify the majority of masses as benign or malignant [1].

However, even after ultrasonography utilizing simple rules or other ultrasonography grading systems, the diagnosis of 18–31% of adnexal masses remains uncertain [2].

Due to the possibility of upstaging a contained early-stage ovarian cancer or the risk of sample mistake leading to a missed cancer diagnosis, percutaneous biopsy of a suspected adnexal tumor is not recommended. Since only 8–20% of adnexal masses on ultrasonography are malignant, many women with sonographically ambiguous but

*Correspondence:
Rania Mostafa Hassan
Raniahassan@medicine.zu.edu.eg; Ronina7@hotmail.com
[1] Department of Radiodiagnosis, Faculty of Medicine, Zagazig University, Zagazig, Egypt
[2] Al Ahrar Teaching Hospital, Zagazig, Egypt

benign adnexal masses endure potentially lengthy surgical treatments that may be unnecessary [3].

Ultrasound is the most used imaging modality for assessing the uterus, fallopian tubes, and adnexa in females. Because of its widespread availability, lack of radiation and low cost, ultrasonography is now the gold standard for evaluating the female pelvis. When demonstrating gynecological anatomy or assessing physiological or pathological changes, ultrasound is typically the first and only imaging modality employed [4].

Ovarian ultrasound (US) is the gold standard imaging modality for detecting and characterizing ovarian tumors because of its ease of use and lack of invasiveness [5]. Results from US color Doppler may enhance morphological evaluation of ovarian cancer risk [6].

In 2020, the American College of Radiology (ACR) published a consensus article on the O-RADS classification, a technique for assessing the likelihood of malignancy in adnexal tumors. The O-RADS approach uses six criteria to assess the potential danger posed by adnexal masses, adnexal masses with score 3 and 4 are considered indeterminate masses [7] (Table 1).

The goal of the Ovarian-Adnexal Reporting and Data System (O-RADS) US risk stratification and management system is to standardize interpretations of US reports in order to reduce or eliminate ambiguity, thereby increasing the likelihood of accurately assigning the risk of malignancy to ovarian and other adnexal masses [8].

The purpose of this research was to evaluate the diagnostic performance of ultrasound using O-RADS US classification system in diagnosis of indeterminate adnexal masses.

Methods

Ethical consent

Academic and Ethical Committee approved the research (IRB Approval No. ZU-IRB#9240/12–1-2022). All participants agreed to participate in the research after signing an informed written permission form. The Declaration of Helsinki, a global standard for the ethical conduct of medical research involving human participants, has been followed throughout this project.

Population and study design

Between February 2022 and February 2023, this prospective study was conducted and included 108 patients with confidence interval 95%. We allocated patients from two hospitals who were sent to the diagnostic ultrasound unit, examined by a radiologist with 12-year experience in ultrasound and a radiologist with 5-year experience in ultrasound to evaluate a possible adnexal mass and Histopathologic diagnosis was the gold standard in patients managed by surgical treatment (57 lesions in our study). The other 39 lesions showed resolution and improvement on follow-up ultrasound or MRI scans.

- Inclusion criteria:

1. age 16–65 years old.
2. Female with sonographically indeterminate adnexal masses O-RADS US 3 & 4—according to the O-RADS US classification which was developed by an international multidisciplinary committee sponsored by the American College of Radiology-

ORADS US 3: low risk of malignancy (1 to < 10%)—needs a referral to ultrasound specialist or gynecologist with a view to MRI

- Unilocular > 10 cm (simple or non-simple) lesions looking like typical dermoids, endometriomas, or hemorrhagic cysts > 10 cm

Table 1 O-RADS US scores [9]

O RAD US score	Risk of malignancy	Descriptors
3	1 to < 10%	Mature teratoma/hemorrhagic cyst/endometrioma > 10 cm
		Unilocular cyst with irregular inner wall (< 3 mm height)
		Multilocular cyst < 10 cm with smooth inner wall, CS 1–3
		Solid smooth lesion, any size, CS 1
4	10 to < 50%	Unilocular cyst with solid component (0–3 papillary projections)
		Multilocular cyst > 10 cm with smooth inner wall, CS 1—3
		Any size with smooth inner wall, CS 4
		Any size with irregular inner wall and/or septation. any CS
		With solid component. CS 1—2
		Solid smooth lesion, any size, CS 2—3

- solid smooth lesion of any with color score 1
- multilocular cyst < 10 cm smooth inner wall with color score 1–3

O-RADS US 4: lesions with an intermediate risk of malignancy (10 to < 50%)—needs ultrasound specialist review or MRI as well as management by a gynecologist with gynecological oncology support or solely by a gynecological oncologist

- unilocular cyst with a solid component, any size, 1–3 papillary projections, any color score
- multilocular cyst with solid component, any size, color score 1–2
- multilocular cyst without solid component
    - > 10 cm, smooth inner wall with color score 1–3
    - any size smooth inner wall with color score of 4
    - any size with an irregular inner wall or irregular septations of any color score
- solid smooth lesion of any with color score 2–3

Exclusion criteria:

1. The patients who refused the examination despite informed discussion with the sonographer
2. patient with a previous history of the operated adnexal lesion.
3. O-RADS US 1: physiologic category (normal premenopausal ovary)
    - ovarian follicle (< 3 cm)
    - corpus luteum (< 3 cm)
4. O-RADS US 2: almost certainly benign category (< 1% risk of malignancy)
    - simple cyst 3–5 cm
        - premenopausal: no follow-up
        - postmenopausal: 1-year follow-up
    - simple cyst 5–10 cm
        - premenopausal: 8–12-week follow-up
        - postmenopausal: 1-year follow-up
    - non-simple but unilocular cyst with smooth margins 3–10 cm
        - premenopausal: 8–12-week follow-up
        - postmenopausal: refer to ultrasound specialist or MRI; management by a gynecologist
    - non-simple but unilocular cyst with smooth margins < 3 cm
        - premenopausal: no follow-up
        - postmenopausal: 1-year follow up if referring to ultrasound specialist or MRI management by a gynecologist
    - lesions with "classical ultrasound characteristics" of the following but may have specific recommendations and measure < 10 cm:
        - typical hemorrhagic cyst
        - dermoid cyst
        - endometrioma
        - paraovarian cyst
        - peritoneal inclusion cyst
        - hydrosalpinx
5. O-RADS US 5: lesions with a high risk of malignancy (≥ 50%)—needs a referral to a gynecological oncologist
    - presence of ascites/peritoneal nodularity
    - unilocular cyst with 4 or more papillary projections
    - multilocular cyst with a solid component—color score 3–4
    - solid lesion—smooth outer contour, any size, color score 2–3
    - Solid irregular lesion of any size

U/S protocol and technique

All US tests were done using the same system (a SonoScape S40 Exp/S40 Pro/S40/S35 Digital Color Doppler ultrasound system) to rule out the probability of system-to-system variations in the ultrasound imaging, a trans-abdominal ultrasound was performed with a full bladder, or a trans-vaginal ultrasound was performed after UB evacuation. While the patient was lying supine, multidirectional sonograms were acquired using transducers with frequencies ranging from 2.5 to 8 MHz. Location, size, consistency, and clearly defined boundaries were used to classify each adnexal lesion. The vascularity of the lesion were evaluated using Power or color Doppler US, and to ensure the presence or absence of a solid component. Using the US O-RADS categorization system, we gave each lesion a score.

Reference standard

The US findings using the O-RADS classification system were correlated with surgical removal and pathology findings for suspicious masses, and the remaining O-RADS 3 (low risk malignancy) lesions in young premenopausal patients were referred for MRI assessment before the final clinical diagnosis was made.

Statistical analysis

SPSS version 28 (IBM Co., Armonk, NY, USA) was used for the statistical analysis. The parameters' quantitative mean, standard deviation (SD), and range were given. The percentage and frequency distributions were used to depict the qualitative variables.

The diagnostic efficacy of several tests was compared using ROC curves with area under the curve (AUC) (where AUC > 50% represents acceptable performance and AUC 100% is the optimum performance for the test). To be statistically significant, the P value has to be less than 0.05 with two tails.

Results

This prospective study included 108 females with sonographically indeterminate adnexal masses, with ages ranging between 16 and 62 years (mean age of 42.92 ± 13.01 years). Most patients (91.7%) were married. Out of 108 patients, 61.1% were premenopausal, as shown in Table 2.

As shown in Table 2, all 108 patients suffered from pain, more than half patients (63.9%) suffered from constipation or diarrhea, 44.4% had fever, 41.7% had palpable mass or increased abdominal volume, 22.2% had vaginal bleeding, and 19.4% had urinary symptoms.

As regards the origin of the studied lesions, 99 were adnexal (out of which, 69 were ovarian, 21 were tubo-ovarian, and 9 were in broad ligament) and 9 were non adnexal (uterine lesions) as shown in Fig. 1.

Over half of masses (52.8%) were classified as O-RADS 3 according to the O-RADS US stratification system which is low risk malignant as case in Fig. 2 and 47.2% were diagnosed as O-RADS 4 being intermediate risk malignant as case in Fig. 3, 4 and 5. Regarding US O-RADS classification in relation to the reference results by pathology, 57 lesions were categorized as O-RADS 3 by US, 18 of them were diagnosed as malignant according to pathology. Out of 51 lesions categorized as O-RADS 4 by US, 30 were diagnosed as benign by pathology as shown in Table 3.

In 44.4% of the investigated masses, no blood flow was detected using the color doppler score, which was based on the strength of the color signal, minimal flow in 36.1%,

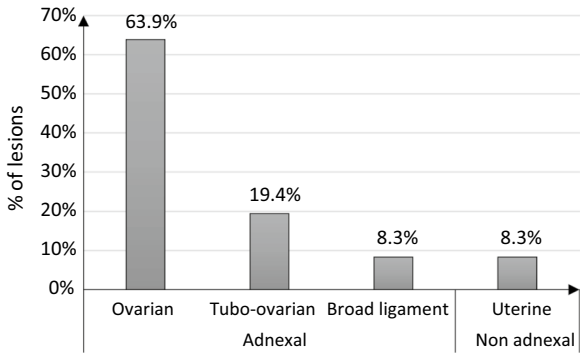

Fig. 1 Origin of lesions detected in the studied patients

Table 2 Baseline characteristics and symptomatology of the studied patients ($n = 108$)

		Total patients ($n = 108$)
Age (years)	Mean ± SD	42.92 ± 13.01
	Range	16–62
Marital status	Unmarried	9 (8.3%)
	Married	99 (91.7%)
Menstrual state	Premenopausal	66 (61.1%)
	Postmenopausal	42 (38.9%)
Symptomatology	**N**	**%**
Pain	108	100.0%
Constipation or diarrhea	69	63.9%
Fever	48	44.4%
Palpable mass or increased abdominal volume	45	41.7%
Vaginal bleeding	24	22.2%
Urinary symptoms	21	19.4%

Data are presented as frequency (%) unless otherwise mentioned

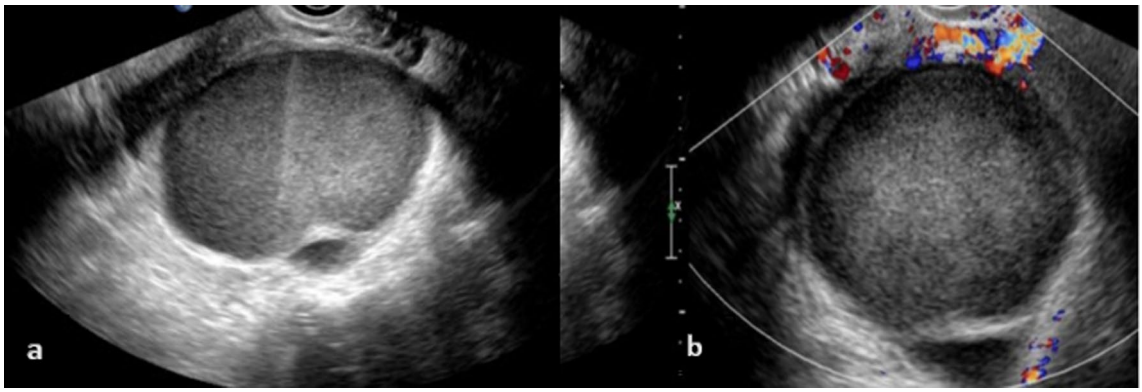

Fig. 2 A 37-year-old female patient presented with pelvic pain, fever, and leukocytosis. **a** transvaginal ultrasound showing left adnexal well defined bilocular cystic lesion of turbid content measures about 5 × 3 cm. **b** color Doppler study shows peripheral vascular activity. Scoring: O-RADS US 3 color Score 2. Diagnosis by pathology: tubo-ovarian abscess

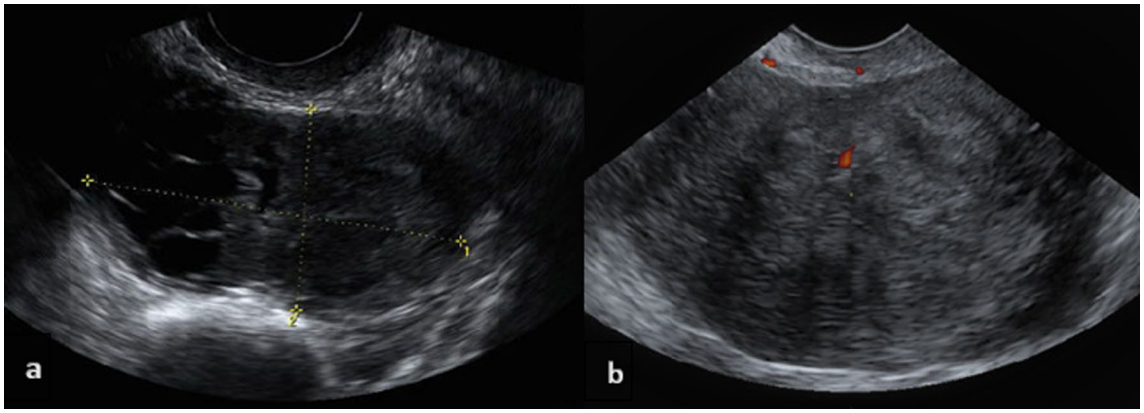

Fig. 3 A 16-year-old female patient presented with pelvic pain and abdominal distension. **a** Large left pelvi-abdominal mixed soft tissue/cystic mass lesion measures about 8 × 10 cm the cystic component is multiloculated with turbid content & thick internal septations **b** power doppler study showing internal flow is detected. Scoring: O-RADS US 4— color score 2. Diagnosis by pathology: left ovarian juvenile granulosa cell tumor

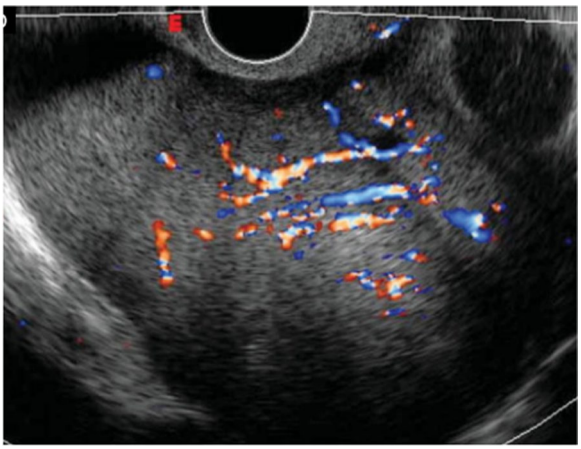

Fig. 4 A 52-year-old female patient presented by postmenopausal bleeding transvaginal ultrasound reveals large pelvic right soft tissue mass lesion measures about 10 × 7 cm with moderate vascular activity on color doppler. Score: O-RADS US 4, color score = 3. Diagnosis by pathology: pedunculated subserous leiomyosarcoma

moderate flow in 11.1%, and high vascular flow in 8.3% as shown Fig. 6.

At cutoff 4, the O-RADS US score for malignancy gave a sensitivity of 93.13% (95% CI 25.13–80.78), specificity of 66.72% (95% CI 34.49–76.81), PPV of 93.18% (95% CI 26.07–58.16), and NPV of 75.42% (95% CI 52.13–81.17) with an overall accuracy of 92.56% (95% CI 38.10–72.06) as summarized in Table 4.

Discussion

When an adnexal lesion is noticed on pelvic ultrasound examination, the objective is to classify this lesion as benign versus potentially malignant when it is found during a pelvic ultrasound examination to help with the necessary follow-up, which may include a possible referral to gynecology oncology. To further assist radiologists in classifying and recommending treatment for women with adnexal lesions, the ACR O-RADS Committee has

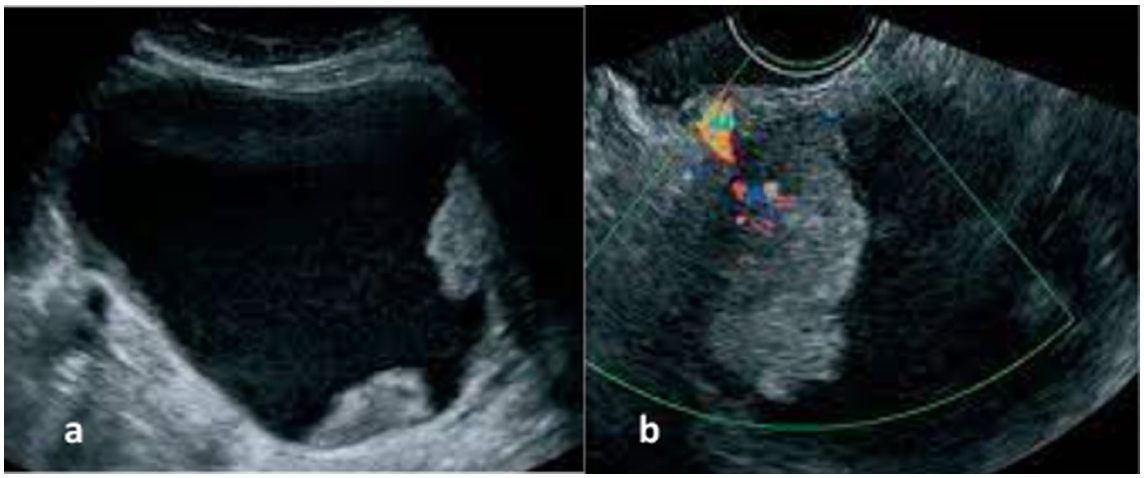

Fig. 5 A 49-year-old female patient presented by irregular bleeding and pelvic pain **a** TAS shows unilocular left adnexal complex cystic lesion with solid component noted anterosuperior score: O-RADS US 4 CS:2. Diagnosis by pathology: endometrioid adenocarcinoma

Table 3 O-RADS classification by US in relation to pathology results

	US	
	O-RADS3 (likely benign)	**O-RADS4 (likely malignant)**
Benign	39 (36.1%)	30 (27.8%)
Malignant	18 (16.7%)	21 (19.4%)
Total	57 (52.8%)	51 (47.2%)

Data are presented as frequency (%)

Table 4 Diagnostic performance of O-RADS US score for malignancy according to pathology results

	Value	**95% CI**
Sensitivity	93.13	25.13–80.78
Specificity	66.72	34.49–76.81
PPV	93.18	26.07–58.16
NPV	75.42	52.13–81.17
Diagnostic accuracy	92.56	38.10–72.06

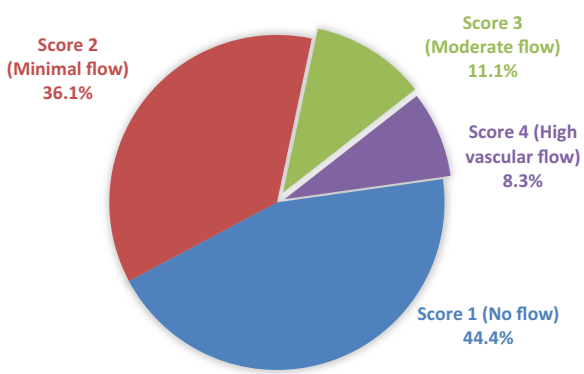

Fig. 6 O-RADS color score of the studied patients

released the O-RADS US Risk Stratification and Management System [10].

The current study included 108 females with sonographically indeterminate adnexal masses, with ages ranging between 16 and 62 years (mean age of 42.92 ± 13.01 years). Most patients (91.7%) were married. Out of 108 patients, 61.1% were premenopausal& 38.9% were postmenopausal.

Similarly, Hack et al. [11] performed research including all women who had pelvic US at a tertiary referral cancer hospital between August 2015 and April 2017. As many as 2801 pelvic US studies were found during the study period, and 227 individuals with 262 lesions (9 percent) were included. There was a wide range of ages represented, with 52 being the mean. In terms of when they entered and exited menopause, the breakdown was as follows: 113 (50% of the sample) were postmenopausal, 107 (47%) were premenopausal, and 7 (2% of the sample) were perimenopausal (3 percent) [11].

Also, AMOR. [12] found that adnexal masses were more common in postmenopausal elderly women [12].

In the current study, we found that all 108 patients suffered from pain, more than half of patients (63.9%) suffered from constipation or diarrhea, 44.4% had a fever, 41.7% had palpable mass or increased abdominal volume, 22.2% had vaginal bleeding, and 19.4% had urinary symptoms. This agreed with Bhagde et al. [13], who stated that about 92% of patients complained of stomach aches [13].

Furthermore, Givens et al. [14] showed that women with ovarian cancer most often have pelvic or abdominal discomfort [14].

On the other hand, ovarian cancer often has vague symptoms such as IBS, lethargy, and sudden weight loss [15, 16].

In the current study, we cleared that based on the O-RADS US score, more than half masses (52.8%) were diagnosed as O-RADS 3, which is low-risk malignant, and 47.2% were diagnosed as O-RADS 4 being intermediate-risk malignant.

Concurrently, Zhang et al. [17] examined 263 masses using U/S GIRADS and discovered that 86 of them were benign neoplasm (GI-RADS 3), while 101 were of GI-RADS 4 [17].

The GIRADS classification was used to determine the severity of 112 lesions, and the results showed that 32 lesions (28.6%) were GI-RADS 3, and 13 lesions (11.6%) were GIRADS 4 [14].

In the current study, we demonstrated that regarding US O-RADS classification in relation to the reference results by pathology, 57 lesions were categorized as O-RADS 3 by the US, and 3 of them was diagnosed as malignant according to pathology (false negative). Out of 51 lesions categorized as O-RADS 4 by the US, 42 were diagnosed as benign by pathology (false positive).

Our study results are in agreement with the results of the study done by Zhang et al. [17] results which found 4 false-negative malignant cases that were misclassified as GI-RADS3, whereas 24 benign lesions with false-positive results that were diagnosed as GI-RADS 4 [17].

In the current study, we demonstrated that based on pathology results which were the reference standard, 36.1% of the total adnexal masses were malignant.

Zhang et al. [17] results. They looked at 242 individuals with tumors of varying malignancy (110 cancerous and 153 benign) [17].

Unlike the findings of Pereira et al. [18], that identified a significant malignancy rate, with 90 (47.37%) of 190 masses meeting the criteria for malignancy based on histological examination [18].

Adnexal lesions with a typical appearance may be reliably detected and characterized by transvaginal sonography. But in the 2 biggest ovarian cancer screening studies, a considerable percentage of false-positive individuals received unnecessary surgery [19, 20]. The accuracy and specificity of an ultrasound examination may be diminished if the patient has nonclassical traits including avascular solid components, a big mass, or if the sonographer is inexperienced. The risk of malignancy index, the risk of ovarian malignancy algorithm, and other sonographic grading methods have all been endorsed. However, results have been mixed in actual clinical settings, maybe because of variations in operator experience and cancer prevalence within the study group [19, 20].

In this study, we found that at cutoff 4, the O-RADS US score for malignancy gave a sensitivity of 93.13% (95% CI 25.13–80.78), specificity of 66.72% (95% CI 34.49–76.81), PPV of 93.18% (95% CI 26.07–58.16), and NPV of 75.42% (95% CI 52.13–81.17) with an overall accuracy of 92.56% (95% CI 38.10–72.06).

There is a concordance between our findings and those of Prasad et al. [21], which came to the conclusion that histology and U/S O-RADS had excellent agreement for the diagnosis of benign and malignant ovarian tumors, with 100% sensitivity, 80% specificity, 36% PPV, and 100% NPV, at cutoff point 0.6 [21]. Our study had some limitations. The sample size was relatively small. This explains that our study did not include less common but not rare adnexal lesions, i.e., ovarian edema, ovarian torsion, and inflammatory ileocecal masses as a mimic of adnexal lesion. In addition, 57% of our patients had histopathological examination of their lesions, which is considered the definite diagnostic test. As the remaining patients (36%) were treated conservatively with regular follow-up with either regressive or stable lesions supporting the radiological diagnosis with MRI and TVUS examination.

Conclusions

The US O-RADS classification system is a crucial non-invasive diagnostic tool for suspicious ovarian masses with high sensitivity in differentiation between benign and malignant neoplastic lesions.

Abbreviations

AM	Adnexal masses
CI	Confidence interval
CS	Color scoring
GI-RADS	The Gynecologic Imaging-Reporting and Data System
NPV	Negative predictive value
O-RADS	Ovarian-Adnexal Reporting and Data System
PPV	Positive predictive value
US	Ultrasound
TVUS	Transvaginal

Acknowledgements

The author thanks all the study participants for their patience and support.

Author contributions

Study concepts and design were prepared by RH, HT, and SE. Literature research was discovered by RH and MK. Clinical studies was developed by MK. Experimental studies/data analysis was performed by RH and MK. Statistical analysis was conducted by MK and SE. Manuscript preparation was drafted by RH and MK. Manuscript editing was revised by HT. All authors read and approved the final manuscript.

Funding

No funding was obtained for this study.

Availability of data and materials

He datasets used and analyzed during the current study are available from the corresponding author on reasonable request.

Declarations

Ethics approval and consent to participate

This study was approved by the Institutional Review Board (IRB) of Zagazig University (IRB Approval No. ZU-IRB#9240/12–1-2022). A written informed consent from the patient before the study.

Consent for publication

All patients included in this research gave written informed consent to publish the data contained within this study.

Competing interests

The authors declare that they have no competing interests.

Received: 10 June 2023 Accepted: 29 December 2023
Published online: 08 January 2024

References

1. Urban RR, Pappas TC, Bullock RG, Munroe DG, Bonato V, Agnew K, Goff BA (2018) Combined symptom index and second-generation multivariate biomarker test for prediction of ovarian cancer in patients with an adnexal mass. Gynecol Oncol 150(2):318–323. https://doi.org/10.1016/j.ygyno.2018.06.004
2. Meys EMJ, Kaijser J, Kruitwagen RFPM, Slangen BFM, van Calster B, Aertgeerts B, Verbakel JY, Timmerman D, van Gorp T (2016) Subjective assessment versus ultrasound models to diagnose ovarian cancer: a systematic review and meta-analysis. Eur J Cancer 58:17–29. https://doi.org/10.1016/j.ejca.2016.01.007
3. Thomassin-Naggara I, Poncelet E, Jalaguier-Coudray A, Guerra A, Fournier LS, Stojanovic S, Millet I, Bharwani N, Juhan V, Cunha TM, Masselli G, Balleyguier C, Malhaire C, Perrot NF, Sadowski EA, Bazot M, Taourel P, Porcher R, Darai E, Reinhold C, Rockall AG (2020) Ovarian-Adnexal Reporting Data System Magnetic Resonance Imaging (O-RADS MRI) score for risk stratification of sonographically indeterminate adnexal masses. JAMA Netw Open 3(1):e1919896. https://doi.org/10.1001/jamanetworkopen.2019.19896
4. Mohaghegh P, Rockall AG (2012) Imaging strategy for early ovarian cancer: characterization of adnexal masses with conventional and advanced imaging techniques. Radiographics 32(6):1751–1773. https://doi.org/10.1148/rg.326125520
5. Gong Y, Wang Q, Dong L, Jia Y, Hua C, Mi F, Li C (2017) Different imaging techniques for the detection of pelvic lymph nodes metastasis from gynecological malignancies: a systematic review and meta-analysis. Oncotarget 8(8):14107–14125. https://doi.org/10.18632/oncotarget.12959
6. Manganaro L, Ciulla S, Celli V, Ercolani G, Ninkova R, Miceli V, Cozzi A, Rizzo SM, Thomassin-Naggara I, Catalano C (2023) Impact of DWI and ADC values in Ovarian-Adnexal Reporting and Data System (O-RADS) MRI score. Radiol Med 128(5):565–577. https://doi.org/10.1007/s11547-023-01628-3
7. Andreotti RF, Timmerman D, Strachowski LM, Froyman W, Benacerraf BR, Bennett GL, Bourne T, Brown DL, Coleman BG, Frates MC, Goldstein SR, Hamper UM, Horrow MM, Hernanz-Schulman M, Reinhold C, Rose SL, Whitcomb BP, Wolfman WL, Glanc P (2020) O-RADS us risk stratification and management system: a consensus guideline from the ACR Ovarian-Adnexal Reporting and Data System Committee. Radiology 294(1):168–185. https://doi.org/10.1148/radiol.2019191150
8. Carballo EV, Maturen KE, Li Z, Patel-Lippmann KK, Wasnik AP, Sadowski EA, Barroilhet LM (2022) Surgical outcomes of adnexal masses classified by IOTA ultrasound simple rules. Sci Rep 12(1):21848. https://doi.org/10.1038/s41598-022-26441-2
9. Ahmed H (2021) The usefulness of the ultrasound diagnosis of suspicious ovarian masses based on the O-RADS classification system. Al-Azhar Int Med J 6:1–6. https://doi.org/10.21608/aimj.2021.90943.1551
10. Crestani A, Theodore C, Levaillant J-M, Thomassin-Naggara I, Skalli D, Miaihle G, Dabi Y, Haddad B, Touboul C (2020) Magnetic resonance and ultrasound fusion imaging to characterise ovarian masses: a feasibility study. Anticancer Res 40(7):4115–4121. https://doi.org/10.21873/anticanres.14410
11. Hack K, Gandhi N, Bouchard-Fortier G, Chawla TP, Ferguson SE, Li S, Kahn D, Tyrrell PN, Glanc P (2022) External validation of O-RADS US risk stratification and management system. Radiology 304(1):114–120. https://doi.org/10.1148/radiol.211868
12. Amor F, Alcázar JL, Vaccaro H, León M, Iturra A (2011) GI-RADS reporting system for ultrasound evaluation of adnexal masses in clinical practice: a prospective multicenter study. Ultrasound Obstet Gynecol 38(4):450–455. https://doi.org/10.1002/uog.9012
13. Bhagde AD, Jani SK, Patel MS, Shah SR (2016) An analytical study of 50 women presenting with an adnexal mass. Int J Reprod Contracep Obstet Gynecol 6(1):262. https://doi.org/10.18203/2320-1770.ijrcog20164671
14. Zhang X, Meng X, Dou T, Sun H (2020) Diagnostic accuracy of transvaginal ultrasound examination for assigning a specific diagnosis to adnexal masses: a meta analysis. Exp Ther Med 20(6):1–1. https://doi.org/10.3892/etm.2020.9395
15. Ebell MH, Culp MB, Radke TJ (2016) A systematic review of symptoms for the diagnosis of ovarian cancer. Am J Prev Med 50(3):384–394. https://doi.org/10.1016/j.amepre.2015.09.023
16. Goff BA (2004) Frequency of symptoms of ovarian cancer in women presenting to primary care clinics. JAMA 291(22):2705. https://doi.org/10.1001/jama.291.22.2705
17. Zhang T, Li F, Liu J, Zhang S (2017) Diagnostic performance of the Gynecology Imaging Reporting and Data System for malignant adnexal masses. Int J Gynecol Obstet 137(3):325–331. https://doi.org/10.1002/ijgo.12153
18. Pereira PN, Yoshida A, Sarian LO, Barros RH de O, Jales RM, Derchain S (2022) Assessment of the performance of the O-RADS MRI score for the evaluation of adnexal masses, with technical notes. Radiologia Brasileira 55(3):137–144. https://doi.org/10.1590/0100-3984.2021.0050
19. Buys SS (2011) Effect of screening on ovarian cancer mortality. JAMA 305(22):2295. https://doi.org/10.1001/jama.2011.766
20. Jacobs IJ, Menon U, Ryan A, Gentry-Maharaj A, Burnell M, Kalsi JK, Amso NN, Apostolidou S, Benjamin E, Cruickshank D, Crump DN, Davies SK, Dawnay A, Dobbs S, Fletcher G, Ford J, Godfrey K, Gunu R, Habib M et al (2016) Ovarian cancer screening and mortality in the UK Collaborative Trial of Ovarian Cancer Screening (UKCTOCS): a randomised controlled trial. The Lancet 387(10022):945–956. https://doi.org/10.1016/S0140-6736(15)01224-6
21. Prasad S, Jha MK, Bharat I, Sehgal C (2019) Evaluation of ovarian masses by color doppler imaging and histopathological correlation. Int J Contemp Med Surg Radiol 4(2):66. https://doi.org/10.21276/ijcmsr.2019.4.2.22

Publisher's Note