Mosaad *et al. Egypt J Radiol Nucl Med* (2024) 55:28
https://doi.org/10.1186/s43055-024-01198-y

Egyptian Journal of Radiology and Nuclear Medicine

RESEARCH

Open Access

^{18}F-Fluorodeoxyglucose positron emission tomography [^{18}F-FDG PET CT] in assessment of patients with vocal cord paralysis [VCP] secondary to extra laryngeal neoplastic causes: How is it reliable?

Basant Mohamed Raief Mosaad[1*], Haytham Abdelkader[2], Tahany Rabie[1] and Moustafa Abdelkawi[3]

Abstract

Background The main cause of voice hoarseness is vocal cord palsy (VCP) that may be induced by many diseases that could be due to local laryngeal or extra laryngeal causes, including neoplastic and non-neoplastic entities. Normal vocal cords ^{18}F-fluorodeoxyglucose (FDG) activity should be symmetric and of low grade higher than the mediastinal background uptake. Vocal cords asymmetrical FDG uptake was a well-known finding in patients with VCP. When recurrent laryngeal nerve (RLN) palsy is suspected, FDG PET and computed tomography (CT) findings can give strong evidence of diagnosis, with ability to diagnose the underlying extra laryngeal neoplastic etiology. Our aim was to assess the sensitivity and accuracy of hybrid FDG PET CT scan in diagnosis of VCP secondary to an extra laryngeal neoplastic cause.

Methods A retrospective study for 50 patients, presented with hoarseness of voice, referred from Otorhinolaryngology department to outpatient clinical oncology units, with clinically suspected extra laryngeal neoplastic causes of VCP. Left lung cancer was detected in 52% of patients which was the most frequent cause, 10% had right lung cancer, 8% had thyroid cancer, 6% had mediastinal lymphoma, 6% had metastatic mediastinal lymph nodes from breast cancer, and 6% had esophageal carcinoma.

Results PET CT scan versus CT scan showed true positive results in (44 vs. 29 patient), true negative results in 5 patients in both scans, and false negative in (1 vs. 16 patient), with no false positive in either. Thus, the sensitivity, specificity, positive predictive value, negative predictive value, and accuracy for PET CT scan versus CT scan were 98% vs. 68%, 100% for both scans, 100% for both scans, 83.3% vs. 23.8%, and 86% vs. 56%, respectively.

Conclusions FDG PET CT scan plays an important role in diagnosis of oncology-related extra laryngeal causes of VCP, with higher sensitivity, negative predictive value, and accuracy than CT scan. FDG PET CT scan should be included in the workup of VCP if extra laryngeal oncological cause is suspected.

Keywords Vocal cord palsy, FDG PET CT, Hoarseness of voice

*Correspondence:
Basant Mohamed Raief Mosaad
basantraief@gmail.com
Full list of author information is available at the end of the article

Background

Hoarseness of voice is a general term, describing any change in the character of the voice. The main cause of hoarseness is vocal cord palsy (VCP) that could be induced by several laryngeal and extra laryngeal causes. Extra laryngeal causes of VCP include several mediastinal diseases, including neoplastic, inflammatory, postoperative sequel and vascular causes [1–3]. In patients with no obvious signs of laryngeal pathology, a variety of other clinical diseases affecting the innervation to the vocal cords may be sought. This obviously includes the identification of any extra laryngeal neoplasm [4].

The anatomical course of the vagus nerve and its branches is not identical on either side. It passes through jugular foramen vertically into the carotid sheath. Through its passage, several nerves arise, including the superior laryngeal and recurrent laryngeal nerves. The right recurrent laryngeal nerve (RLN) turns around the subclavian artery, whereas the left recurrent laryngeal nerve has longer course turning around the aortic arch to the aortopulmonary window and run upwards in the tracheoesophageal groove then it enters the larynx [2].

Vocal cord paralysis (VCP) can be caused by a wide range of diseases, including either in the larynx itself [intra laryngeal causes] or due to causes that can affect the vagus and/or recurrent laryngeal nerves [extra laryngeal causes]. Due to the familiarity of thoracic causes that can result in VCP, inclusion of the mediastinum [down to the level of the aortopulmonary window] in computed tomography (CT) is mandatory [3].

The normal fluorodeoxyglucose (FDG) uptake of the larynx is symmetric and of low-grade activity with mean standardized uptake value (SUV) in normal resting vocal cords reported as 1.77 [5]. If the patient vocalizes during or after FDG injection, this may result in symmetrical increased physiological uptake. Decrease [or loss] of the physiological FDG uptake in one of the vocal cords can be due to underlying VCP [6].

Lack of FDG physiological activity in the paralyzed cord and compensatory activation of the non-paralyzed vocal cord causes asymmetrical FDG uptake [7]. So, the workload of the non-paralyzed cord increases, and glucose consumption increases which is seen as an increased metabolic activity in the corresponding PET images [8].

In cases with clinical suspicion of RLN palsy, combining both FDG PET and CT scans represents strong diagnostic imaging procedures to confirm the diagnosis and to search for such extra laryngeal causes of RLN palsy, particularly, if there is other evidence of malignancy along the course of RLN. RLN palsy in the mediastinum has been described to occur with a number of neoplasms [6].

The length of the left RLN is more than double that of the right RLN; this predisposes the left RLN to a higher rate of injury from non-traumatic causes, such as neoplastic infiltration [6].

In our study, we aimed to study the structural and functional changes in the vocal cord using 18F-FDG PET/CT imaging in patients with extra laryngeal and thoracic neoplasms presented with hoarseness of voice.

Methods

The study was conducted on 50 patients from March 2019 till March 2021. All patients were referred to the PET CT unit of our Radiology department, from the outpatient clinical oncology units, due to hoarseness of voice, proven by laryngoscope done for all patients in the Otorhinolaryngology department as a vocal cord paralysis due to extra laryngeal cause.

We performed ^{18}F-FDG PET/CT study for all patients after obtaining informed written consent from the patients, and the study protocol was approved by the institutional research ethics committee. Inclusion criteria included adult patients presented with hoarseness of voice with clinically suspected extra laryngeal malignancy. Exclusion criteria included patients with previous history of vocal cord disease or thyroid surgery, patients with laryngeal lesions affecting the glottic, supra- or infra glottic regions, patients having higher blood sugar [more than 200 mg/dL], and patients having previous neck radiation.

Patient preparation

All patients fasted 6–8 h prior to the examination; blood glucose level was not exceeding 150 mg/dl at the time of the radiotracer injection (tested by Haemotest® check). Patients were instructed not to do any vigorous movements for 24 hours before the exam time to avoid exaggerated muscular uptake. Patients were instructed to keep calm before and during the scan. Patients were instructed to remain inactive after receiving FDG injection.

Scan protocol

All scans were performed using PET/CT system (Philips® Ingenuity TF128 multi-slice PET/CT; scanner; USA). The PET images were acquired (45–60 min) after IV injection of 0.1 mCi of ^{18}F-FDG/kg according to patients' weight adjustment.

A diagnostic contrast-enhanced CT scan was done first using the following parameters: 350 mA, 120 kV, 5-mm slice thickness, 0.5-s tube rotation time, and 8-mm table feed. An iodinated non-ionic contrast agent (like Omnipaque® 350) was administered intravenous

(100 ml) using an automatic injector, with an injection flow of 4 ml/s just before the beginning of the scan.

According to FDG PET/CT: EANM procedure guidelines for tumor imaging: version 2.0) [9]: PET/CT studies performed with the intention of assessing FDG uptake quantitatively should follow the following recommendations:

CT topogram, followed by deep-inspiration thoracic CT scan with a 20-s delay from the beginning of contrast agent infusion (this CT scan is used neither for attenuation correction nor for PET/CT image fusion), followed by whole-body diagnostic CT scan (with shallow breathing) with a 45-s delay after the thoracic CT scan (equilibrium or venous phase) if the thoracic CT scan was performed, or with a 60-s delay after the beginning of contrast agent infusion if the thoracic CT scan was not performed, followed by PET acquisition.

PET scan was done in supine position on the whole body from vertex to feet following CT scan. Several bed positions (5–7 in number) were performed and each with approximately 15-cm axial field of view per bed position with 4-mm in-plane spatial resolution and was covering the corresponding field of view of the CT. The time of acquisition emission data was about 2 min for each bed position and in time range 13–17 min.

Recommendations for FDG dose and administered activity (According to FDG PET/CT: EANM procedure guidelines for tumor imaging: version 2.0) [9].

The minimum recommended administered FDG activity and PET acquisition duration for each bed position must be adjusted so that the product of the FDG activity and PET acquisition duration is equal to or greater than the specifications set out below.

It recommended determining the minimum FDG administered dose in adults, by assuming a linear and a quadratic [10] relationship, respectively, between PET acquisition time per bed position, patient weight and recommended FDG activity as follows:

The minimum FDG administered activity calculated: FDG (MBq)=7 (MBq·min·bed−1·kg−1) × patient weight (kg)/emission acquisition duration per bed position (min·bed−1) [9].

An advanced PHILIPS workstation [Intelli Space portal] was used in postprocessing to view all CT, PET, and fused PET/CT images, and they were reconstructed in multi-planar reformation and viewed in different planes for all patients guided by "3D maximum intensity projection (MIP) images" PET image with the fused PET CT images being coded in *smart color map window* on PHILIPS portal workstation [better suppression of the physiological FDG background activity than thermal and rainbow color map].

The collected data were coded, tabulated, and analyzed; categorical variables (qualitative data) were presented as number and percentage; and descriptive analysis was done for numerical (quantitative) data.

Interpretation of PET/CT scans:

Interpretation of PET/CT images was done by two consultant radiologists with more than 5 years' experience. Initially, they started with neck axial CT and fused images passing through the two vocal cords, commenting on CT manifestation of VCP and assessing whether the vocal cord uptake was physiological uptake or lost. Then, they examined the MIP image to detect any pathological uptake followed by careful examination of the axial CT and axial fused PET images to detect the underlying etiology.

There is no single lower limit of the intensity of FDG uptake for the detection of abnormal uptake within lesions as it depends on the degree of contrast between the tumor and physiological high uptake in adjacent background in correlation to hepatic and mediastinum average FDG uptake.

PET/CT scan was considered positive in a patient with a biopsy verified cancer, and FDG avid tumor is identified along the expected course of vagal or recurrent laryngeal nerve, or close to the brain stem, or as a paraneoplastic phenomenon.

Scan reports were reviewed and compared to the clinical, diagnostic workup including biopsy and histopathology.

Quantitative analysis

To evaluate the FDG uptake pattern in paralyzed and non-paralyzed vocal cords seen by laryngoscope, it was assessed visually and quantitatively using the maximum body weight adjusted standardized uptake value (SUV max) which was evaluated by placing a spherical volume of interest over the vocal cord. The volume of interest was guided by CT and by PET images to avoid errors caused by miss registration.

Statistical analyses

Data were analyzed using Stata® version 14.2 (StataCorp LLC, College Station, TX, USA) and MedCalc© version 15.8 (MedCalc© Software bvba, Ostend, Belgium). Quantitative variables were described in the form of mean and standard deviation. Qualitative variables were described as number and percentages. Sensitivity, specificity, positive predictive value (PPV), negative predictive value (NPV), and accuracy with regard to malignancy, accompanied with Wilson score based 95% confidence intervals (CI), were calculated to determine the diagnostic performance of FDG PET/CT in detecting malignant lesions. Qualitative variables were compared using Chi-square

(x 2) test. Fisher's exact test was applied for testing differences in localization of VCP against presence/absence of cancer. The significance of the obtained results was judged at the (0.05) level.

Results

The study was conducted on 50 patients presented with hoarseness of voice, their ages ranged from 40 to 73 years (mean ± 57.14 years), 36 (72%) were males, and 14 (28%) were females. The right VCP palsy was detected in 12 patients (24%), while the left VCP was detected in 38 patients (76%).

Four patients (8%) had thyroid cancer (Fig. 1). Twenty-six patients (52%) had left lung cancer (Fig. 2), which was the most frequent cause of VCP. Five (10%) had right lung cancer. Three patients (6%) had lymphoma (Fig. 3), and other three cases (6%) presented with metastatic mediastinal lymph nodes from breast cancer. Three patients (6%) had esophageal carcinoma. The rest of cases presented with aortopulmonary window nodal malignancy, other metastatic mediastinal lymph nodes, right para hilar lung cancer, metastatic lymph nodes, and infiltrative tracheal neoplasm (Fig. 4) (one case for each 2%) (Table 1).

The agreement between hybrid PET CT and CT findings for patients presented with hoarseness of voice. There was moderate agreement between hybrid PET CT and CT findings ($\kappa = 0.226$) and was statistically significant ($p = 0.029$). Most of the patients (56%) had positive findings on both hybrid PET CT and CT, while only a few (10%) had negative findings on both tests. There was only one case where hybrid PET CT was negative, but CT was positive, suggesting that hybrid PET CT is more sensitive than CT (Table 2).

Hybrid PET CT scan versus CT scan showed true positive results in (44 vs. 29 patient) and true negative results in 5 patients in both scans, with no false positive in both scans and false negative in (1 vs. 16 patient). Thus, the sensitivity, specificity, positive predictive value (PPV), negative predictive value (NPV), and accuracy for PET CT scan versus CT scan were 98% vs. 68%, 100% for both scans, 100% for both scans, 83.3% vs. 23.8%, and 86% vs. 56%, respectively (Table 3).

Discussion

The main cause of hoarseness of voice is VCP that may be induced by many extra laryngeal mediastinal diseases, including neoplasia, inflammation, and postoperative and vascular conditions [7, 8]. CT of the neck and chest is usually performed in most of cases, including the mediastinum down to the level of the aorticopulmonary window (on the left side) or brachiocephalic artery (on the opposite side), to detect possible causes the can affect the course of the recurrent laryngeal nerves. VCP itself can be reliably identified at CT by recognizing key findings at the level of the true vocal cords and aryepiglottic folds. However, there are a number of VCP mimics and imaging pitfalls [8].

Normal laryngeal FDG activity during speech is symmetric and low grade. The lack of FDG activity in the paralyzed cord and compensatory activation of the non-paralyzed vocal cord causes asymmetrical FDG uptake seen in vocal cord paralysis [11–13]. The aim of the study was to confirm VCP and to assess the specificity and

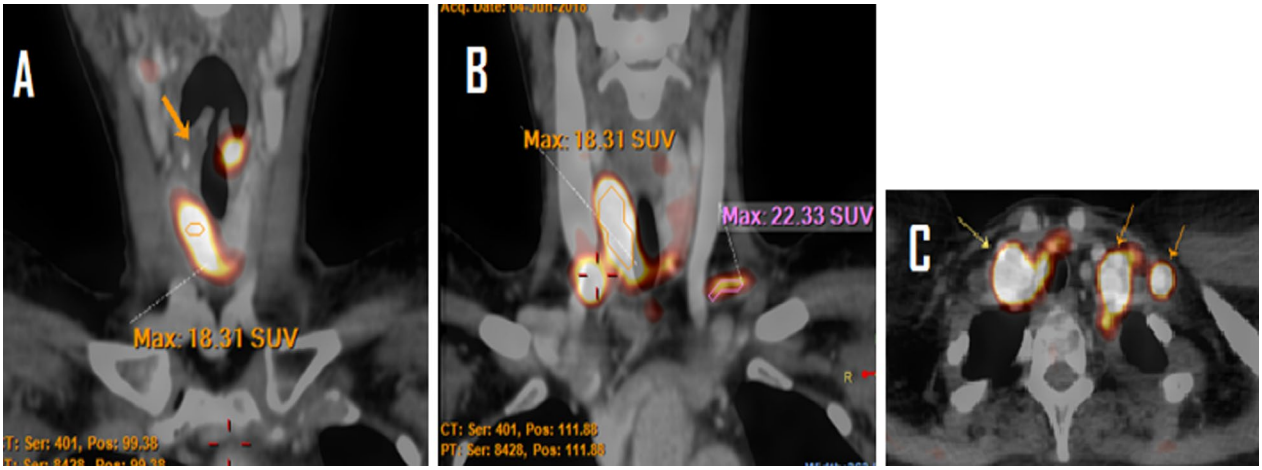

Fig. 1 A 54-year-old female patient presented with neck swelling and hoarseness of voice. **A** Coronal fused PET CT image revealed loss of physiological uptake of the right vocal cord [orange arrow] secondary to infiltrating soft tissue mass lesion related to the right lobe of thyroid gland extending to the isthmus achieving 18.31 SUV max (Coronal images; **A** and **B**). Axial fused PET CT in the lower neck (**C**) revealed regional metastatic avid lymphadenopathies at the supra clavicular and lower deep cervical nodal groups (thin yellow and orange arrows) achieving up to 22.33 SUV max

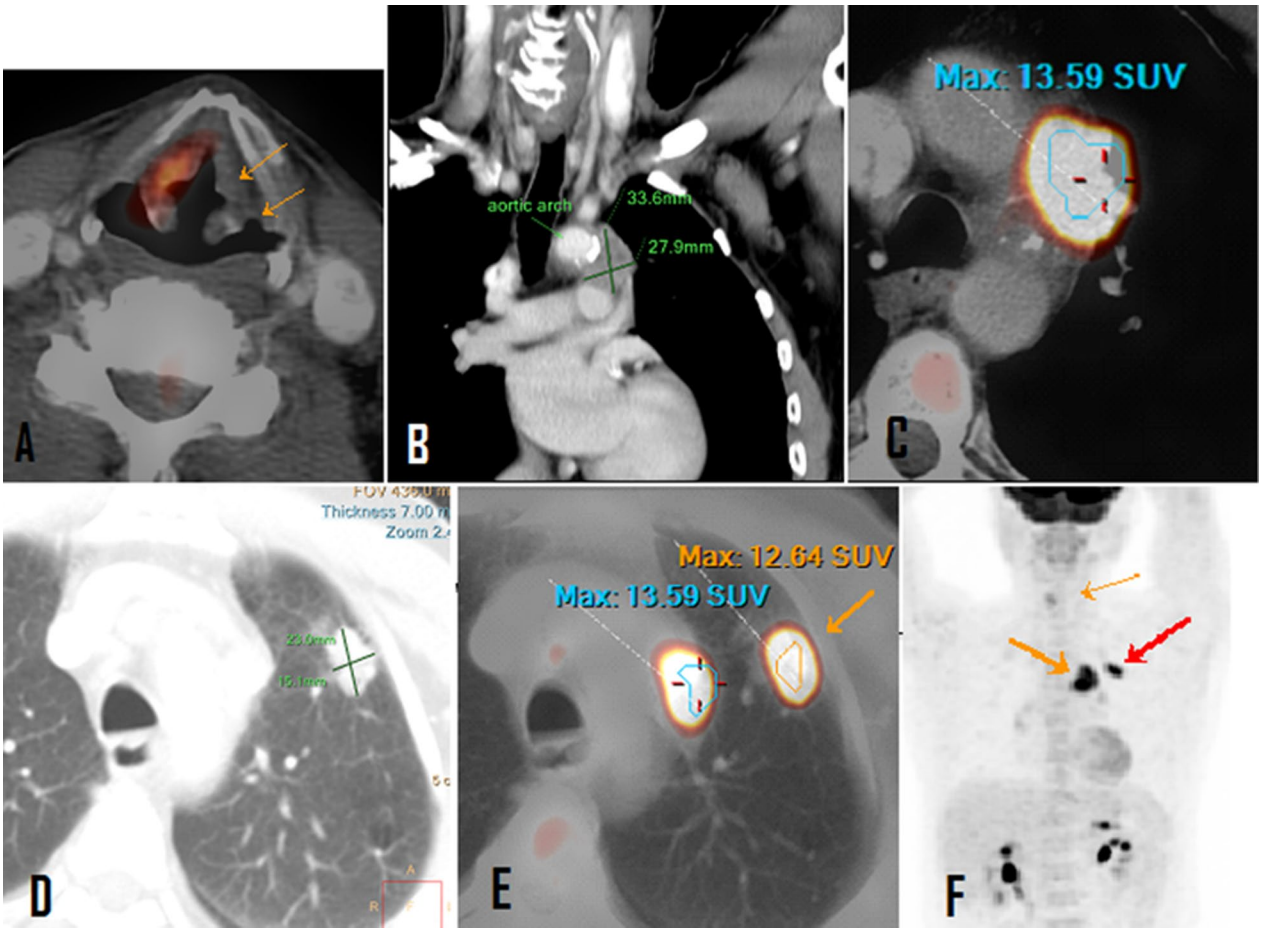

Fig. 2 A 62-year-old male patient presented with hoarseness of voice. (**A**) Fused axial PET CT image at the level of the vocal cords reveals loss of left vocal cord physiological activity (thin yellow arrows), due to an infiltrating avid nodal metastasis at the aortopulmonary (AP) window, measuring 33.6x27.9mm, achieving up to 13.59 SUV max (coronal CT image [**B**] and corresponding fused axial PET CT [**C**]), secondary to a small primary bronchogenic, speculated mass, 25x20 mm (axial CT [**D**] and corresponding axial fused PET CT [**E**]; (orange arrow) related to the anterior segment of the left upper lung lobe, achieving up to 12.64 SUV max. (**F**) MIP image revealed the primary lung mass [red arrow], metastatic AP window LN [orange thick arrow] and loss of left vocal cord activity [orange thin arrow]

sensitivity of FDG PET CT scan in the detection of VCP secondary to extra laryngeal and thoracic causes among patients presented with hoarseness of voice.

Oncology-related patients with clinically suspected unilateral vocal cord paralysis have hoarseness of voice which is reported in 90% of patients in our study. They suffer from change of voice pitch/quality and decrease in the loudness of their voice. The adduction inability of the affected vocal cord leads to a glottic gap which results in rough voice or breathlessness during speech with increased levels of voice fatigue with talking. This is also confirmed in other studies done by Ivey [14] and Richardson and Bastian [15].

Vocal cord paralysis leads to difficulty with heaving lifting or straining (due to an impaired Valsalva maneuver secondary to weak glottic closure). Some patients may suffer from cough, globus sensation, swallowing symptoms and/or choking which may be suggestive of aspiration [16, 17]. In such cases, high vagal injury with affection of both RLN and superior laryngeal nerve should be suspected, and this may help to differentiate between isolated RLN palsy and high vagal lesions and may also suffers from dysphagia for both solids and liquids and nasal regurgitation of oral intake. As time passed, some patients acquire compensatory mechanisms to overcome their reduced vocalization and choking.

Ivey [14] has reported that the length of the left RLN is more than double that of the right RLN, this predisposes the left RLN to a higher rate of injury from non-traumatic causes, such as neoplastic infiltration [10], and this matches with the results of our research which showed 76% affection of left vocal cord compared to 24% affection of right side [14].

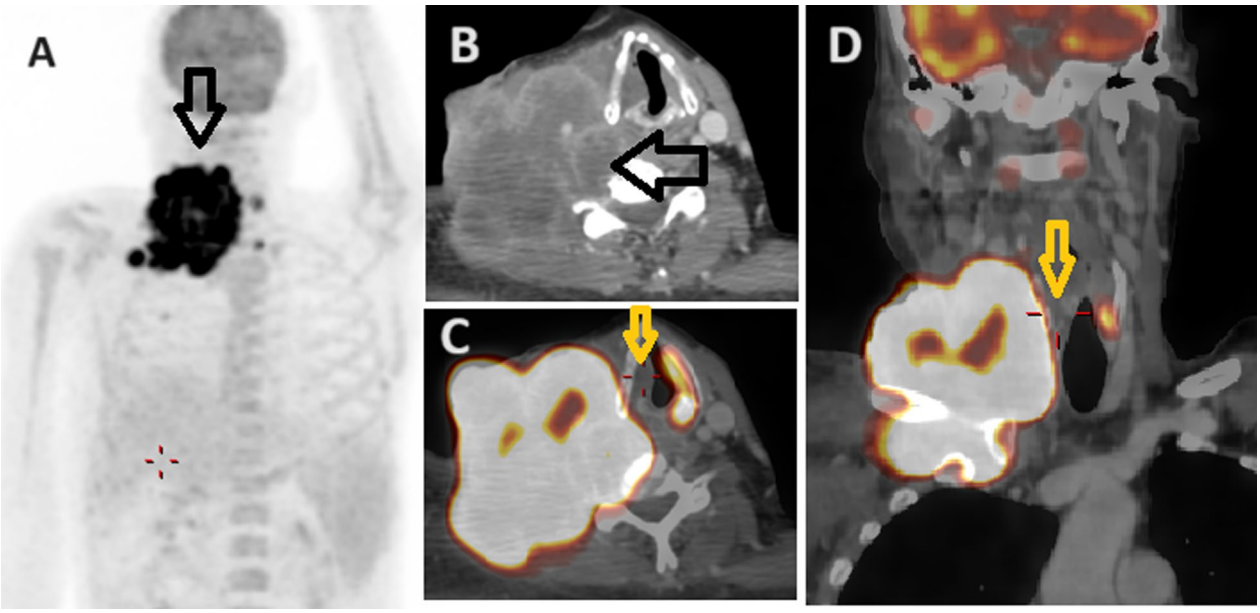

Fig. 3 A 60-year-old male patient presented with right neck swelling and hoarseness of voice. Axial CT [**B**], axial fused PET CT [**C**] and coronal fused PET CT [**D**] revealed amalgamated confluent FDG avid nodal mass lesions [levels III, IV, Vb and VII] with loss of physiological uptake of the right vocal cord [yellow arrow; **C** and **D**] achieving up to 25 SUV max. (**A**) MIP image revealed the enlarged amalgamated right deep cervical FDG avid nodal mass lesions [black thick arrow]. The lymphomatous lesions were pathologically proven to be non-Hodgkin's lymphoma

Unilateral VCP in patients with extra laryngeal malignancies has many causes [15]. The most important neoplastic lesion that can cause VCP is bronchogenic carcinoma. In a study done by Wang et al. [16], bronchogenic carcinoma was responsible for about 43% of cases of unilateral VCP [62 % of our cases included in the study had lung cancer which was the most frequent cause of VCP; 52% has left lung cancer and 10 % has right lung cancer]. VCP can be the initial reason for suspecting lung cancer. Wang et al. [16] reported also that neoplasm was the second most common cause of VCP.

Another study done by Knudsen et al. [17] also concluded that lung cancer was the most common etiology, 14 of 27 (52%).

A note is made of T-stage of bronchogenic carcinoma [TNM staging, 8th edition] depending mainly on the size of the lesion. The larger the tumor, the higher grade of the neoplasia. When there is unilateral VCP associated to lung cancer, the T-stage of the primary neoplasia will be upstaged into T4 regardless of the size of primary neoplasia [16–19]. We concluded that it is important to check the vocal cord activity in all cases scanned for bronchogenic carcinoma coming for FDG PET CT staging, as it can upstage the disease in many cases.

Other causes of VCP are reported in our study which includes 8% having thyroid cancer and 6% having other cancers [esophageal, lymphoma, and metastatic mediastinal nodes from breast cancer].

Clinical history should be taken in detail, as the non-neoplastic causes of unilateral VCP should be excluded, like iatrogenic traumatic injury of RLN palsy, history of thyroid surgery, carotid endarterectomy, and anterior approach for surgery to the cervical spine. Moreover, skull base operations are the most common procedures associated with this complication. Prior radiation, chemotherapy, or both should also be excluded as they can be potential causes of RLN palsy. Radiation therapy at high doses could lead to fibrosis with decreased vascularity to nerves in the radiotherapy field. Vagus nerve injury could occur in patients treated with radiation therapy to head and neck region up to 10 years later [20, 21].

Many CT findings must be noted in cases of clinically suspected unilateral vocal cord paralysis, as dilatation of the ipsilateral laryngeal ventricle, medial position of the posterior vocal fold margin, anterior position of the arytenoid cartilage, rotation and thickening of the ipsilateral aryepiglottic fold, ipsilateral dilatation of the pyriform sinus, and thyroarytenoid muscles atrophy [22].

Bilateral VCP is extremely rare. It has many causes like those that can lead to scarring of the vocal cords [like neck irradiation, prolonged intubation, caustic inhalation and scleroderma]. Also, central nervous causes [like strokes and extensive MS] can affect the vagal nuclei in the brain stem. Bilateral VCP leads to abducted median position of both vocal cords with

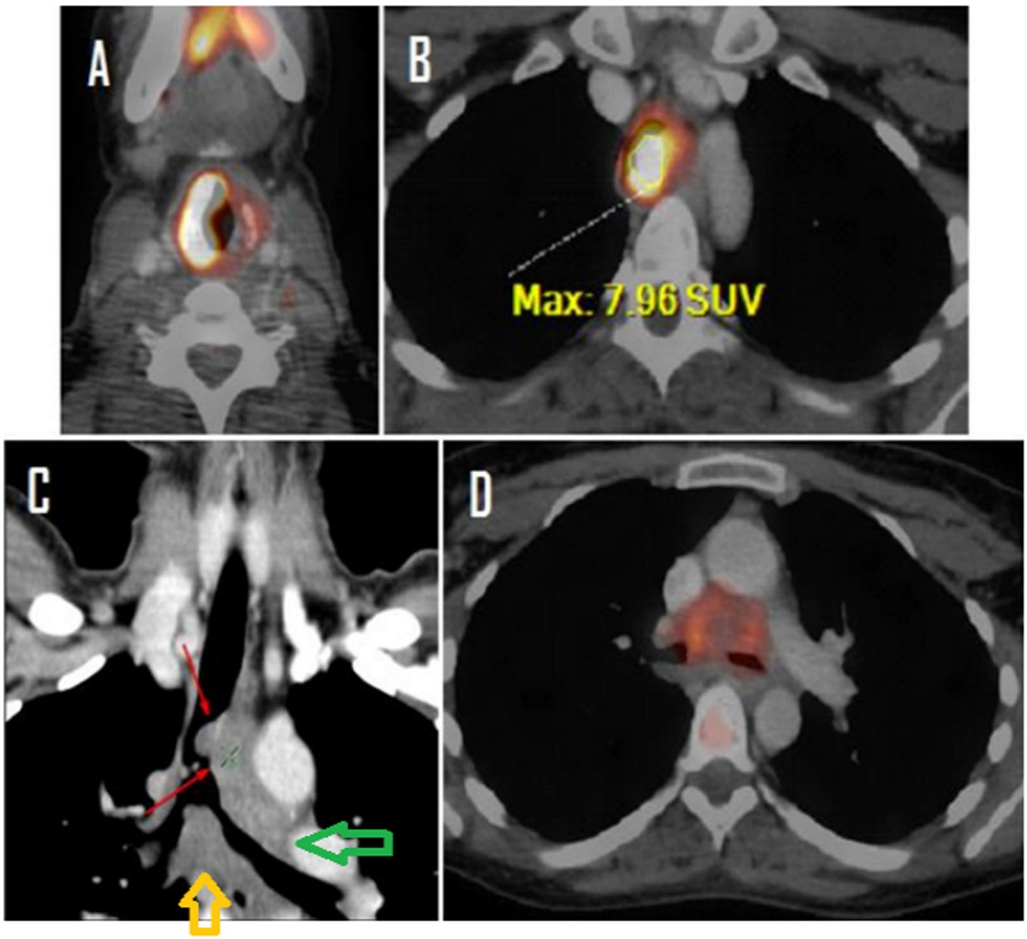

Fig. 4 A 52-year-old male patient presented with left vocal cord paralysis. **A** Axial fused PET CT image reveals loss of normal left vocal cord physiological uptake, secondary to intensely avid soft tissue mass lesion infiltrating the left lower lateral wall of trachea (axial fused PET CT image **B** and coronal CT; **C** image; red arrows) encroaching on its lumen achieving up to 7.96 SUV max merging with regional infiltrating left tracheobronchial, left hilar [green arrow] and subcarinal [yellow arrow] lymphadenopathies [**C** (coronal CT image) and **D** (axial fused PET CT image)]. Pathological assessment of the tracheal lesion proven to be adenoid cystic carcinoma

Table 1 The distribution of underlying malignancy for VCP

Diagnosis	No.	%
Right lung cancer	5	10.0
Left lung cancer	26	52.0
Thyroid cancer	4	8.0
Aortopulmonary cancer	1	2.0
Esophageal carcinoma	3	6.0
Lymphoma	3	6.0
Metastatic mediastinal LNs from breast cancer	3	6.0
Metastatic mediastinal lymphadenopathies	1	2.0
Right lung cancer with Metastatic mediastinal lymphadenopathies	1	2.0
Right parahilar lung carcinoma	1	2.0
Infilterative tracheal neoplasm	1	2.0
Metastatic lymph nodes	1	2.0
Total	50	100.0

subsequent inspiratory stridor that need urgent fibro-optic laryngoscopy for diagnosis [23].

Normal laryngeal FDG activity is symmetric and low grade. Symmetrical physiological vocal cords FDG increased uptake occurs if the patient speaks at or soon after injection of FDG due to increased metabolic uptake by contracting muscles related to phonation. The asymmetry of vocal cords uptake is more pronounced in acute and subacute conditions and becomes less observed and even loss of the FDG uptake with increasing duration of RLN palsy [7].

In our study, the CT accuracy (56%) and sensitivity (68%) were less than those of hybrid PET CT (86% and 98%, respectively); this matches with Thomassen et al, 2011, who also reported accuracy 88% (78–94%) and sensitivity 100% (88–100%) for PET CT scan [24].

Table 2 Agreement between CT and hybrid PET CT

	CT findings		Total	Agreement			
	Negative	Positive		%	Kappa	*p* value	Sig.
Hybrid PET CT							
Negative	5 (10%)	1 (2%)	6 (12%)	66.0%	0.226	0.029	S
Positive	16 (32%)	28 (56%)	44 (88%)				
Total	21 (42%)	29 (58%)	50 (100%)				

Table 3 Comparison between CT and hybrid PET CT parameters in reference to any positive result detected by either CT or PET CT

Parameter	TP	TN	FP	FN	Accuracy	Sensitivity	Specificity	PPV	NPV
CT findings	29	5	0	16	56.0	68	100	100	23.8
Hybrid PET CT	44	5	0	1	86.0	98	100	100	83.3

Sensitivity is the percentage of positive results detected by CT and PET CT out of the total positive results detected by either modality. According to this table, hybrid PET CT has a higher sensitivity than CT alone (98% vs. 68%) and a lower FN rate (1 vs. 16). This suggests that hybrid PET CT is more accurate and reliable than CT alone for detecting positive results.

Komissarovan et al. [6] had reported that in cases of unilateral vocal cord paresis the FDG uptake appears asymmetric with increased FDG uptake in the non-affected vocal cord opposite to the side of injured nerve; the mechanism is due to decreased glucose utilization in the paralyzed cord and compensatory increased workload of the contralateral normal vocal cord. It is important that this pattern cannot be misdiagnosed as a primary glottic neoplasm or as metastatic disease, both of which may present with unilateral increase.

Detection of cases with bilateral RLN palsy is difficult by PET CT alone based on the fact that in these cases the finding of asymmetric uptake could not be pronounced [6].

Usually, the patient is advised to rest and to withhold from speaking during the period of FDG uptake. Talking, coughing, or chewing after injection of the radiotracer element could lead to normal increased FDG uptake by tongue, pharyngeal muscles or larynx [6].

When RLN palsy is suspected clinically, the combination of FDG PET and CT findings can make a strong morphological and functional evidence of diagnosis of vocal cord paralysis, especially if there is additional evidence for etiological neoplasm along the pass of the RLN providing a possible mechanism for injury.

Rarity of the cases with VCP in patients treated for cancer besides the high cost of PET CT scan leads to small sample size of our study and considered as a limitation of the study, so further studies on larger sample size would be advised in the future studies.

Conclusions

Integrated morphological and functional diagnostic performance of FDG PET CT for patients with extra laryngeal causes of vocal fold paralysis gives higher accuracy, sensitivity, and negative predictive values over CT scan alone. PET CT scan should be included in the routine imaging work up of vocal cord palsy in all clinically suspected patients to have extra laryngeal neoplasia, particularly in cases of bronchogenic cancer and other head and neck malignancies occurring along the course of RLNs.

Abbreviations

^{18}F-FDG PET	^{18}Fluorine-fluorodeoxyglucose positron emission tomography
CT	Computed tomography
RLN	Recurrent laryngeal nerve
VCP	Vocal cord paralysis
SUV	Standardized uptake value
MIP	Maximum intensity projection
(AP) Window	Aortopulmonary window
NPV	Negative predictive value
PPV	Positive predictive value
TP	True positive
TN	True negative

Acknowledgements

Not applicable.

Author contributions

The authors contributed to the study conception and design. Material preparation, data collection, and data analysis were performed by all authors. The first draft of the manuscript was written by MMA and HA. TMR and BMR read and approved the final manuscript. All the authors read and approved the final manuscript.

Funding
This work has not received any funding.

Availability of data and materials
All data generated or analyzed during this study are included in this article.

Declarations

Ethics approval and consent to participate
The study protocol was approved by the Ethical Committee of Helwan University (Reference Number: 91-2022), and written informed consent was obtained from all patients to participate in the study.

Consent for publication
Written informed consent was obtained from all patients for publication of the study.

Competing interests
The authors declare that they have no competing interests.

Author details
[1]Faculty of Medicine, Ain Shams University, Cairo, Egypt. [2]Faculty of Medicine, Helwan University, Cairo, Egypt. [3]Radiodiagnosis Department, Faculty of Medicine, Helwan University, Cairo, Egypt.

Received: 4 September 2023 Accepted: 17 January 2024
Published online: 02 February 2024

References

1. Ulis JM, Yanagisawa E (2009) What's new in differential diagnosis and treatment of hoarseness? Curr Opin Otolaryngol Head Neck Surg 17:209–215
2. Van der Goten A (2004) Evaluation of the patient with hoarseness. Eur Radiol 14(8):1406–1415. https://doi.org/10.1007/s00330-004-2272-x
3. Paquette CM, Manos DC, Psooy BJ (2012) Unilateral vocal cord paralysis: a review of CT findings, mediastinal causes, and the course of the recurrent laryngeal nerves. Radiographics 32(3):721–740. https://doi.org/10.1148/rg.323115129. Erratum in: Radiographics, 2012 Nov–Dec;32(7):2166
4. Sorensen JR, Johansen J, Gano L, Sorensen JA, Larsen SR, Andersen PB, Thomassen A, Godballe CA (2014) "Package solution" fast track program can reduce the diagnostic waiting time in head and neck cancer. Eur Arch Otorhinolaryngol 271(5):1163–1170. https://doi.org/10.1007/s00405-013-2584
5. Nakamoto Y, Tatsumi M, Hammoud D, Cohade C, Osman MM, Wahl RL (2005) Normal FDG distribution patterns in the head and neck: PET/CT evaluation. Radiology 234:879–885
6. Komissarova M, Wong KK, Piert M, Mukherji SK, Fig LM (2009) Spectrum of 18F-FDG PET/CT findings in oncology related recurrent laryngeal nerve palsy. Am J Roentgenol 192:288–294
7. Fujimoto T, Itoh M, Tashiro M, Yamaguchi K, Kubota K, Ohmori H (2000) Glucose uptake by individual skeletal muscles during running using whole-body positron emission tomography. Eur J Appl Physiol 83(4–5):297–302
8. Purandare NC, Rangarajan V, Shah S (2007) Case report: right vocal cord paralysis detected by PET/CT in a case of esophageal cancer. Indian J Radiol Imaging 17(3):166–168
9. Boellaard R, Delgado-Bolton R, Oyen WJG, Giammarile F, Tatsch K, Eschner W, Verzijlbergen FJ, Barrington SF, Pike LC, Weber WA, Stroobants S, Delbeke D, Donohoe KJ, Holbrook S, Graham MM, Testanera G, Hoekstra OS, Zijlstra J, Visser E, Hoekstra CJ, Pruim J, Willemsen A, Arends B, Kotzerke J, Bockisch A, Beyer T, Chiti A, Krause BJ (2015) FDG PET/CT: EANM procedure guidelines for tumour imaging: version 2.0. Eur J Nucl Med Mol Imaging 42:328–354. https://doi.org/10.1007/s00259-014-2961-x
10. De Groot EH, Post N, Boellaard R, Wagenaar NR, Willemsen AT, van Dalen JA (2013) Optimized dose regimen for whole-body FDG-PET imaging. Eur J Nucl Med Mol Imaging Res 3(1):63. https://doi.org/10.1186/2191-219X-3-63
11. Thomassen A, Nielsen AL, Lauridsen JK, Blomberg BA, Hess S, Petersen H, Johansen A, Asmussen JT, Sørensen JR, Johansen J, Godballe C, Høilund-Carlsen PF (2014) FDG-PET/CT can rule out malignancy in patients with vocal cord palsy. Am J Nucl Med Mol Imaging 4(2):193–201
12. Thomassen A, Nielsen AL, Gerke O, Johansen A, Petersen H (2011) Duration of ^{18}F-FDG avidity in lymph nodes after pandemic H1N1V and seasonal influenza vaccination. Eur J Nucl Med Mol Imaging 38:894–898
13. Mehlum CS, Faber CE, Grontved AM (2009) Ugeskr Laeger; vocal fold palsy-etiology and outcome, vol 171, pp 109–112
14. Ivey CM (2019) Vocal fold paresis. Otolaryngol Clin N Am 52(4):637–648
15. Richardson BE, Bastian RW (2004) Clinical evaluation of vocal fold paralysis. Otolaryngol Clin N Am 37(1):45–58. https://doi.org/10.1016/s0030-6665(03)00179-8)
16. Wang H-W, Lu C-C, Chao P-Z, Lee F-P (2022) Causes of vocal fold paralysis. Ear Nose Throat J 101(7):NP294–NP298. https://doi.org/10.1177/0145561320965212
17. Knudsen R, Gaunsbaek MQ, Schultz JH, Nilsson AC, Madsen JS, Asgari N (2019) Vocal cord paralysis as primary and secondary results of malignancy: a prospective descriptive study. Laryngosc Investig Otolaryngol https://doi.org/10.1002/lio2.251
18. Mountain CF (2002) Staging classification of lung cancer. A critical evaluation. Clin Chest Med 23:103–121
19. Takalkar AM, El-Haddad G, Lilien DL (2008) FDG-PET and PET/CT—part II. Indian J Radiol Imaging 18(1):17–36. https://doi.org/10.4103/0971-3026.38504
20. Myssiorek D (2004) Recurrent laryngeal nerve paralysis: anatomy and etiology. Otolaryngol Clin N Am 37:25–44
21. Chen HC, Jen YM, Wang CH, Lee JC, Lin YS (2007) Etiology of vocal cord paralysis. J Oto-rhino-laryngol Its Relat Spec 69:167–171
22. Chin SC, Edelstein S, Chen CY, Som PM (2003) Using CT to localize side and level of vocal cord paralysis. Am J Roentgenol 180:1165–1170
23. Salik I, Winters R (2023) Bilateral vocal cord paralysis. StatPearls [Internet]. Treasure Island (FL): StatPearls Publishing. https://www.ncbi.nlm.nih.gov/books/NBK560852/
24. Thomassen A, Nielsen AL, Lauridsen JK, Blomberg BA, Hess S, Petersen H, Johansen A, Asmussen J, Sorensen JR, Johansen J, Godballe C, Carlsen PF (2014) FDG-PET/CT can rule out malignancy in patients with vocal cord palsy. Am J Nucl Med Mol Imaging 4(2):193–201

Publisher's Note