Fares and Mohammed
Egypt J Radiol Nucl Med (2024) 55:35
https://doi.org/10.1186/s43055-024-01201-6

Egyptian Journal of Radiology and Nuclear Medicine

CASE REPORT

Open Access

Breast metastasis from primary hand rhabdomyosarcoma

Nevien Ragae Fares[1*] and Tassnim Osama Mohammed[1]

Abstract

Background Rhabdomyosarcoma can occur almost anywhere in the body; however, the most common primary sites include the head and neck (50%), genitourinary tract (~25%), and extremities (~15%). Approximately 20% of rhabdomyosarcoma patients present with metastases at diagnosis, most commonly to the lungs, bone marrow, and lymph nodes. Rhabdomyosarcoma metastasizing to distant sites such as the breast highlights its aggressive behavior.

Case presentation A 20-year-old girl presented with left-hand swelling and pain which was unfortunately excised without imaging evaluation. Postoperative histopathology revealed a malignant spindle cell tumor. After two months, the patient complained of rapidly growing bilateral breast masses. As regards the patient's age diagnostic ultrasound was done that revealed bilateral breast masses with bilateral axillary lymphadenopathy (Fig. 1), and then, magnetic resonance imaging was done that revealed bilateral breast masses of malignant criteria and pathological left axillary lymph nodes (Fig. 2). An ultrasound-guided biopsy was taken from both breast masses which revealed a metastatic malignant spindle cell tumor. After immunophenotyping, the diagnosis of rhabdomyosarcoma is established. Unfortunately, a metastatic work-up was done that revealed a visceral and nodal metastasis as well as a myocardial deposit (Fig. 3).

Conclusions Metastasis of rhabdomyosarcoma to the breast is rare and occurs in young women as in our case with mainly primary site in limbs. It is important to be clinically aware of the risk of breast metastasis in female patients with primary extra-mammary rhabdomyosarcoma.

Keywords Metastasis to breast, Rhabdomyosarcoma, Breast malignancy

Background

Rhabdomyosarcoma, a malignant neoplasm arising from primitive mesenchymal cells, typically manifests in the skeletal muscles and can occur virtually anywhere in the body. Its most prevalent primary sites include the head and neck (approximately 50%), genitourinary tract (~25%), and extremities (~15%) [1]. The instances of rhabdomyosarcoma metastasizing to distant sites such as the breast highlight the aggressive behavior and potential for atypical dissemination of this tumor. Approximately 20% of rhabdomyosarcoma patients present with metastases at diagnosis, most commonly to the lungs, bone marrow, and lymph nodes [2].

Case presentation

A 20-year-old previously healthy female presented to our clinic with complaints of persistent left-hand swelling and discomfort. An initial assessment revealed a palpable mass in the left hand associated with localized pain. Regrettably, due to the urgency of the symptoms and the assumption of a possible benign etiology, surgical

*Correspondence:
Nevien Ragae Fares
Nova.fares.33@gmail.com; Besa33@hotmail.com
[1] Radiodiagnosis Department, Minia Oncology Center, Minya, Egypt

excision was performed without prior imaging evaluation. Postoperative histopathological analysis unexpectedly unveiled findings of a malignant spindle cell tumor. Approximately two months following the excision, the patient returned with alarming symptoms of rapidly growing bilateral breast masses associated with tenderness and skin changes. Imaging studies were initiated by ultrasound examination that revealed bilateral breast masses with heterogeneous characteristics. Notably, the retro-areolar region of the left breast exhibited a large, irregular soft tissue lesion, while smaller masses were observed in the contralateral breast. Moreover, bilateral axillary lymphadenopathy was evident on imaging, suggestive of potential metastatic involvement (Fig. 1).

Further characterization through magnetic resonance imaging (MRI) confirmed the presence of malignant criteria within the bilateral breast masses. The left retro-areolar mass exhibited diffuse thickening of the overlying skin. Additionally, enlarged ipsilateral left axillary lymph nodes displayed total replacement by soft tissue, mirroring that in the left breast (Fig. 2).

To establish a definitive diagnosis, ultrasound-guided true-cut needle biopsies were performed of both breast masses. Histopathological examination, along with immunophenotyping, conclusively identified metastatic malignant spindle cell tumors consistent with rhabdomyosarcoma. This unexpected diagnosis underscored the need for comprehensive evaluation and heightened suspicion of metastatic disease in unusual presentations. Subsequent metastatic work-up, including contrast-enhanced CT scans, unveiled an extensive spread of the disease. Metastases were observed in various visceral sites, notably with findings of myocardial involvement, in addition to pulmonary nodules, nodal metastasis in mediastinal, hilar, and para-aortic regions, as well as hepatic metastatic deposits (Fig. 3).

Discussion

The occurrence of breast metastasis from rhabdomyosarcoma is an infrequent presentation, representing only a small fraction of metastatic cases. The literature primarily documents metastases to the lungs, bone marrow, and

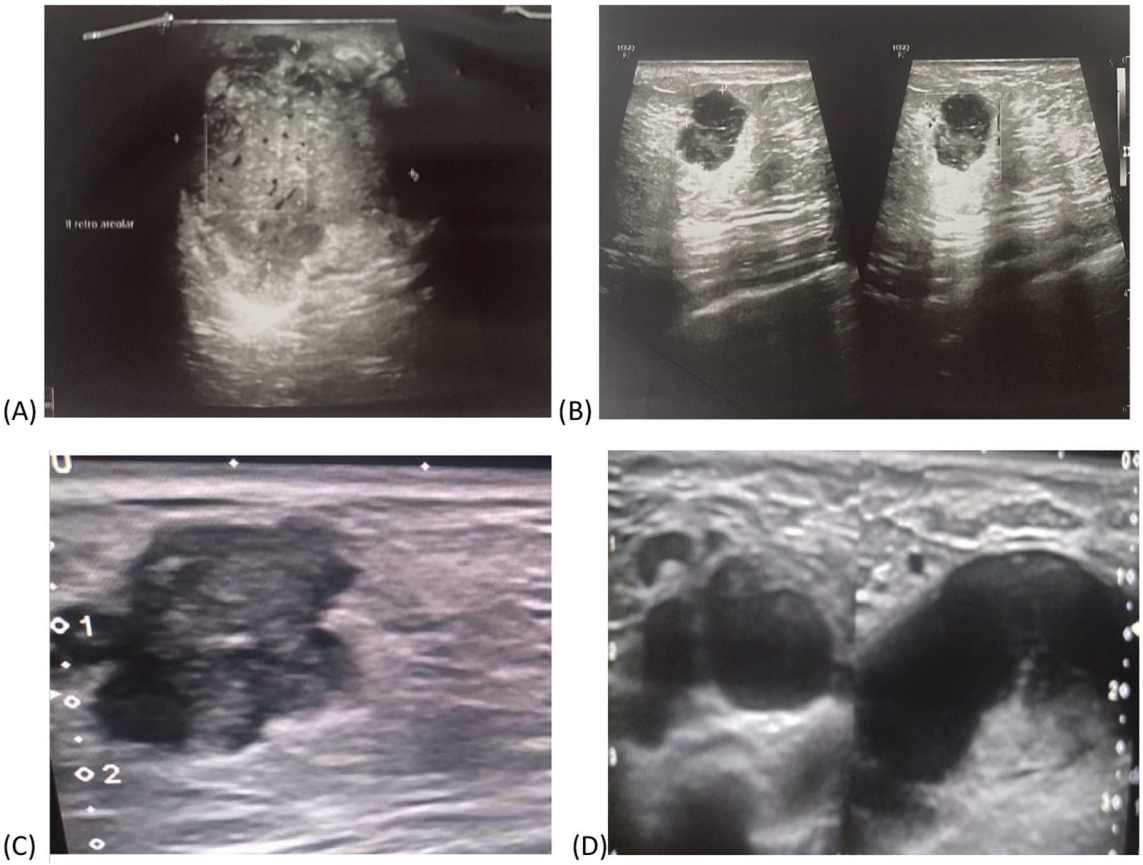

Fig. 1 Bilateral diagnostic ultrasound that shows a large heterogeneous soft tissue mass lesion seen at the retro-areolar region of the left breast (**A**), another smaller one seen at the right breast (**B**, **C**). All of them are anti-parallel orientation and do not respect related tissue plans. **D** Pathological left axillary LNs with a near total replacement of normal nodal tissue

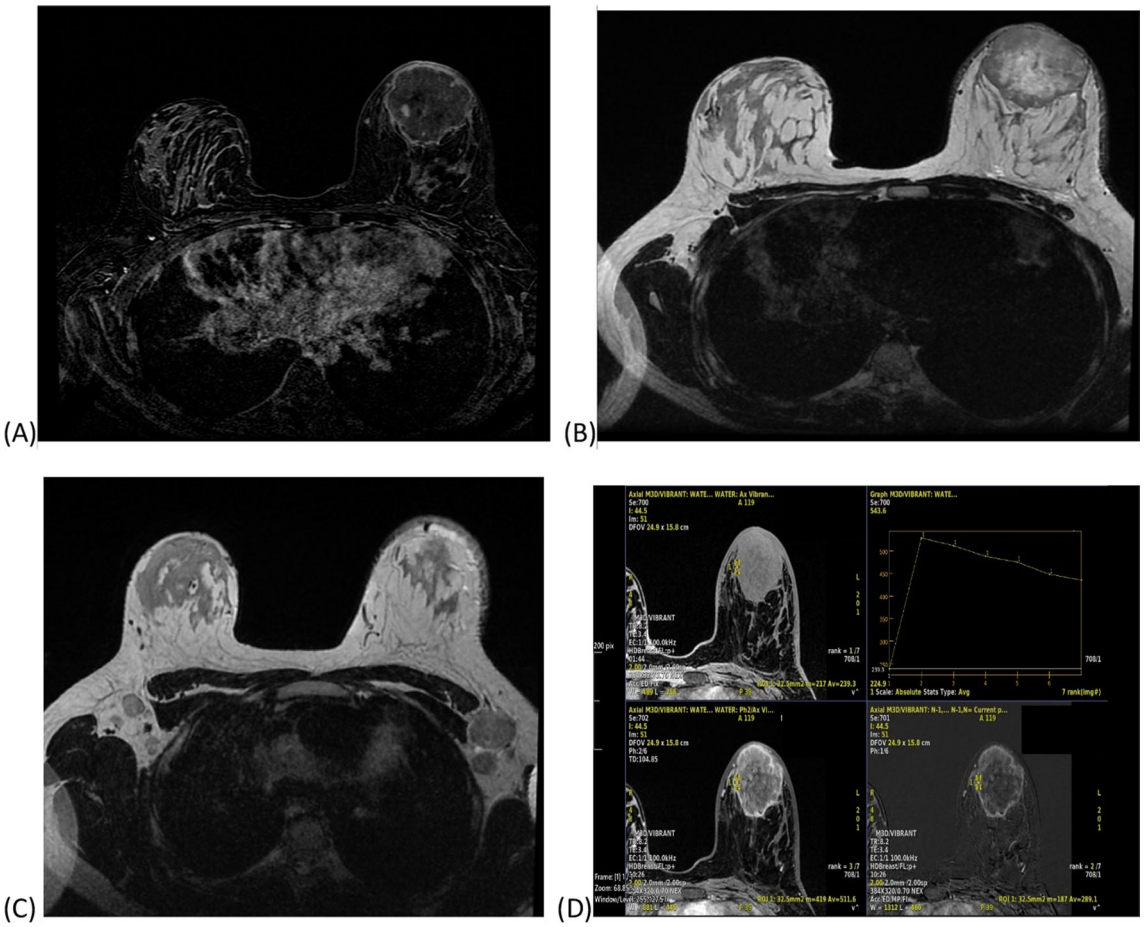

Fig. 2 Breast MRI axial plan post-contrast T1WI STIR **A** post-contrast T1WI **B**, **C** show large heterogeneously enhanced left retro-areolar mass lesion with diffuse thickening of the overlying skin, also enlarged bilateral axillary lymph nodes with the left-sided ones are seen replaced by soft tissue signal resampling that of left breast mass. Dynamic curve (**D**) on ROI on left breast mass shows a washout pattern curve

lymph nodes in rhabdomyosarcoma patients at diagnosis [3]. An unusual dissemination pattern was observed in this case, with the initial presentation in the hand followed by subsequent metastasis to the breasts. The identification of metastatic deposits in visceral organs, nodal regions, and even myocardial tissue further complicates the disease course and treatment approach [2]. This highlights the aggressive nature of rhabdomyosarcoma. Awareness among clinicians regarding the potential for breast metastasis in patients with primary rhabdomyosarcoma in other anatomical locations is crucial for prompt intervention and tailored management plans [2].

Conclusions

Metastasis of rhabdomyosarcoma to the breast is rare and occurs in young women as in our case with mainly primary site in limbs. It is important to be clinically aware of the risk of breast metastasis in female patients with primary extra-mammary rhabdomyosarcoma.

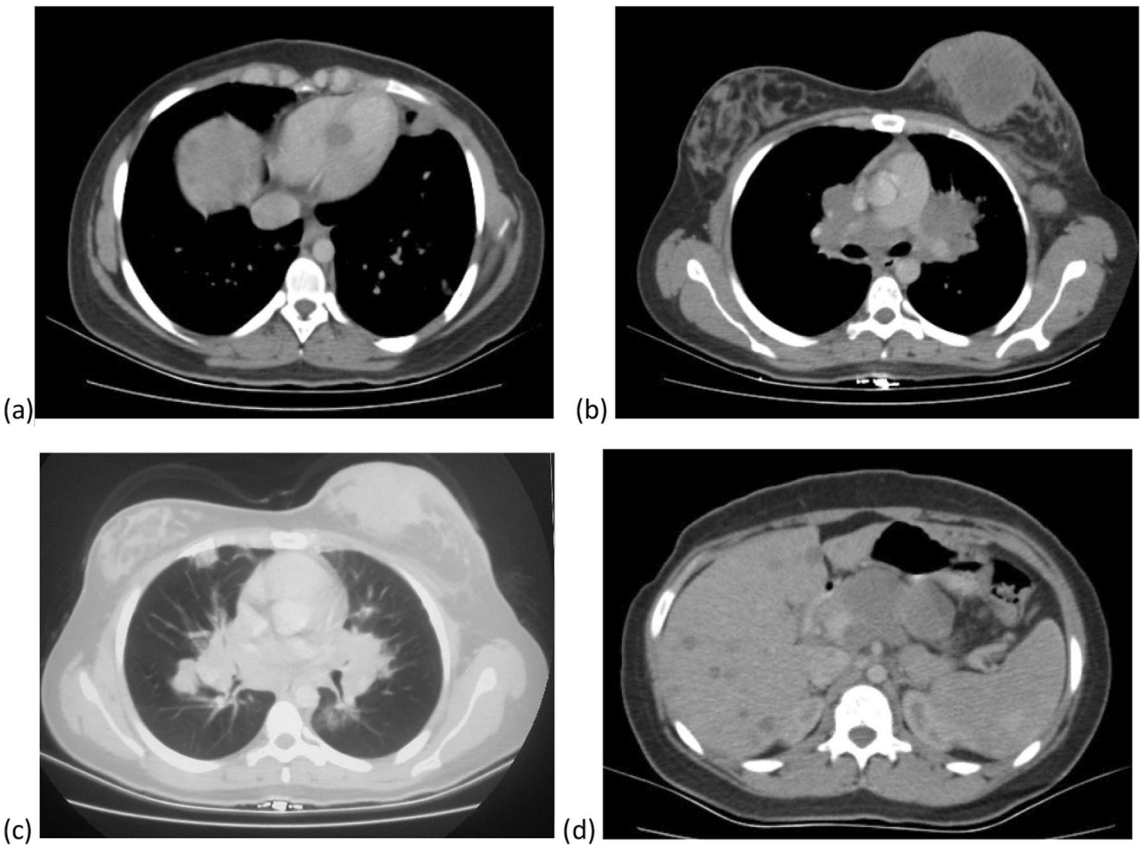

Fig. 3 Contrast-enhanced CT chest axial cuts on a mediastinal window that shows a well-defined hypodense focal mass lesion seen at the region of the inter-ventricular septum (**a**) and enlarged mediastinal, hilar, and left axillary lymph nodes as well as a large left breast mass (**b**). An axial cut of pulmonary widow shows few pulmonary nodules (**c**). An axial cut on the upper abdomen shows multiple hepatic focal lesions and enlarged amalgamated gastro-hepatic and porta-hepatis lymph nodes (**d**)

Abbreviations

CT Computed tomography
MRI Magnetic resonance imaging

Acknowledgements
We acknowledge the invaluable contribution of Dr. Mariana F. Gayed and Dr. Manal Abou Samra for their expertise in the Histopathology and MRI evaluation of this case.

Author contributions
All authors have read and approved the manuscript.

Funding
No funding disclosure.

Availability of data and materials
The data sets used and/or analyzed during the current study are available from the main author upon reasonable request.

Declarations

Ethics approval and consent to participate
This study was approved by the ethics committee of Minia Oncology Center and Specialized Medical Centers.

Consent for publication
Written informed consent was obtained from the patient for the publication of his case report and accompanying images.

Competing interests
The authors declare that they have no competing interests.

Received: 18 November 2023 Accepted: 21 January 2024
Published online: 12 February 2024

References

1. Bai X, Wang X (2018) Solitary breast metastasis from rhabdomyosarcoma shown on FDG PET/CT. Clin Nucl Med 43(7):556–558. https://doi.org/10.1097/RLU.0000000000002125
2. Audino AN, Setty BA, Yeager ND (2017) Rhabdomyosarcoma of the breast in adolescent and young adult (AYA) women. J Pediatr Hematol Oncol 39(1):62–66. https://doi.org/10.1097/MPH.0000000000000710
3. Kebudi R, Koc BS, Gorgun O, Celik A, Kebudi A, Darendeliler E (2017) Breast metastases in children and adolescents with rhabdomyosarcoma: a large single-institution experience and literature review. J Pediatr Hematol Oncol 39(1):67–71. https://doi.org/10.1097/MPH.0000000000000680

Publisher's Note