Taymour *et al. Egypt J Radiol Nucl Med* (2024) 55:42
https://doi.org/10.1186/s43055-024-01209-y

Egyptian Journal of Radiology and Nuclear Medicine

RESEARCH

Open Access

Can ultrasound shear wave elastography differentiate between malignant and benign pleural effusions?

Takeya Ahmed Taymour[1], Libya Saleh Wasel Mohamed[1], Yasmine Hamdy El Hinnawy[1] and Mohammed Raafat Abd El-Mageed[1*]

Abstract

Background Malignant pleural effusion is a common and unfortunately serious condition that is related to life poor quality and mortality. The majority of malignant pleural effusion is metastatic in nature, with the most encountered primary neoplasm in men is the lung cancer while in women is the breast cancer. Ultrasound elastography, with its ability of evaluating tissue stiffness, has been used to differentiate malignant from benign diseases. Shear wave elastography (SWE) has been explored in several organs, like the liver, breast, thyroid, lymph nodes and prostate, with the pleura can now be included among the growing list of SWE applications. Shear wave elastography may help in the differentiation of transudative and exudative types of pleural effusions.

Results In this study, a total of 36 patients were included, 50% revealed malignant pleural effusions (10/18 mesothelioma) and (8/18 metastatic), while the 50% revealed benign pleural effusions (9/18 transudates) and (9/18 exudates). By using sensitivity analysis test of the SWE values with V1 represents the minimum value, V2 the maximum value to calculate the cutoff values that will be used in our final diagnosis in order to differentiate benign and malignant cases. V1 shear wave elastography can significantly predict the malignant pleural effusion with *p* value 0.001 using a cutoff 48 kPa with calculated sensitivity, specificity, positive predictive value (PPV) and negative predictive value (NPV) were as follows 94.4%, 88.9%, 89.5% & 94.4% respectively with diagnostic accuracy of 92%. SWE maximum value (V2) can significantly predict the malignant pleural effusion with p value 0.001 using a cutoff 54.2 kPa, with calculated sensitivity, specificity, PPV and NPV were as follows 94.4%, 94.4%, 94.4% and 94.4% respectively with diagnostic accuracy 94.4%. So, through comparing both cutoff values, we concluded that the cutoff value 2 is better with greater specificity, PPV and NPV in relation to the final diagnosis.

Conclusions Combination of both conventional transthoracic ultrasound and SWE quantitative and qualitative abilities in assessment of both pleural and parenchymal lesions can result in high diagnostic accuracy. Shear wave elastography alone is a sensitive, specific, useful, cost-effective, widely available and noninvasive tool for assessment of tissue stiffness and in matters of high sensitivity. 54.2 kPa can be used as the cutoff value to distinguish MPE from benign pleural disease.

Keywords Pleural effusion, Ultrasound, Shear wave elastography

*Correspondence:
Mohammed Raafat Abd El-Mageed
mohammed.raafat@kasralainy.edu.eg
[1] Faculty of Medicine, Cairo University, Cairo, Egypt

Background

Malignant pleural effusion (MPE) is a common and unfortunately serious condition that is related with life poor quality and mortality. The majority of malignant pleural effusion is metastatic in nature, with the most encountered primary neoplasm in men is the lung cancer

while in women is the breast cancer. The daily practice of thoracic ultrasound (TUS) has enhanced the diagnosis of MPE and assisted in the improvement of pleural procedures [1].

The different imaging modalities established their role in the diagnostic workup of patients with suspected MPE. Nowadays, TUS is routinely used by the physicians mainly during the pleural interventions to minimize complications. TUS can provide important information during the investigation workup of patients with pleural effusion. Pleural thickening and nodularity detected during TUS are highly specific for malignancy and therefore may help to shorten the investigation time specially in patients with these high-risk features [2].

Ultrasound elastography is a noninvasive, safe, cost-effective and reliable technique to assess the mechanical properties of soft tissue and provide imaging biomarkers for pathological processes. The large difference in acoustic impedance between air and lung tissue results in the reflection of the ultrasound wave at the lung surface and, consequently, the loss of most ultrasound energy. In recent years, there has been an increasing interest in ultrasound elastography applications in evaluating lung diseases [3].

TUS is often the initial tool used to help diagnose MPE. Ultrasound elastography, with its ability of evaluating tissue stiffness, has been used to differentiate malignant from benign diseases [4].

Shear wave elastography (SWE) has been explored in several organs, like the liver, breast, thyroid, lymph nodes and prostate, with the pleura can now be included among the growing list of SWE applications [5].

SWE may help in the differentiation of transudative and exudative types of the pleural effusions [6].

The purpose of this research is to investigate the feasibility of transthoracic shear wave ultrasound elastography values in the differentiation of pleural effusions by the accompanied pleural or pulmonary lesions.

Methods

During this prospective study, a total of 36 patients were included from December 2021 to September 2022. They had a mean age of 53.5 years ranging from 21 to 88 years old with 24 of them were males (66.3%), while the other 12 were females (33.7%).

The patients with known pleural effusion were referred from chest department and outpatient clinic to the radiology department of our institution from September 2021 to June 2022, and lung US with shear wave elastography had been done for them.

Inclusion criteria

- Computed tomography (CT) evidence of pleural effusion (s).
- No established diagnosis (malignant or otherwise) of the cause of pleural effusion.

Exclusion criteria

- Patient too ill to warrant further investigation in normal clinical practice.
- Patients who refuse to undergo further investigations to assess the nature of their pulmonary lesions and the associated pleural effusions.
- Severely dyspneic patients that could not withhold their breath or cooperate during ultrasound examination.

All cases were subjected to the following:

- Thorough clinical examination, history taking, general and chest examination and routine laboratory tests.
- Imaging studies:
  - CT chest or chest X-rays according to assumed diagnosis.
  - Ultrasound: Transthoracic ultrasound with SWE were done to all patients with pleural effusion.
- Aspiration cytology of pleural fluid had done first for some patients.
- Tissue biopsy or aspiration has been performed for suspicious cases for whom of the following criteria exist:
  - Pleural or pulmonary lesions by CT and transthoracic US.
  - Cases with history of previous malignant diseases even with negative imaging findings.
- Other patients just follow-up after medical treatment.

Protocol of ultrasound examination

- The studies were performed using Toshiba Aplio 500 provided with shear wave elastography software with both a high-resolution straight exhibit transducer of 7–14 MHz is used and convex transducer 3–5 MHz is used for imaging in more obese patients.

Chest ultrasonography technique of examination:

- The patients were examined in the supine and sitting positions, arms raised and hands placed at the back of the head in order to extend the intercostal spaces and rotate the scapula outward.
- Examination was performed systematically through the intercostal spaces in six vertical lines which are mid clavicular, anterior axillary, mid axillary, posterior axillary, mid scapular and para-vertebral. The examination was started from the midclavicular line by recognizing the pleura, which appears as fine echogenic line between two anechoic ribs.
- Examination performed while the patient taking a deep breath and holding it in order to widen the intercostal spaces.
- B-mode assessment of the pleural effusion and the parietal pleura had been done first to identify its sonographic aspect. Associated pleural thickening and subpleural/pulmonary masses accompanied by fast scanning of the abdominal solid organs for any mass lesions within.

Ultrasound-SWE Technique:

- SWE has been applied with avoiding compression during scanning and SWE values had been taken in different quadrants and areas to ensure fulfilling most of the pleural areas to ensure symmetry of findings with ROI circles diameter between 3 and 10 mm.
- Multiple SWE values in kilo pascal (kPa) with color coded maps (elastogram) were taken and two values, the minimum and maximum elasticity values are used for the final diagnosis.
- Twin ultrasound elastography views were used in which the left image represents the elastogram and the right image represents the B-mode ultrasound which help to visualize the parietal pleura lines and to apply ROI measurements in kPa.

Data analysis:

- Transthoracic ultrasound parameters that had been used in the final diagnoses and considered positive for malignant etiologies are presence of parietal pleura thickening > 1 cm, presence of subpleural and pulmonary masses. Assessment of pleural fluid volume and aspect also done.
- SWE was evaluated using both quantitative measurements (elasticity values) and qualitative assessment using a color coding elastogram. Solid (stiff) tissues generate primarily red color maps, whereas soft (less stiff) tissues generate green/yellow-to-light blue color maps.

Methods of final diagnosis:

- Correlated with conventional TUS and US SWE.
- The histopathological results will be used as the diagnostic reference for diagnosing nature of pleural effusion in most of the cases.
- Some patients in our study diagnosed based upon clinical data and follow-up response to medical treatment and proved by radiological CT chest for absence of any suspicious pleural/pulmonary lesions.

Statistical analysis

Statistical analysis was conducted using SPSS 25th edition, numeric variables as age were presented in mean ± SD. Categorical data were presented in frequency and percentages, and paired comparison of diagnostic modalities was conducted using paired *t* test. Sensitivity, specificity, positive predictive value, negative predictive value and diagnostic accuracy were calculated using ROC curve. Any p value < 0.05 was considered significant.

Results

A total of 36 patients were included in the study, they had a mean age 53.5 years ranging from 21 to 88 years old. Twenty-four of them were males (66.3%), while twelve were females (33.7%).

The percentage of benign to malignant effusions is 50:50 as shown in Table 1 with the characteristics of the pleural effusions described in Table 2.

Table 1 Underlying causes of pleural effusion

Benign		Malignant
Exudates	**Transudates**	**Exudates**
Post pneumonic/inflammatory	Renal	Mesothelioma
7 (38.8%)	3 (8.3%)	10 (55.5%)
Tuberculosis	Cardiac	Metastatic
2 (11.1%)	3 (8.3%)	8 (44.4%)
	Hepatic 3 (8.3)	

Table 2 Characteristics of the pleural effusions

	Frequency	Percentage
Side of affection		
Left sided	5	13.9%
Right sided	29	80.6%
Bilateral	2	5.6%
Pleural thickening		
No	27	75%
Yes	9	25%
Aspect		
Non septated	29	80.6%
Septated	7	19.4%
Volume		
Mild	6	16.7%
Moderate	13	36.1%
Massive	17	47.2%

Diagnostic indices of transthoracic ultrasound

Criteria for malignancy are presence of pleural thickening > 1 cm with or without subpleural nodularity and masses.

Paired comparison of US findings and final diagnosis showed that there was a statistically significant difference between US findings and diagnosis with P value 0.012. US showed 56% sensitivity, 88.9% specificity, 83.3% PPV, 66.7% NPV and overall accuracy 62% in detecting malignant pleural effusions. These findings indicate that US can be used as a screening rather than diagnostic tool for malignant pleural effusion.

Regarding the pleural effusion characteristics, the number of the malignant cases was higher in case of septated pleural effusions (6 out of 7 were malignant) and massive pleural effusions (11 out of 17 were malignant). Therefore, both characteristics can be considered as important predictors of malignant effusions and urge meticulous further investigations.

Ultrasound shear wave elastography

By using sensitivity analysis test of the three SWE values with V1 represents the minimum value, V2 the maximum value to calculate the cutoff values that well be used in our final diagnosis in order to differentiate benign and malignant cases.

Shear wave elastography minimum (values1) can significantly predict the malignant pleural effusion with p value 0.001 using a cutoff 48 kPa with calculated sensitivity, specificity, positive predictive value and negative predictive value were as follows 94.4%, 88.9%, 89.5% & 94.4% respectively with diagnostic accuracy of 92% and 0.934 AUC.

SWE maximum value (values 2) can significantly predict the malignant pleural effusion with p value 0.001 using a cutoff 54.2 kPa, with calculated sensitivity, specificity, positive predictive value and negative predictive value were as follows 94.4%, 94.4%, 94.4% and 94.4% respectively with diagnostic accuracy 94.4% and 0.952 AUC.

So, with comparing both cutoff values, we concluded that the cutoff value 2 is better with greater specificity, PPV and NPV in relation to the final diagnosis. Cases with SWE values greater than 54.2 kPa are classified as malignant (Figs. 1, 2), while those with SWE values lower than 54.2 kPa are classified as benign (Fig. 3).

Our results showed a sensitivity of 94.4% and a specificity of 88.9% for detecting MPE with the SWE 48 kPa a total of 33 (92%) out of 36 patients were correctly diagnosed. Two patients were misdiagnosed with MPE (tuberculous) and one patient with metastatic carcinoma was misdiagnosed as benign PE.

While SWE value of 54.2 kPa showed higher value indices, one patient with was misdiagnosed with MPE (tuberculous) and one patient with pulmonary adenocarcinoma that metastasized to the pleura was misdiagnosed as benign PE with a total 34 (94%) out of 36 were correctly diagnosed.

Discussion

Pleural effusion can occur because of a high hydrostatic pressure gradient (transudate) or enhanced permeability in pleural vascular systems (exudate). Pleural effusion found in a patient necessitates careful differential diagnosis because therapy is dependent on fluid density [7].

B-mode ultrasonography exposes organ morphology and volume values, whereas USE gives quantitative and qualitative information regarding tissue elasticity [4].

Ultrasound elastography is a novel technique that assesses tissue stiffness. Therefore, UE may provide additional information on tissue mechanical properties

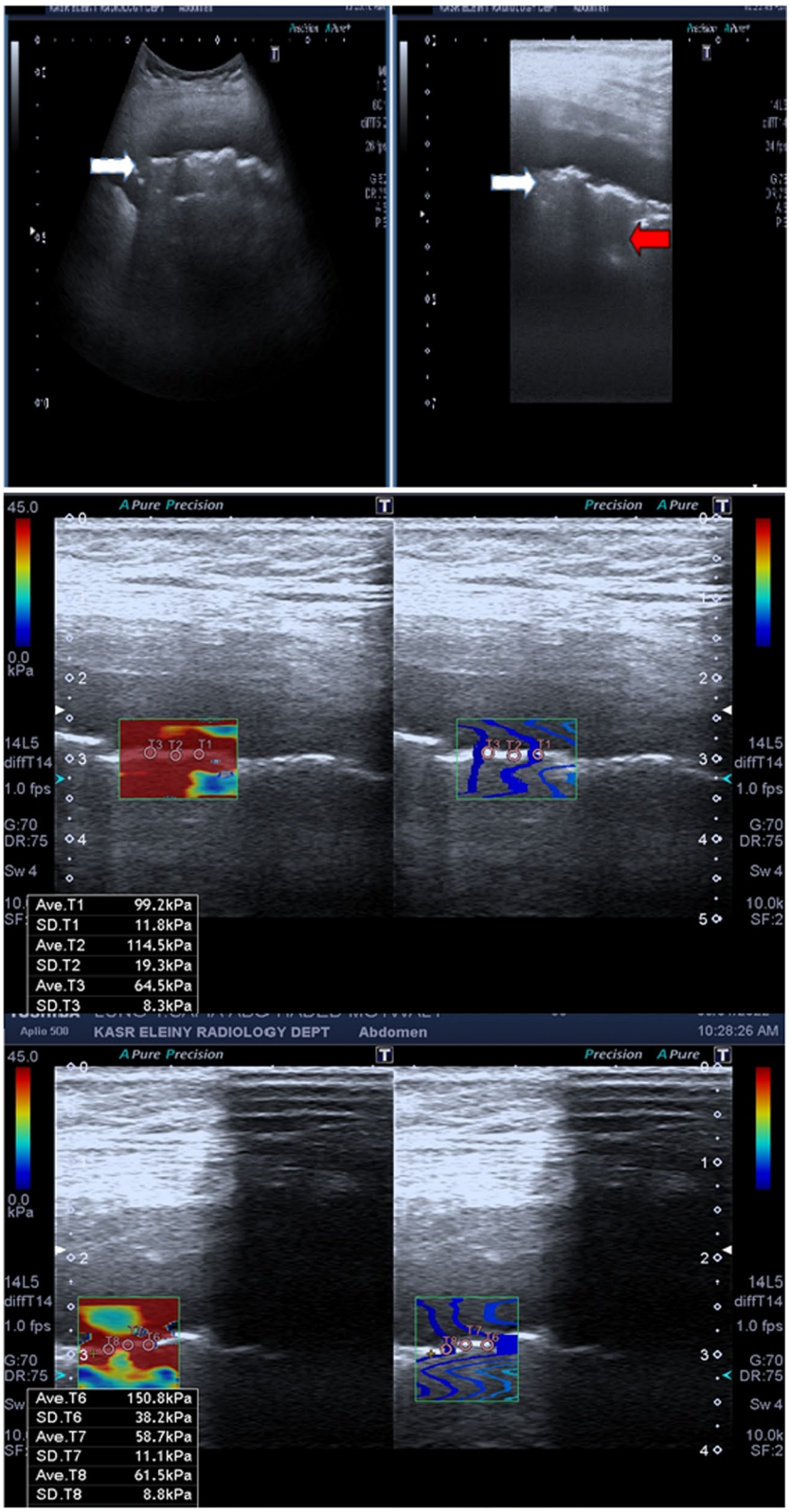

Fig. 1 (See legend on next page.)

(See figure on previous page.)

Fig. 1 An 88-year-old female patient presented with dyspnea, chest pain and weight loss with inserted chest tube revealing hemorrhagic contents. The first image from above is transthoracic B-mode ultrasound showing pleural thickening and irregularity (white arrow) with subpleural nodules (red arrow) associated with mild anechoic right sided pleural effusion. The next two images: Right images B-mode ultrasound, left image measures elasticity values in kPa. with color coding maps of predominantly red (high stiffness, solid tissues). SWE values all above 54.2 kPa with maximum value equal 150 kPa. compatible with final diagnosis of malignancy. By histopathology of transthoracic pleural biopsy revealed malignant mesothelioma

compared to ultrasonography, which analyzes tissue acoustic properties. As the tissue stiffness of malignant lesions is usually higher than that of benign lesions, elastography could be used to differentiate malignancy from normal tissue, thus informing the decision of which nodules to sample during ultrasound-guided transthoracic needle biopsy [8].

Thus, we conducted a cross-sectional analytical study aiming to investigate the feasibility of transthoracic shear wave elastography values in the differentiation of malignant pleural effusions by assessment of the parietal pleura elastographic findings.

We included a total of 36 patients in the final analysis, they had a mean age 53.5 range from 21 to 88 years old, 50% of the cases revealed malignant pleural effusions while the 50% revealed benign pleural effusions.

The current study showed that shear wave elastography could significantly predict the malignant pleural effusion with p value 0.001 using a SWE maximum cutoff value of ≥ 54.2 kPa giving 94.4% sensitivity, 94.4% specificity, 94.4% positive predictive value and 94.4% negative predictive with diagnostic accuracy 94.4%.

These findings are consistent yet with rather higher values compared to the results of Jiang et al. [4], who concluded that the diagnostic performance based on SWE with maximum cutoff value of ≥ 56.9 kPa showed that 84.21% of patients were diagnosed correctly with malignant pleural effusion with 84.2% sensitivity, 82% specificity, 87.27% NPV and 80.7% PPV.

The current study also showed that shear wave elastography could significantly predict the malignant pleural effusion with p value 0.001 using a SWE minimum cutoff of ≥ 48 kPa, 94.4% sensitivity, 88.9% specificity, 89.5% positive predictive value, 94.4% negative predictive value diagnostic accuracy 92%.

These findings were consistent with the study conducted by Jiang et al. [4], who stated that the diagnostic performance using SWE cutoff point ≥ 47.25 kPa showed that 88.60% of patients were diagnosed correctly with malignant pleural effusion with 90.57% sensitivity, 86.9% specificity, 85.7 PPV and 91.2% NPV.

With 91% sensitivity and 76.7% specificity, Ozgokce et al. [6] stated a conclusion that exudative pleural effusion SWE values were higher than transudative pleural effusion SWE values and statistically significant.

These diagnostic indices were lower than reported in our study, this can be justified by their larger samples and the different population included with different prevalence of etiologies.

According to the same previous mentioned studies whom stated that most false-positive results in both conventional TUS and US elastography were due to tuberculosis infection and empyema, our current study also revealed false-positive finding for tuberculosis patients, and conventional TUS revealed irregular mild pleural thickening. These findings are explained by the severe inflammatory reactions caused by tuberculous infection on the pleural lining, as well as the subsequent residual pleural thickening and fibrosis that can occur later in treatment. These changes result in high SWE values and a red elastogram which is mistaken for MPE.

Jiang et al. [4] study also revealed that false-negative results were for some non-small cell lung carcinoma (adenocarcinoma) which showed also mild amount of pleural effusion without separation. The parietal pleura measured 0.4 cm in thickness with its elasticity value below the cutoff value measures about 41.4 kPa.

Similarly in our study, the false negative results were to also attributed to lung adenocarcinoma showing pleural metastasis with elasticity value below cut-off value measures about 29 kPa.

In the current study, paired comparison of US findings and final diagnosis showed that there was a statistically significant difference between US findings and final diagnosis with p value 0.012. US showed sensitivity 56%, specificity 88.9%, PPV 83.3%, NPV 66.7% and overall accuracy 62% in detecting malignant pleural effusion as we depend mostly on the parietal pleural thickness and associated subpleural nodularity/masses.

These findings were consistent with a study conducted by Jiang et al. [4], who reported that the sensitivity of thoracic US was 60%, the specificity was 93.33% in detection of malignant pleural effusion (Jiang et al., 2019).

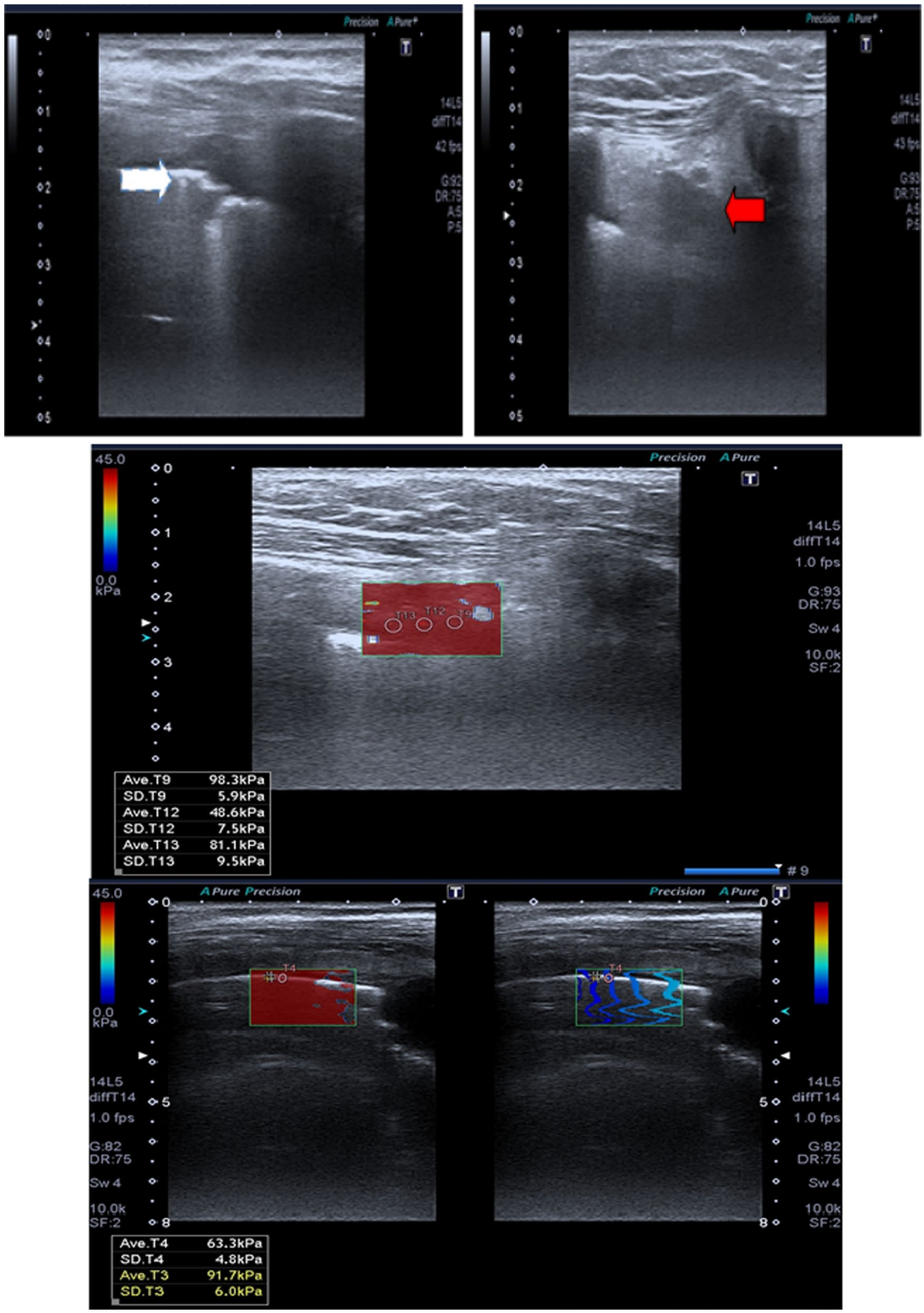

Fig. 2 (See legend on next page.)

(See figure on previous page.)

Fig. 2 53 years old male patient presented with hemoptysis, cough and dyspnea with inserted chest tube draining hemorrhagic fluid. The first image from above is for transthoracic B-mode ultrasound showing pleural thickening (white arrow) and subpleural pulmonary solid mass lesion (red arrow) with remnant of anechoic mild pleural effusion. The next two images revealing elasticity values in kPa. with color coding maps of predominantly red (high stiffness, solid tissues). SWE values all above 54.2 kPa with maximum value equal 98 kPa. compatible with final diagnosis of malignancy. By histopathology of transthoracic tru-cut pleural biopsy revealed epithelial type neoplasm infiltrating the pleura of metastatic suprarenal adenocarcinoma

In study by Qureshi et al. [9] conducted on 52 Patients stated that TUS is useful in differentiating malignant from benign pleural disease in patients presenting with suspected MPE and may become an important adjunct in the diagnostic pathway, whom also correlate the contrast enhanced CT findings with those of TUS and established that TUS parietal pleural thickening and nodularity have using a TUS threshold value of pleural thickening > 1 cm as suggestive of malignancy, TUS has an overall sensitivity of 79%, specificity 100%, positive predictive value (PPV) 100% and negative predictive value (NPV) 73% for differentiating malignant from benign pleural disease.

Jimenez et al. [10] who conducted study on 1084 patients with pleural effusions concluded that malignancy is the most common cause of massive exudative effusions (53.7%) and transudative effusions as cirrhotic (9.9%) and idiopathic 14%. Parapneumonic effusions account for (10.7%) and also TB (7.4%). They considered cirrhosis of liver is the most common cause of massive transudative effusion in matter of frequency.

In current study, finding were consistent with previous studies with 11/18 of malignant (64.7%) and 6/18 (35.3%) of benign effusions were massive in volume. In brief fluid volume is not a diagnostic parameter by its own, but it warrants meticulous further cytological and histopathological correlation.

According to Shkolnik et al. [11] evaluation of 300 patients with pleural effusion, thoracic ultrasonography is inadequate to diagnose a transudative pleural effusion reliably. Although the TUS findings of a complex septated effusion may suggest an exudative pleural effusion with high positive predictive value of 90%. However, none of the four TUS characteristics were highly specific of a pleural diagnosis.

In current study, we concluded the sonographic assessment of fluid volume and sonographic appearance support the fact that US can be used as a screening rather than diagnostic tool for malignant pleural effusion.

In the current study, we faced some limitations. First, the relatively small sample size of this study which may have affected the determination of the cutoff elasticity values for shear wave elastography. Not all metastatic lesions were much included in our study due to bad general conditions of the available cases, which highly degrading the exam quality and more over the SWE values, so they have been excluded from our study. Finally, the interpretation and generalization of our results should consider potential pitfalls and technical limitations. Despite of preforming SWE is less operator dependent than strain elastography, it still should be performed by experienced personnel.

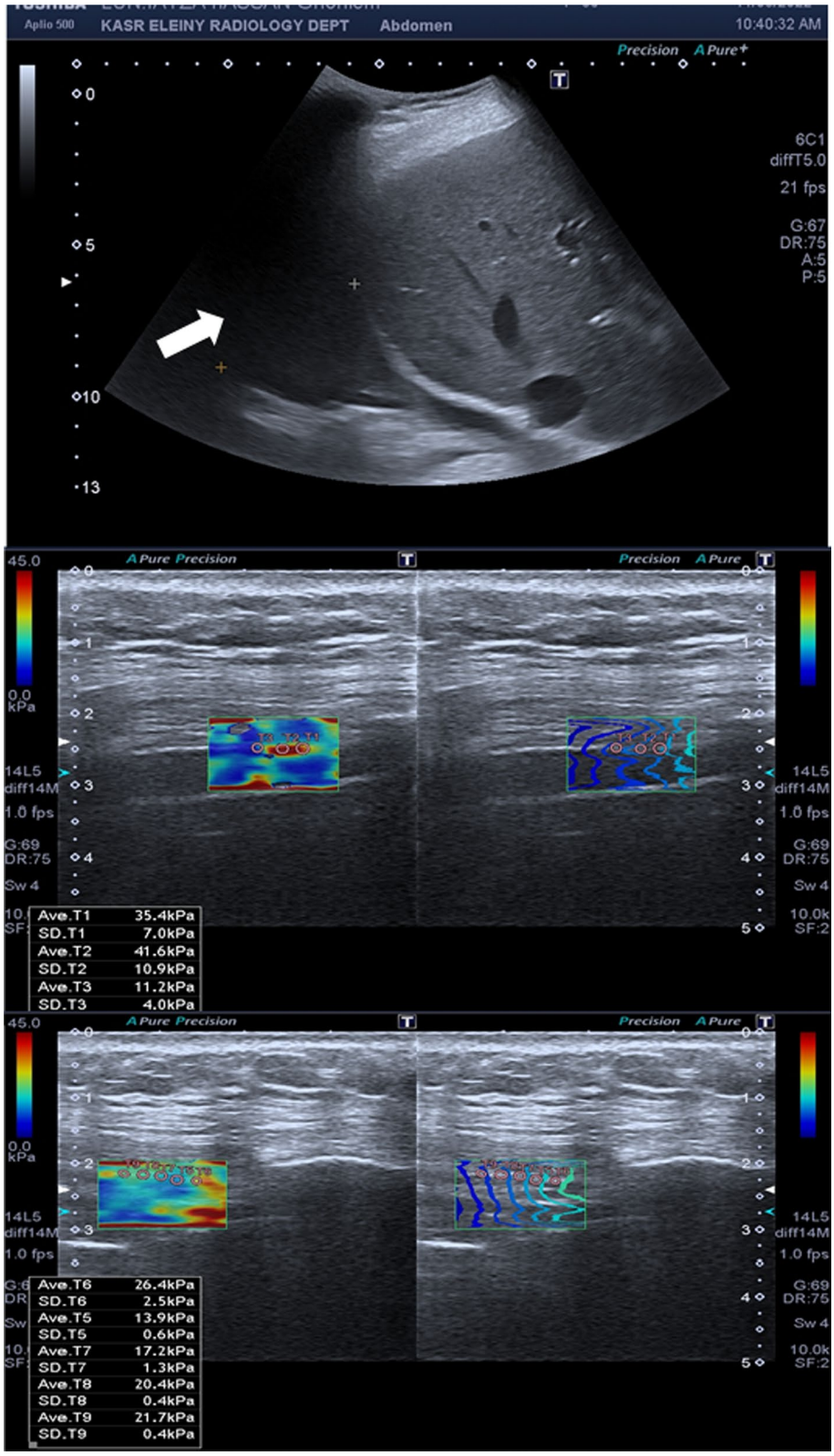

Fig. 3 (See legend on next page.)

(See figure on previous page.)

Fig. 3 59 years female patient presented with dyspnea, cough and fever. The first image from above is transthoracic B-mode ultrasound shows mild-to-moderate anechoic right-sided pleural effusion (white arrow). The next two images revealing elasticity values in KPa with color coding maps of predominantly yellow/green (less stiffness, soft tissues). Although negative transthoracic ultrasound for pleural thickening, subpleural masses or pulmonary lesions, biopsy had been taken from the patient as the patient known to had right breast cancer in order to exclude metastatic etiology. By histopathology pleural biopsy revealed inflammatory reactions. SWE values all below 54.2 kPa with maximum value equal 41.6 kPa compatible with final diagnosis of benign nature

Conclusions

In conclusion, combination of both conventional transthoracic ultrasound and SWE quantitative and qualitative abilities in assessment of both pleural and parenchymal lesions can result in high diagnostic accuracy. Shear wave elastography alone is a sensitive, specific, useful, cost effective, widely available and noninvasive tool for assessment of tissue stiffness and in matters of high sensitivity result can be used to distinguish malignant pleural effusion from benign pleural disease.

Abbreviations

MPE	Malignant pleural effusion
SWE	Shear wave elastography
PPV	Positive predictive value
NPV	Negative predictive value
TUS	Transthoracic ultrasound
CT	Computed tomography
kPa	Kilo pascal

Acknowledgements

The authors would like to thank all the personnel contributed to this study.

Author contributions

TA shared in study conception and design, processing CT findings and shared in writing and correcting the manuscript and revision. LS shared in study conception and design, processing CT findings and shared in writing and correcting the manuscript and revision. YH shared in study conception and design, writing and correcting the manuscript and revision. MR shared in study conception and design, acquisition of data, analysis and interpretation of data and drafting of manuscript. All authors read and approved the final manuscript.

Funding

This study had no funding from any resource.

Availability of data and materials

The datasets used and/or analyzed during the study are available upon reasonable request.

Declarations

Ethics approval and consent to participate

No individual data included in the study. This study was approved by the Research Ethics Committee of the Faculty of Medicine at Cairo University Kasr El-Aini in Egypt in December 2021; reference number MS-508–2021. All patients included in this study gave verbal informed consent to participate in this research. If the patient was unconscious at the time of the study, written informed consent for their participation was given by their legal guardian.

Consent for publication

All patients included in this study gave written informed consent to publish the data contained within this study. If the patient was unconscious when consent for publication was requested, written informed consent for the publication was given by their legal guardian.

Competing interests

The authors declare that they have no competing interests.

Received: 5 November 2023 Accepted: 26 January 2024
Published online: 23 February 2024

References

1. Psallidas I, Kalomenidis I, Porcel JM, Robinson BW, Stathopoulos GT (2016) Malignant pleural effusion: from bench to bedside. Eur Respir Rev 25(140):189–198
2. Bugalho A, Ferreira D, Dias SS, Schuhmann M, Branco JC, Gomes MJ, Eberhardt R (2014) The diagnostic value of transthoracic ultrasonographic features in predicting malignancy in undiagnosed pleural effusions: a prospective observational study. Respiration 87(4):270–278
3. Zhou B, Yang X, Zhang X, Curran WJ, Liu T (2020) Ultrasound elastography for lung disease assessment. IEEE Trans Ultrason Ferroelectr Freq Control 67(11):2249–2257
4. Jiang B, Li XL, Yin Y, Zhang Q, Zang T, Song WS, Wang XM, Kang J, Herth FJ, Hou G (2019) Ultrasound elastography: a novel tool for the differential diagnosis of pleural effusion. Eur Respir J 54(2):1802018
5. Porcel JM (2019) Ultrasound-based elastography:"hard" to implement in the pleural effusion work-up? Eur Respir J 54(2):190
6. Ozgokce M, Durmaz F, Yavuz A, Üney I, Yildiz H, Arslan H, Dundar I, Havan N, Ogul H (2019) Shear-wave elastography in the characterization of pleural effusions. Ultrasound Q 35(2):164–168
7. Jany B, Welte T (2019) Pleural effusion in adults—etiology, diagnosis, and treatment. Dtsch Arztebl Int 116(21):377
8. Quarato CM, Venuti M, Dimitri L, Lacedonia D, Simeone A, Mirijello A, De Cosmo S, Maiello E, Taurchini M, Scioscia G, Barbaro MP (2022) Transthoracic ultrasound shear wave elastography for the study of subpleural lung lesions. Ultrasonography 41(1):93
9. Qureshi NR, Rahman NM, Gleeson FV (2009) Thoracic ultrasound in the diagnosis of malignant pleural effusion. Thorax 64(2):139–143
10. Jiménez D, Díaz G, Gil D, Cicero A, Pérez-Rodríguez E, Sueiro A, Light RW (2005) Etiology and prognostic significance of massive pleural effusions. Respir Med 99(9):1183–1187
11. Shkolnik B, Judson MA, Austin A, Hu K, D'Souza M, Zumbrunn A, Huggins JT, Yucel R, Chopra A (2020) Diagnostic accuracy of thoracic ultrasonography to differentiate transudative from exudative pleural effusion. Chest 158(2):692–697

Publisher's Note