

CASE REPORT

Open Access



# A case report of left paraduodenal hernia with a spontaneous reduction on follow-up: the rare demonstration on computed tomography

Saurabh Maheshwari<sup>1\*</sup> , Ajay Khadka<sup>1</sup>, Saikat Bhattacharjee<sup>2</sup>, Uddandam Rajesh<sup>1</sup> and Vibhuti Maria<sup>3</sup>

## Abstract

**Background:** Left paraduodenal hernia (PDH) makes for around 40% of all internal hernias. It is due to the prolapse of bowel through fossa of Landzert, an anatomic variant that is found in around 2% of the population. This hernia is presumed to be spontaneously reducible in many patients with recurrent symptoms.

**Case presentation:** The present report shows the case of this condition in a 65-year-old male presenting with recurrent abdominal pain and subacute intestinal obstruction who was unwilling for surgery and was managed conservatively. A follow-up scan after 11 months revealed complete spontaneous resolution of hernia.

**Conclusions:** This represents only the second demonstration of the oft-mentioned spontaneous reduction of this condition on computed tomography. The radiologists should be aware of this uncommon entity and in the event of clinical suspicion; the imaging should be performed when the patient is symptomatic.

**Keywords:** Hernia, Internal hernia, Paraduodenal hernia, Fossa of Landzert, Abdominal pain

## Background

Internal hernias have an overall incidence of around 1% and cause around 4% of all cases of intestinal obstruction [1]. Paraduodenal hernia (PDH) is the most common type of internal hernias. Left-sided PDH, where the bowel loops herniate through fossa of Landzert, makes around 75% of all PDH [2]. PDH is presumed to be spontaneously reducible in literature, leading to the chronic and recurrent symptomatology [3]. However, there is only one previous case report demonstrating the spontaneous reduction on computed tomography (CT) [4]. This report shows the case of a 65-year-old male with left-sided PDH who was managed conservatively, and a follow-up scan revealed a complete reduction of the hernia.

## Case presentation

A 65-year-old male presented to the emergency department of a tertiary care center in Southern India with complaints of abdominal pain for 3 days duration. He had associated abdominal distension and two episodes of vomiting with no passage of stools over this period. Intermittent passage of flatus was present. He had no history of fever or weight loss. There was no history of previous surgery, trauma, or chronic abdominal pathology. Family and travel history were not contributory.

General examination including vital parameters was normal. Abdominal examination revealed abdominal distension and diffuse abdominal tenderness. There was no guarding or rigidity. Bowel sounds were muffled. A radiograph abdomen showed a few air-fluid levels. However, bowel loops were not dilated. There was no evidence of pneumoperitoneum. A bedside ultrasound of the abdomen and pelvis was not contributory. Routine

\* Correspondence: [saurabhmshwr@yahoo.co.in](mailto:saurabhmshwr@yahoo.co.in)

<sup>1</sup>Department of Radiodiagnosis and Imaging, Armed Forces Medical College, Pune, India

Full list of author information is available at the end of the article

hematological and biochemical investigations were normal.

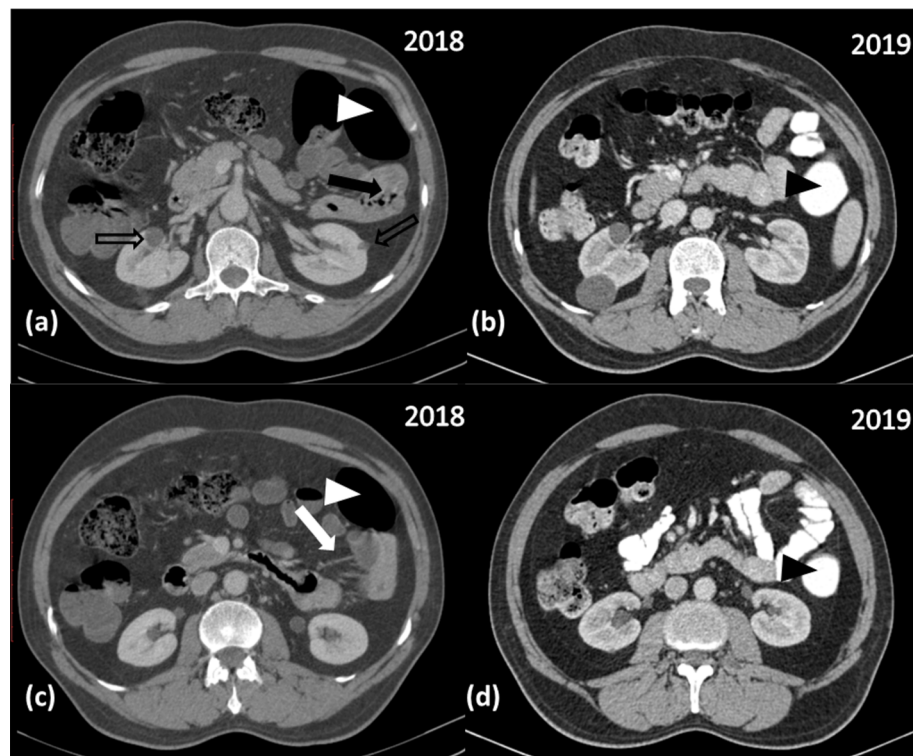
A contrast-enhanced computed tomography (CECT) scan of the abdomen and pelvis was performed for further evaluation of suspected sub-acute intestinal obstruction. The CECT revealed anteromedial displacement of the descending colon in its entire length which was abutting the anterior parietal peritoneum. Multiple proximal jejunal bowel loops were seen to herniate posterolaterally and lie in the anterior pararenal space, to the left of the ligament of Treitz (Fig. 1a). There was crowding and stretching of the mesenteric vessels supplying these loops, but no torsion was seen (Fig. 1c). These vessels were seen to drain into the superior mesenteric vein. The herniated bowel loops did not show any evidence of obstruction or ischemia. There was no other abnormality in the abdomen and pelvis except multiple simple renal cysts. Based on these findings, the patient was diagnosed as a case of left-sided paraduodenal hernia. He was advised for surgery. However, he refused it and was managed conservatively. The patient was discharged after 5 days as his symptoms resolved.

The patient had three episodes of recurrence of symptoms before a follow-up CECT scan done at 11 months. This scan revealed complete resolution of previously seen herniation of bowel loops. The descending colon was also seen to occupy its normal position in the anterior pararenal space lying flush with anterior renal fascia (Fig. 1b and d).

The patient was managed conservatively. He was advised of surgical exploration and repair. However, he did not provide consent for the same. He is on regular follow-up with intermittent recurrence of symptoms which are managed conservatively.

#### Ethics approval and consent to participate

The present study was approved by the ethical board of the hospital in which the study was performed. The patient reported in this article had signed a written informed consent form. This case report was a reporting of a case in a medical educational center, in which all patients are informed that they may be subjects of scientific experiments and are informed of the ethical codes of conduct. This study was in compliance to the latest version of the Helsinki Declaration.



**Fig. 1** Contrast-enhanced computed tomography (CECT) axial images of the abdomen in soft tissue window 11 months apart. Images at presentation (**a** and **c**) show a cluster of small bowel loops seen lying in the left anterior pararenal space (solid black arrow in **a**) with anterior displacement of the descending colon (solid white arrowhead in **a** and **c**). Also seen are multiple simple renal cysts in both kidneys (void black arrows in **a**). Multiple stretched mesenteric vessels are noted in the mesentery of these bowel loops (solid white arrow in **c**). Images after 11 months (**b** and **d**) show complete resolution of these abnormalities. The descending colon is seen in its expected location in the left anterior pararenal space (solid black arrowhead in **b** and **d**)

## Discussion

Internal hernias are well-known, though uncommon, cause of intestinal obstruction. Their types, clinical features, imaging features, and complications have been well documented in the literature [2, 5].

PDH is the most common type of internal hernias constituting around 53% of them [2]. It is of two types: left-sided PDH (75%) and right-sided PDH (25%). Left-sided PDH is due to failure of fusion of the part of the descending mesocolon to the posterior parietal peritoneum [4]. This leads to the formation of the fossa of Landzert, which is also known as the left paraduodenal fossa. This fossa is located at the duodenojejunal (DJ) junction, and bowel loops can herniate through it.

Its clinical features are usually non-specific ranging from vague epigastric discomfort to recurrent intestinal obstruction [6]. Chronic post-prandial pain is another feature of this condition. Some cases may be found incidentally on imaging [5].

Although findings of this entity have been well described on barium studies [4], CT is the modality of choice in current radiology practice [2]. CT shows the variable location of herniated bowel loops. They may lie at the DJ junction between the stomach and the pancreas; between the transverse colon and the left adrenal gland; posterior to the pancreatic tail; or in the left anterior pararenal space [5, 7]. This may be associated with features of small-bowel obstruction in the form of dilated bowel loops and air-fluid levels. Dilated bowel loops may exert mass effect by displacing the stomach, DJ junction, or transverse colon. This may be associated with stretching, engorgement, or even torsion of mesenteric vessels. Unresolved obstruction may lead to sinister complications like ischemia and perforation.

The overall difficulty in the diagnosis of this uncommon condition is compounded further by the transient nature of herniation. This has often been hypothesized in the literature [3–5]. However, there is a scarcity of literature demonstrating spontaneous reduction. Parsons [3] and Meyers [4] demonstrated this on barium studies. There has been just a single report demonstrating this event on CT [8]. There, the authors repeated the CT after 5 days and found the spontaneous reduction.

## Conclusion

This report shows a case of spontaneous reduction of left paraduodenal hernia which is only the second case demonstrating this phenomenon. The radiologists should be aware of this uncommon entity and in the event of clinical suspicion; the imaging should be performed when the patient is symptomatic. Our patient had a recurrent course and exemplified the clinical manifestations of spontaneous reduction and re-herniation.

## Supplementary Information

The online version contains supplementary material available at <https://doi.org/10.1186/s43055-020-00338-4>.

**Additional file 1: Online resource 1.** Complete set of CECT axial images of abdomen in soft tissue window from study performed at presentation.

**Additional file 2: Online resource 2.** Complete set of CECT axial images of abdomen in soft tissue window from CECT study performed after 11 months.

## Abbreviations

PDH: Paraduodenal hernia; CECT: Contrast-enhanced computed tomography; CT: Computed tomography

## Acknowledgements

We would like to thank Dr. Samaresh Sahu for his support in conducting this study.

## Authors' contributions

SM conceptualized the design of this case report. SM and AK contributed to the acquisition and analysis of patient data and images. SB and VM contributed to the drafting and revision of the case report. UR contributed to the interpretation of images. All authors have agreed both to be personally accountable for their own contributions and they have ensured that questions related to the accuracy or integrity of any part of this work, even ones in which they were not personally involved, were appropriately investigated, resolved, and the resolution was documented in the literature. All authors have read and approved the manuscript.

## Funding

No one was paid during this study. The study did not have a source of funding. This study was not supported by a grant.

## Availability of data and materials

All data is available based on a reasonable request.

## Ethics approval and consent to participate

The present study was approved by the ethical board of the hospital in which the study was performed. The patient reported in this article had signed a written informed consent form. This case report was a reporting of a case in a medical educational center, in which all patients are informed that they may be subjects of scientific experiments and are informed of the ethical codes of conduct. This study was in compliance to the latest version of the Helsinki Declaration.

## Consent for publication

The patient had written and signed an informed consent note that the findings may be published without any personal detail.

## Competing interests

The authors declare that they have no competing interests.

## Author details

<sup>1</sup>Department of Radiodiagnosis and Imaging, Armed Forces Medical College, Pune, India. <sup>2</sup>Department of Radiodiagnosis and Imaging, Army Institute of Cardio-thoracic Sciences, Pune, India. <sup>3</sup>Department of Ophthalmology, Armed Forces Medical College, Pune, India.

Received: 14 August 2020 Accepted: 21 October 2020

Published online: 06 November 2020

## References

1. Newsom BD, Kukora JS (1986) Congenital and acquired internal hernias: unusual causes of small bowel obstruction. *Am J Surg* 152(3):279–285
2. Takeyama N, Gokan T, Ohgiya Y, Satoh S, Hashizume T, Hataya K, Kushihiro H, Nakanishi M, Kusano M, Munechika H (2005) CT of internal hernias. *Radiographics* 25(4):997–1015
3. Parsons PB (1953) Paraduodenal hernias. *Am J Roentgenol Radium Ther Nucl Med* 69(4):563

4. Meyers MA (1970) Paraduodenal hernias: radiologic and arteriographic diagnosis. *Radiology* 95(1):29–37
5. Doishita S, Takeshita T, Uchima Y, Kawasaki M, Shimono T, Yamashita A, Sugimoto M, Ninoi T, Shima H, Miki Y (2016) Internal hernias in the era of multidetector CT: correlation of imaging and surgical findings. *Radiographics* 36(1):88–106
6. Meyers MA (2006) *Dynamic radiology of the abdomen: normal and pathologic anatomy*, vol 179 Springer Science & Business Media
7. Martin LC, Merkle EM, Thompson WM (2006) Review of internal hernias: radiographic and clinical findings. *AJR Am J Roentgenol* 186(3):703–717
8. Ovali GY, Orguc S, Unlu M, Pabescu Y (2005) Transient left paraduodenal hernia. *Comput Med Imaging Graph* 29(6):459–461

## Publisher's Note

Springer Nature remains neutral with regard to jurisdictional claims in published maps and institutional affiliations.

**Submit your manuscript to a SpringerOpen<sup>®</sup> journal and benefit from:**

- Convenient online submission
- Rigorous peer review
- Open access: articles freely available online
- High visibility within the field
- Retaining the copyright to your article

---

Submit your next manuscript at ► [springeropen.com](https://www.springeropen.com)