

RESEARCH

Open Access



Diffusion-weighted imaging or MR spectroscopy: Which to use for the assessment of the response to chemotherapy in breast cancer patients?

Sahar Mansour^{1*} , Ashraf Selim¹, Loay Kassam², Mirna Adel² and Aya Bassam Hashem²

Abstract

Background: Diffusion-weighted MRI (DWI) and MR spectroscopy (MRS) both are noninvasive MR sequences that could be used as a reliable tool to assess the functional behavior of the breast cancer. The aim of the study was to assess the value of DWI and MRS in predicting the early response to neo-adjuvant chemotherapy (NAC) and absence of residual disease after treatment.

Results: One hundred thirty-three patients diagnosed with breast cancer and scheduled for NAC were enrolled in this study. All lesions were subjected to qualitative and quantitative analysis of DCE-MRI, DWI and MRS, where the lesions size, kinetic parameters, ADC values and MRS choline peak were recorded before the start of NAC and after completion of chemotherapy. The results of each MRI modality were correlated with the findings that were found at the pathology report of the complete surgical specimen. The sensitivity and specificity of the MR modalities to predict pathological complete remission post-NAC were 73.68% and 83.33%, respectively, using the kinetic curve pattern, 78.95% and 83.33%, respectively, using the ADC value and finally 78.95% and 91.67%, respectively, using the MRS choline peak. Similar sensitivity (89.47%) to predict pathological complete remission was presented by the ADC value and the MRS choline peak together when compared to the ADC value and dynamic curve patterns.

Conclusion: DWI and MRS are valuable MRI techniques and their accuracy in detecting residual disease is almost similar to that of DCE MRI. The inclusion of these sequences in the imaging protocol of NAC candidates improve monitoring of the response to treatment and allow early distinction between complete, partial and non-responders' cases in breast cancer patients.

Keywords: Breast cancer, MR spectroscopy (MRS), Diffusion-weighted MRI (DWI), Neo-adjuvant chemotherapy, Pathologic complete remission

Background

Neo-adjuvant chemotherapy (NAC) is used for the treatment of the breast cancer because it changes inoperable tumors into operable ones and downstage the involvement of the axillary nodes. So, it increases the probability

of breast conservative surgery. Furthermore, NAC helps in eliminating micrometastases [1–3].

The efficacy of NAC has to be monitored early in the regimen so that to determine the proper timing and type of operation required to be performed [3].

Breast MRI was shown to be the most accurate modality in the assessment of response to NAC. Recently, other MRI techniques have been explored as diffusion-weighted imaging (DWI) and magnetic resonance spectroscopy (MRS) [4].

*Correspondence: sahar_mnsr@yahoo.com

¹ Women's Imaging Unit, Radiology Department, Kasr El Ainy Hospital, Cairo University, El Manial, Cairo, Egypt

Full list of author information is available at the end of the article

DWI technique reflects water diffusion properties in the imaged tissues [5]. Chemotherapy causes cytotoxic effect on targeted masses which present as a less restrictive area for water to diffuse. Also, the increase in the values of the apparent diffusion coefficient elicited by the tumor may be considered as an indicator of response of treatment even before the detection of decrease in the tumor size [6].

MRS is another MR technique that reflects the chemical composition of tissue, where the changes in the total choline (tCho) signal may present treatment response than size changes [7].

So the aim of this work was to elucidate the role of DWI and MRS as noninvasive functional MR sequences in the assessment of tumor response to neo-adjuvant chemotherapy and to define which one of these techniques is more favorable to use in the context of predicting pathological complete remission (pCR).

Methods

Patients

The current prospective study included 133 patients with histopathologically proven invasive breast cancer whom were candidates for neo-adjuvant chemotherapy during the period between December 2018 and November 2020.

All patients were subjected to two multiparametric MRI examinations (DCE-MRI, DWI and MRS) which were done before starting and after completion of the course of the neo-adjuvant chemotherapy.

Excluded criteria were patients with: (1) early-stage breast cancer; (2) ductal carcinoma in situ, stage 0; and (3) stage I invasive cancer and those with contraindication to MRI and intravenous (IV) contrast injection.

Image analysis and interpretation were done by two radiologists in independent sessions. Each had more than 15 years of experience in the field of the breast imaging. The readers were blinded for each other analysis. The standard reference was the complete pathological operative specimen.

Diagnostic tools

All the MRI examinations were done using Philips (Achieva, Philips Medical System, Best, the Netherlands, Release 2.6 and Level 3) device of 1.5 Tesla magnet. Cases were imaged in the prone position with a dedicated breast coil (8 channels).

Dynamic contrast-enhanced MRI

Axial T1-weighted sequence spin echo (TR/TE 500/5.3 ms), sagittal and axial T2-weighted sequences (TR/TE 120/4.9 ms), axial T2-weighted inversion recovery-(TR/TE 80/6.5 ms), dynamic post-contrast acquisition were performed using six series of 3D THRIVE

acquisition—1 before and 5 after power injection of 0.1 mmol/kg BW of contrast with the parameters (TR/TE 2.8/9 ms) and slice thickness=1.5 mm. At the area of maximum enhancement, ROI was placed and kinetic curves were elicited to analyze amount of contrast uptake at the DCE-MRI.

DWI

DWI was performed using single-shot echo planar imaging, fat suppression, with TR/TE of 5000 ms/77 ms, respectively. Section thickness was 5 mm, field of view was 30 × 30 cm, matrix was 256 × 256 and total acquisition time was 7:14 min. The used b values were obtained at 0, 850 and 1000 s/mm².

ADC value calculation

The ADC values were measured manually by applying ROI on the breast carcinoma. Placement of the ROI was guided by areas of diffusion restriction (i.e., bright signal intensity on DWI and intermediate/low signal on the ADC maps). For large masses, a large ROI applied to cover as much as possible of the pathology, in case of masses with large central liquefaction or cystic component; multiple ROIs were applied to the abnormality marginal solid portion and the mean ADC value was the value considered later in the data calculation and analysis.

MRS

The T2 pre-contrast or the post-contrast subtracted images (depends on the conspicuity of the lesion) were used to identify the solid part of the lesion and guide the placement of the volume of interest (VOI). Localized single-voxel water- and fat-suppressed MR spectroscopy examinations were acquired from the tissue within the VOI by using PRESS technique. Average VOI size was 12 × 12 × 12 mm. 1H MRS was acquired using the following technical parameters: TR/TE, 2000/270 ms; spectral width 1000 Hz; and 1024 data points. The MRS scan time was 5 min and the shimming time ranged from 5 to 10 min according to lesion. Therefore, the total time to acquire MRS per one lesion, ranged from 10 to 15 min.

Image analysis

Subtraction images were first reviewed to detect the presence of lesion enhancement. 2.3.1 Cancer evaluation was carried out regarding:

1. Pattern of enhancement.
2. *Dynamic behavior of the mass*: with evaluation of the maximum relative enhancement as well as the type of time/signal intensity curve (type I, type II or type III). After NAC MRI studies, the worst curve pattern

was taken into consideration. Lesions that showed early washout curves were considered non-responders; lesions with persistent curve characteristics were considered responders; and lesions with plateau enhancement were indeterminate.

3. *Presence or absence of persistent restriction of the diffusion signal:* The persistent increase in the bright signal intensity in spite of the increase in the b value of the DW sequence that was suggestive of malignant cells and stability of the low ADC value was counted as a non-responder case. The increase in the ADC value by the end of therapy was suggested as a quantitative sign of tumor response.
4. *The presence of the choline metabolite and the value of the choline peak in the MRS study:* The decrease in the choline peak height and surface area, were counted as a case of responder to the chemotherapy.

Statistical analysis

Data were coded and entered using the statistical package SPSS (Statistical Package for the Social Sciences) version 25. Data were summarized using frequency (count) and relative frequency (percentage) for categorical data. For comparing categorical data, Chi-squared (χ^2) test was performed. Correlations between quantitative variables were done using Spearman correlation coefficient. Logistic regression was done to detect malignancy using combination of ADC, MRS and curve type. *P* value less than 0.05 was considered as a statistically significant value.

Results

This study included 133 proved malignant breast lesions, IDC represented (90.9%) and ILC represented (9.1%).

The MR images whether contrast- or non-contrast-based were assessed between the pre- and post-NAC studies, and the agreement of the readers at the initial independent readings was on 130/133 cases (kappa 0.96).

Mean age at diagnosis was 48 years (range 32–65 years).

Post-NAC multiparametric MRI characteristics

MRI showed regressive course regarding the size of the included tumors that showed mean diameter of 3.6 cm post-NAC instead of 4.9 cm pre-NAC (Figs. 1 and 2).

The curve patterns in post-NAC, showed mainly type I (45.5%) pattern in almost half of the cases, followed by type II (21.2%) and type III (33.3%). In the pre-therapy group, the dominant curve pattern was the type III, early washout curve pattern (72.7%).

ADC values equal to or below $1.043 \times 10^{-3} \text{ mm}^2/\text{s}$ together with the decrease in the degree of the restricted diffusion at the DWI were suggestive of response to therapy with sensitivity and specificity 96.9% and 66.7%, respectively. There were increase in the measured ADC value of 88% of the patients ($n=116$) (Figs. 1) and decreased or stationary value in 12% ($n=17$) (Figs. 2 and 3). The increase in the mean ADC value in the post-NAC patients presented by 1.06 compared to 0.7 in the pre-NAC cases. Mean ADC value for responders was $0.7 \times 10^{-3} \text{ mm}^2/\text{s} \pm 0.174 \text{ SD}$ in the pre-NAC and was improved to reach $1.3 \times 10^{-3} \text{ mm}^2/\text{s} \pm 0.242 \text{ SD}$ in the post-NAC MRI examinations.

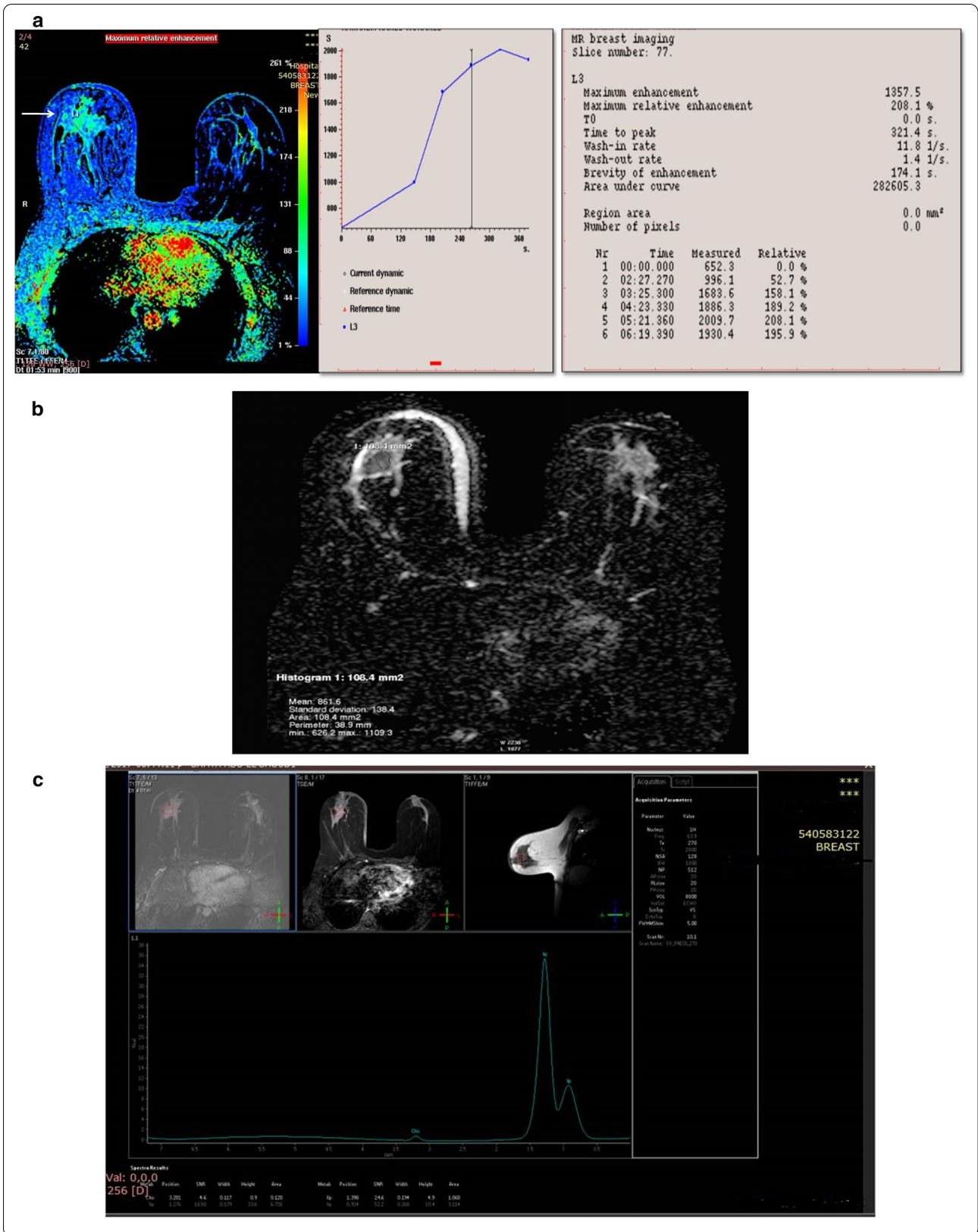
The mean value of the choline peak for the included carcinomas was 0.9 mmol/l and interquartile range was 0.3–2 mmol/l. The current work showed tCho peaks height more than 0.36 mmol/l value to be considered as non-responder case (Fig. 3). Sensitivity and specificity at that level achieved 71% and 71.4%, respectively. MRS choline peak reduced (i.e., improved) in 85% of cases ($n=113$) and remains stationary in 15% ($n=20$) with reduced responders mean MRS choline peak to 0.3 in the post-NAC MRI studies compared to 0.96 in the pre-NAC MRI studies.

Clinical, radiological and pathological response to neo-adjuvant chemotherapy

Complete radiological response (CRR) is defined as the absence of residual tumor in the breast and axillary lymph

(see figure on next page)

Fig. 1 A 34-year-old female presented with right breast lump. *Pre-therapy:* **a** Focal spiculated mass at the central portion of the right breast. Associate ipsilateral dermal thickening and interstitial edema with few pathologically enlarged right axillary lymph nodes (not seen in the figure). The mass showed delayed peak of contrast uptake at 260 s with corresponding maximum relative enhancement at 208% and delayed washout curve pattern **lb**. **b** ADC map showed intermediate signal of the tumor and a low ADC value of $0.861 \times 10^{-3} \text{ mm}^2/\text{s}$. **c** MRS was positive for choline (choline peak = 0.9 mmol/l). *Histopathology:* Invasive lobular carcinoma pleomorphic type grade II associated with lobular carcinoma in situ. *Immunohistopathology:* Negative for ER and PR, positive for HER 2 NEU (class 3+), Ki 67 15%. *Treatment decision:* Neo-adjuvant chemotherapy and breast conservative surgery. *Post-therapy:* **d** Dramatic reduction in the size of the right breast mass. The skin thickening of 4 mm is still noted. Faint contrast uptake was noted at the confine of the right breast mass, arrow (note, a clip is seen inserted within the vicinity of the mass), with marked reduction in the percentage of signal intensity to be 23%. **e** DWI examination showed increased ADC value of $1.255 \times 10^{-3} \text{ mm}^2/\text{s}$. **f** MRS showed favorable post-chemotherapeutic response in the form of reduced choline peak to reach 0.2 mmol/l. *Pathology report of the surgical specimen:* Tiny remnants of intra duct carcinoma surrounded by hyalinosis. Examination of sentinel lymph nodes showed positive metastatic deposits (1/1). All of the dissected axillary lymph nodes were negative for metastatic deposits (0/11). The surgical margins were free. *Comments:* Near complete pathological and radiological response



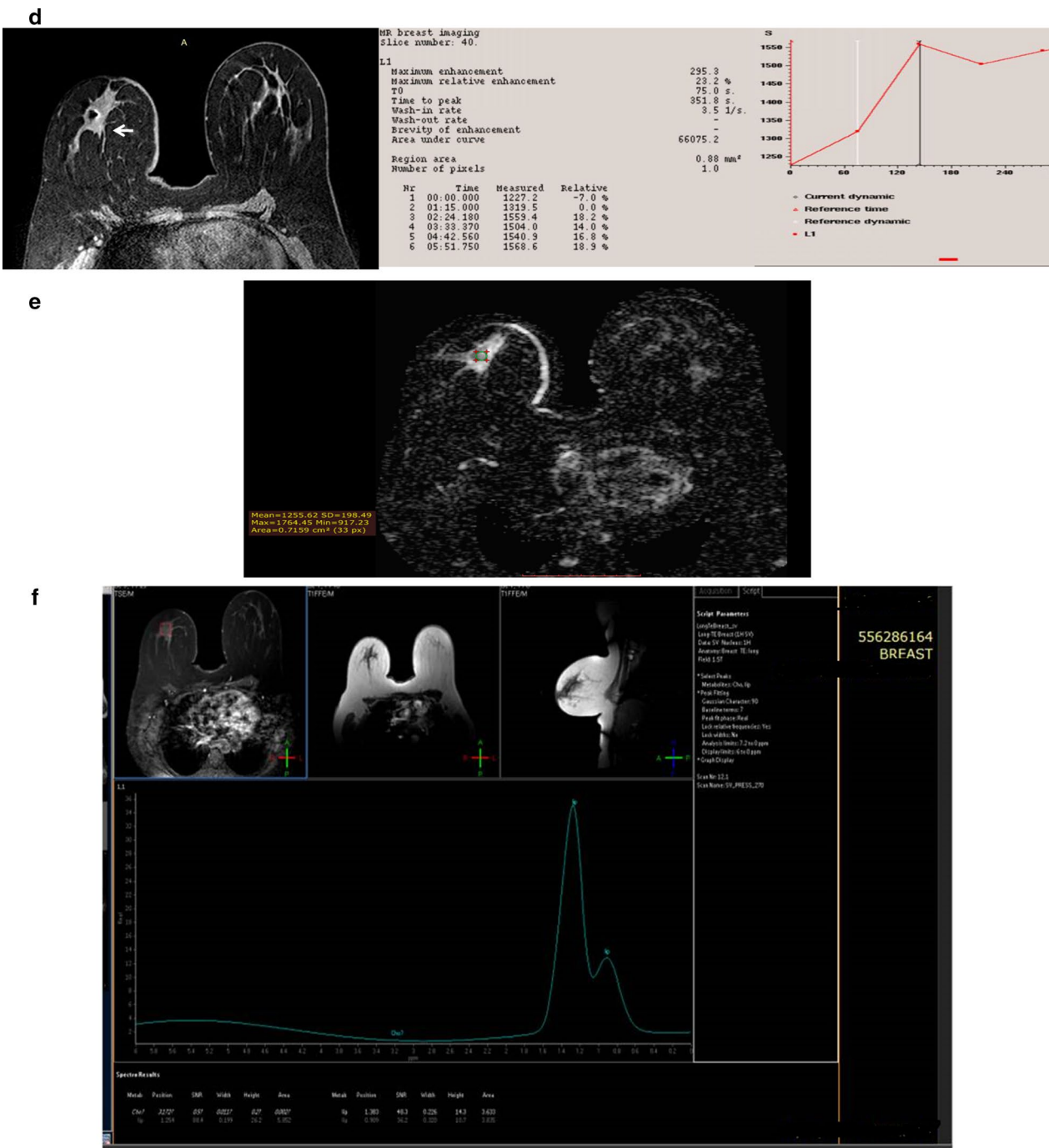


Fig. 1 continued

nodes. Such suggestion was justified by: (1) the absence of pathological contrast enhancement and benign curve pattern on the dynamic post-contrast study, (2) non-restricted (fade of the bright signal on delayed b value images) and relatively high ADC value, and (3) decrease or absence of the choline peak located at 3.2 ppm of the spectrum. Pathological complete remission (pCR) is defined as complete disappearance of any invasive cancer cells in the excised breast tissue and lymph nodes. The presence of residual DCIS or LCIS did not affect our definition of pCR (Fig. 1).

After completion of the sessions of the neo-adjuvant chemotherapy, 18% of the included cases ($n=24$) achieved complete pathological remission for both the breast and the axilla on clinical basis. Partial remission was presented by 70% ($n=93$), stationary disease was shown by 9% ($n=12$) and four patients presented with missing final clinical response after NAC completion (3%). Among those who did not achieve pCR ($n=109$), there were 48 patients (36.1%) whom achieved clinical pCR for the breast alone.

In the current study, 16 patients achieved both CRR and pCR (33.3%), and three patients with CRR were false positive for pCR as the conventional MRI could not detect microfoci of IDC. However, the interpretation of the different sequences of MRI was able to detect 88% of the cases with residual tumor after NAC (Fig. 3).

Diagnostic indices of different MRI modalities to predict pathological complete remission (pCR)

The sensitivity of the ADC value or the choline peak as a single parameter achieved 78.95% (higher than the dynamic curve pattern); however, choline peak had the highest specificity (91.67%) and PPV (93.75%) compared to the ADC value and the dynamic curve pattern. The addition of the ADC value or the MRS choline peak to the dynamic curve patterns in the assessment of the included breast cancers had increased the sensitivity to 89.4% and 78.9%, respectively, instead of 73.68% for the assessment by the dynamic curve pattern alone (Figs. 2 and 3). The sensitivity of combined performance of the ADC value and the MRS choline peak was equal to the

diagnostic performance of the addition of the ADC value to the dynamic curve pattern in the evaluation (89.47%) of the included breast cancers. Such data raise the possibility to use DWI supported by the ADC value in the assessment of cases candidate for neo-adjuvant chemotherapy when contrast administration is contraindicated as in renal failures, allergies or pregnant patients. Statistical indices of the combined evaluation of the dynamic curve pattern, the ADC value and the MRS choline peak achieved 89.47% sensitivity, 83.33% specificity and 87.10% total accuracy. The detailed diagnostic indices of the 3 techniques whether individually and combined are shown in Table 1.

The relation between the increase in the ADC value in the post-NAC patients and the decreased choline peak MRS in the post-NAC ones to predict pathological complete remission is demonstrated in Table 2.

Discussion

The principal goals of NAC in breast cancer are to reduce tumor volume and to provide an opportunity to monitor an individual patient's response and tailor her therapeutic regimen. Such adaptive therapy requires a minimally invasive means to distinguish responders from non-responders early in the course of treatment [8].

Monitoring response to NAC by CE-MRI was studied in various studies and showed that its accuracy to predict pathologic complete remission has a moderate sensitivity. Recently, the idea that DWI and MRS might be able to compensate has been raised [9].

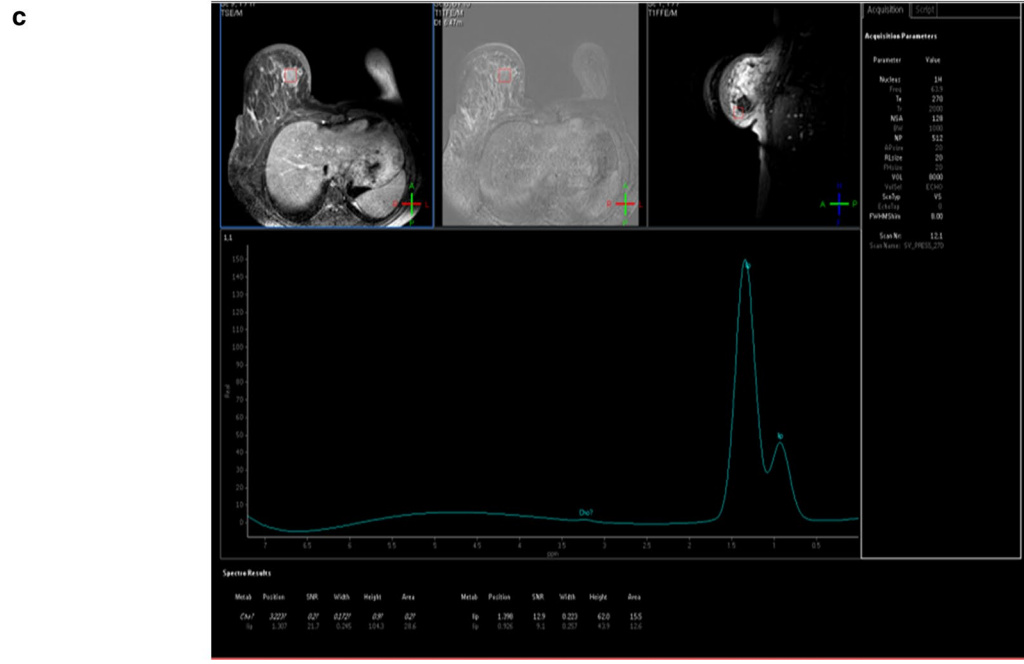
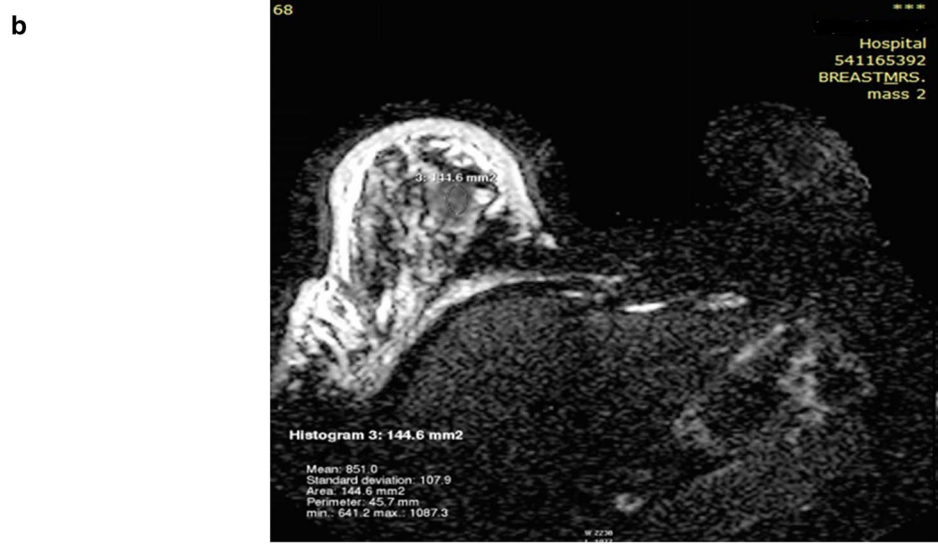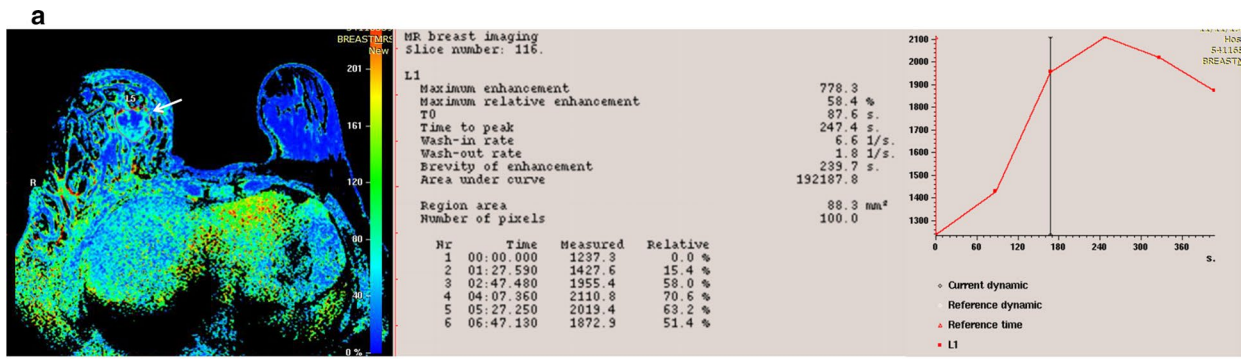
The aim of this work was to study the value of the functional non-contrast-based MR imaging sequences as DWI and the MRS in the follow-up of the response to NAC in the breast cancer patients before surgery.

To our knowledge, there is paucity in the literature about this subject and most of the articles studied only solitary functional sequence. Comparative works between these non-contrast-based MR sequences were not potential.

Regarding the enhancement parameters in the current study, after completion of NAC, the maximum

(see figure on next page)

Fig. 2 A 34-year-old female presented with right breast lump. *Pre-therapy:* **a** Right breast lower inner quadrant indistinct mass with extensive skin edema (peau d'orange). The mass showed delayed peak of contrast uptake at 274 s with corresponding signal intensity percentage of 58% and delayed washout curve pattern type Ib. **b** Right lower inner quadrant mass (ADC value = $0.851 \times 10^{-3} \text{ mm}^2$). **c** MRS was positive for choline (choline peak = 0.9 mmol/l). *Histopathology:* Invasive ductal carcinoma, grade III. *Immunohistopathology:* Negative for ER and PR, positive for HER2/NEU (class 3+), Ki 67 high proliferation index. *Treatment decision:* Neo-adjuvant chemotherapy and modified radical mastectomy. *Post-therapy:* **d** Regressive course regarding the size of the right lower inner quadrant mass. The right breast dominant mass (at the upper inner quadrant) showed faint contrast uptake. Kinetics displayed signal intensity percentage of 35% and progressively rising curve pattern- type I. Also, there was mild regression of previously noted dermal edema seen. **e** DWI showed restricted diffusion and an ADC value of $0.730 \times 10^{-3} \text{ mm}^2/\text{s}$. **f** MRS showed choline peak of 0.4 mmol/l height value. *Pathology report of the surgical specimen:* Gritty mass with wide area of necrosis (partial tumor response). Free deep surgical margins. Metastatic deposits were found in 7 from 12 dissected axillary lymph nodes. *Comments:* Partial pathological and radiological response



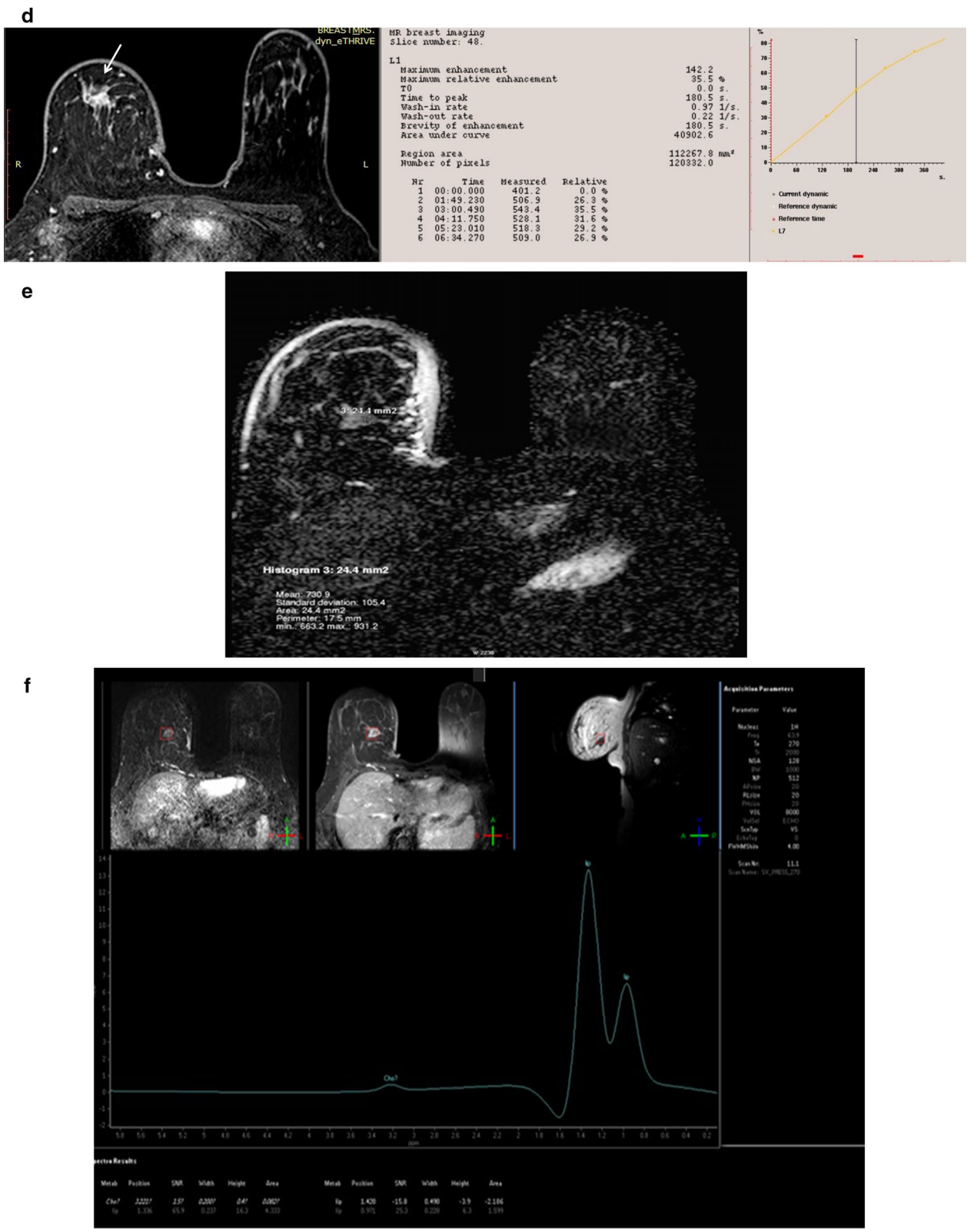


Fig. 2 continued

relative enhancement decreased and the time peak of contrast uptake was increased in responders while there were no significant changes in non-responders. Regarding the dynamic curve patterns, changes were noted between the typical malignant phenotype and the less aggressive phenotype in responders. These results were in agreement with a study by Wang et al. [10] where the maximum relative enhancement of responders decreased significantly, and time peak of contrast uptake increased significantly ($P < 0.001$), while in non-responders there was no significant change ($P > 0.05$). Dynamic signal intensity–time curves tended to significantly flatten after NAC in responders (type I occupied 63.9%), with no significant change in non-responders.

In this work, the ADC value as a single parameter to predict pCR achieved 78.95% sensitivity, 83.33% specificity and 80.65% total accuracy. The additive role of DWI to conventional DCE-MRI enhanced the diagnostic indices to 89.47% sensitivity, 83.87% total accuracy (compared to 73.68% and 77.42%, respectively, in case of DCE-MRI alone). A study by Gao et al. [11] combined data from 20 studies and stated that for assessing pCR after NACT, DWI could be a valuable tool with 89% sensitivity and 72% specificity.

In the current work, a cutoff ADC value of $1.043 \times 10^{-3} \text{ mm}^2/\text{s}$ presented the best statistical indices' to distinguish responders from non-responders with a sensitivity of 96.9%, specificity of 66.7% and total accuracy of 87.2%. A study by Fangberget et al. [12] showed that an ADC cutoff value of $1.42 \times 10^{-3} \text{ mm}^2/\text{s}$ (at $b = 750 \text{ s}/\text{mm}^2$) was suggested as the optimal value with a sensitivity and specificity to distinguish pCR after chemotherapy of 88% and 80%, respectively.

A study by Park et al. [13] elicited that after 3–6 cycles of NAC, the best cutoff for differentiating pCR from non-pCR was a 54.9% increase in the ADC value, which could reach 100% sensitivity and 70.4% specificity. El bakoury et al. [14] assumed a cutoff value of 20%

increase in the ADC value after the first cycle of chemotherapy as indicative of pCR.

Pereira et al. [15] observed significant early increase in the ADC value in responders that precedes reduction in tumor size measured at CE-MRI.

Sharma et al. [16] also believed in significant correlation between the increased ADC value and the treatment response.

On the contrary, Woodhams et al. [6] and Elbakoury et al. [14] stated that the increase in ADC did not correlate with the change in the size of the tumor that was measured at the CE-MRI and pathological response.

The study analysis presented the idea that the post-NAC MRI in most of the responders were characterized by fading of the bright signal on the high b -value DWI-MR images and a slightly bright signal on the ADC maps, which was indicative of apparently free diffusion of water molecules and subsequently low ADC values.

However, one of the major limitations of DWI was encountered which was its low spatial resolution so small cancer foci, including DCIS and scattered foci of invasive lobular cancer, sometimes was not that obvious at DWI.

The current study suggested a cutoff value of 0.36 mmol/l to target the tCho peak and it presented 71.0% sensitivity and 71.4% specificity. The diagnostic indices of choline peak as single parameter to predict pathological complete remission post-NAC showed 78.95% sensitivity and had the highest specificity (91.67%) and PPV (93.75%). The statistical indices were enhanced when the diagnostic performance of the dynamic post-contrast curve and MRS was combined in the post-NAC patients to reach up a value of 78.95% sensitivity, 91.67% specificity and 83.87% total accuracy (compared to 73.68%, 83.3% and 77.42%, respectively, in case of DCE-MRI alone).

Baek et al. [17] stated that at first follow-up tCho concentration changes were not significantly different between patients achieving pCR and those not achieving pCR. However, at second follow-up tCho decreased by

(see figure on next page)

Fig. 3 A 44-year-old female presented with left breast upper outer quadrant mass. *Pre-therapy:* **a** The left breast showed a sizable partly spiculated solid mass at the upper outer quadrant that displayed rim enhancement in the post-contrast MR images. It was seen closely adherent and infiltrating the overlying skin along the outer aspect of the breast. Kinetic curve showed maximum relative enhancement of 134% and type III early washout curve pattern. **b** DWI showed restricted diffusion and a low ADC value of $0.767 \times 10^{-3} \text{ mm}^2/\text{s}$. **c** MRS was positive for choline (choline peak = 1.0 mmol/l). *Histopathology:* Invasive ductal carcinoma, grade II. *Immunohistopathology:* ER (4/8) and PR (8/8), negative for HER 2 NEU and Ki 67 30%. *Treatment decision:* Neo-adjuvant chemotherapy and breast conservative surgery. *Post-therapy:* **d** The lesion showed delayed peak of contrast uptake at 448 s with corresponding signal intensity percentage of 109% and benign type curve pattern. **e** DWI showed restricted diffusion and displayed also low ADC value of $0.830 \times 10^{-3} \text{ mm}^2/\text{s}$. **f** Choline peak on the MRS images was still positive of estimated height value of 0.9 mmol/l. *Pathology report of surgical specimen:* A whitish gritty irregular mass reaching the skin surface that measured 3.2 cm along its maximal diameter with picture of invasive duct carcinoma grade II and associated lobular features. Free surgical margins. One of the dissected lymph nodes showed metastatic deposits (1/5). *Comments:* Radiological and pathological non-responder. The case showed stationary size and the findings at the post-contrast series gave false impression of response. DWI and MRS showed malignant criteria and suggested the accurate diagnosis of a non-responder case that was proved by the pathology report after surgery

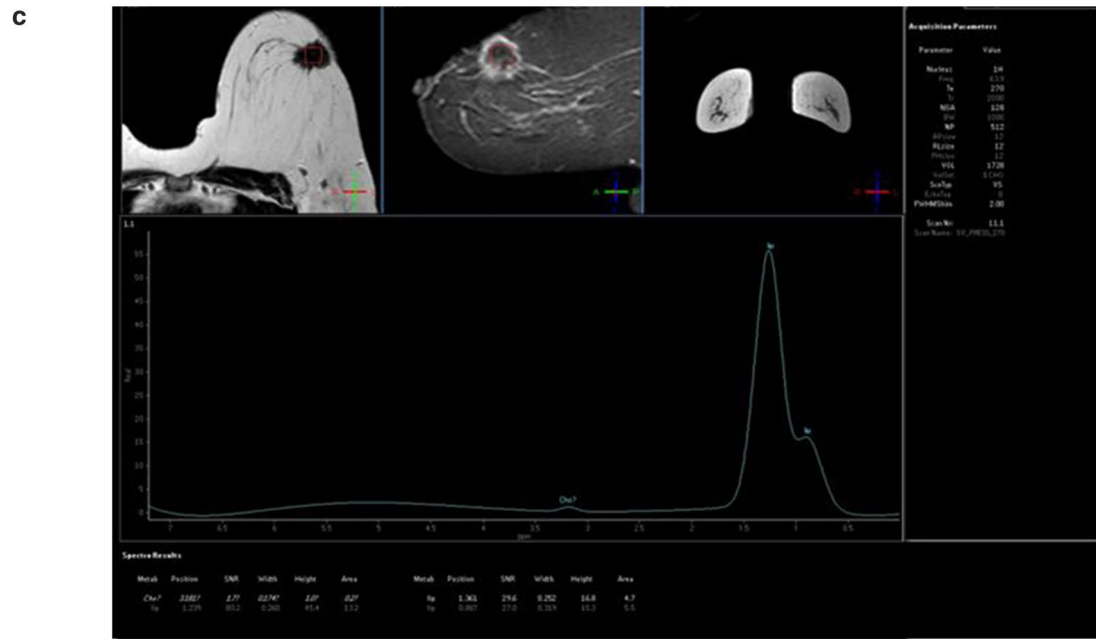
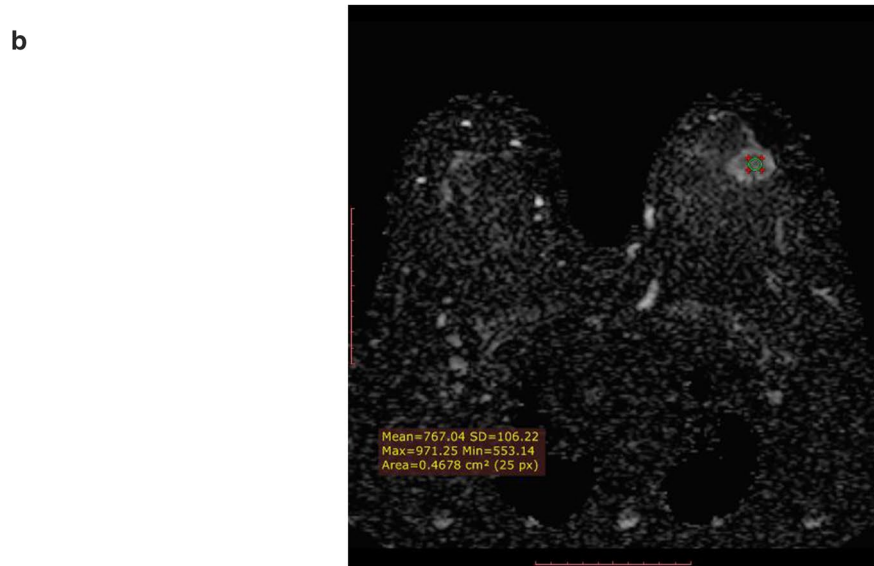
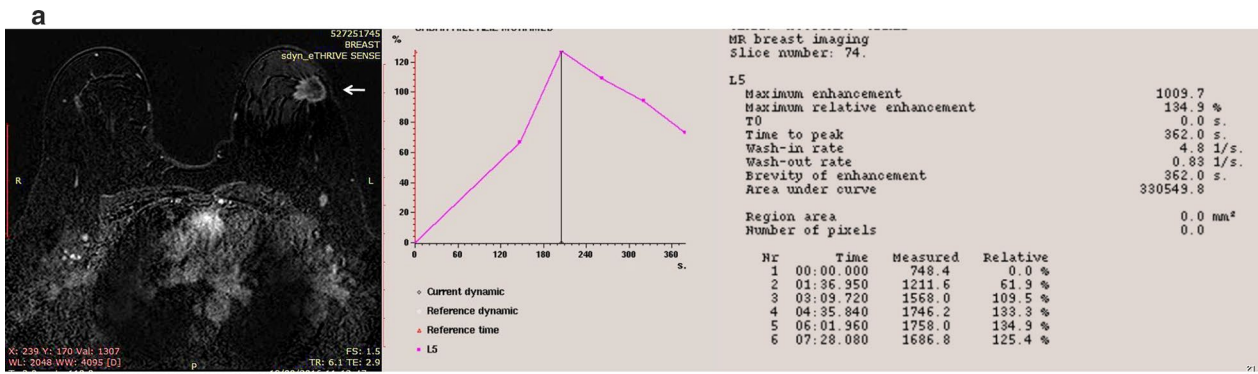


Table 1 Diagnostic indices of different MRI modalities individually and combined to predict pathological complete remission (pCR)

Statistic	ADC (%)	MRS (%)	Curve type (%)	ADC + MRS (%)	ADC + curve type (%)	MRS + curve type (%)	MRS + CURVE type + ADC (%)
Sensitivity	78.95	78.95	73.68	89.47	89.47	78.95	89.47
Specificity	83.33	91.67	83.33	83.33	75.00	91.67	83.33
PPV	88.24	93.75	87.50	89.47	85.00	93.75	89.47
NPV	71.43	73.33	66.67	83.33	81.82	73.33	83.33
Accuracy	80.65	83.87	77.42	87.10	83.87	83.87	87.10

The Values in Bold are the values that clarify the solo role of the ADC values and MRS and show the relevant modality to predict complete cancer remission

Table 2 Cross-tabulation representing relation between increase post-NAC ADC value and decrease post-NAC MRS choline peak to predict pathological complete remission

	Pathological CR yes/no for both breast and axilla				P value
	Yes		No		
	Count	Column N (%)	Count	Column N (%)	
<i>ADC post-pre-group</i>					
Increased	20	83.3	89	88.0	1
Decreased	4	16.7	12	12.0	
<i>MRS choline peak post-pre-grouped</i>					
Decreased	16	66.7	89	88.0	0.241
Same	8	33.3	12	12.0	

100% in patients achieving pCR (versus 67% in patients not achieving pCR, $P=0.01$).

Moreover, Tozaki et al. [18] concluded that the tCho changes after the second cycle may be more sensitive than changes in the tumor size to predict the pathological response.

Baek et al. [7] also reported that with responders there was an average reduction of 50% in tCho level after one or two cycles of NACT (compared to 14% in non-responders) and the mean percentage lesion size reduction was 18% (compared to 15% in non-responders).

The results of these studies were in agreement with the current work: The early metabolic changes were more evident than the changes in tumor size. Also, after completion of NAC, MRS choline peak was reduced in 85% ($n=113$) and remained stationary in 15% ($n=20$) with reduced mean MRS choline peak post-NAC to 0.36 in responders versus 0.95 in non-responders.

On the contrary, a limited data set presented by Bolan's study [19] that focused on the early changes in tCho levels measured 1–4 days after starting chemotherapy where the early decrease in the tCho after chemotherapy initiation presented a poor predictive ability for pCR or radiologic response.

Few studies attempted to compare the evaluation of post-NAC response using both of MRS and DWI

techniques, where the resultant data showed mixed values. Mountford et al. [20] showed that MRS provided substantial prognostic information, slightly more than that provided by volume measurements. They also noted ADC mapping after the second course of NAC did not contribute significantly toward detecting early response.

In another study, Shin et al. [21] found that the post-NAC percentage changes in two parameters of the MRS (absolute and normalized tCho integral) in the pCR group were significantly higher than in the non-responder group ($P=0.020$ and 0.023) but the change in tCho SNR was not significantly different between the two groups. They also reported that the percentage change of the ADC value in the pCR group was significantly higher than that in the non-pCR group (81.3% vs. 12.6%; $P<0.001$). The post-treatment ADC value in the pCR group ($1.43 \times 10^{-3} \text{ mm}^2/\text{s}$) was significantly higher than that in the non-pCR group ($1.10 \times 10^{-3} \text{ mm}^2/\text{s}$) ($P=0.003$). They found that combination of the MRS and the DWI parameters did not provide additional predictive value compared with the predictive value of a single parameter.

These results were in agreement with the results of the current work; the mean post-treatment (i.e., post-NAC) ADC value in the pCR group ($1.3 \times 10^{-3} \text{ mm}^2/\text{s}$) was higher than that in the non-pCR group

(0.95×10^{-3} mm²/s). But on the contrary, the present study showed that the combination of the MRS and the DWI parameters increased the sensitivity and the diagnostic accuracy of the dynamic post-contrast MR imaging in its role in following up response of neo-adjuvant chemotherapy in reported cases of breast cancer and achieved 89.47% sensitivity and 87.10% accuracy compared to 73.68% and 77.42%, respectively, in case of the solo assessment of the post-contrast dynamic curve.

Previously, when the size of the cancer showed no significant regression, the intensity of the contrast uptake was the criterion to rely upon to check response to therapy and so the presence of benign behavior of contrast uptake and the decreased signal intensity in spite of the stationary size of the tumor were considered response to the therapy. The current work showed cases that presented with no enhancement of the breast cancer on post-contrast MRI yet, on DWI and MRS, the findings suggested non-responder case and the pathology report after the surgery confirmed the data presented by the non-contrast functional MR sequences.

Tozaki et al. [18] assessed the change of the integral value of tCho after the first cycle of NAC in comparison with measurements of the ADC value in seven patients. The change of the tCho showed a positive correlation regarding the change in the lesion size ($r=0.91$, $P=0.01$). However, no correlation was observed between the change of the ADC value and the change in the lesion size ($r=0.45$, $P=0.32$). They concluded that MRS after the first cycle may be more sensitive in predicting pathological response(s) than DWI.

In another study by Bathen et al. [22], sixteen patients were evaluated who returned for a follow-up MRS after the first cycle of chemotherapy; eight of them were defined as responders and another eight as non-responders. The reduction in tCho SNR was significant for both responders ($P=0.025$) and non-responders ($P=0.012$). The DWI technique was described in the study, but no discussion or conclusion was made about the result and predictive value of the DWI.

In the current study, the increase in the ADC value post-NAC is associated with the reduction or normalization of the MRS choline peak, and this was considered as an indicator for the detection of responders that could achieve pCR. The current study presented 24 patients who achieved pCR for both breast and axilla: 16 patients had an increase in the ADC value with normalized MRS choline peak that was a true positive indication for pCR, four patients with stationary MRS choline and reduced ADC value and another four patients with increased ADC value and stationary MRS choline peak that was false positive for residual malignancy.

The study may be limited by: (1) the use of 1.5 Tesla magnet MRI machine for the performance of the functional MR imaging especially DWI and MRS which require higher values (≥ 3 T) to achieve accurate assessment of the tumor size/extension and consequently provide more accurate estimation of the ADC values and the height of the choline peak. (2) There is an element of operator variability in application of ROI for the ADC value or acquisition voxel placement at MRS.

Conclusion

DWI and MRS are non-contrast-based techniques that provide equal performance to the traditional dynamic post-contrast MR imaging. The addition of these techniques to the imaging protocol of the candidates of NAC improves monitoring of the response to treatment and allows early distinction between complete, partial and non-responder patients of breast cancer.

Abbreviations

AC: Adriamycin and cyclophosphamide; ADC: Apparent diffusion coefficient; BCS: Breast conservative surgery; CE-MRI: Contrast-enhanced magnetic resonance imaging; CRR: Complete radiological response; DCIS: Ductal carcinoma in situ; DCE-MRI: Dynamic contrast-enhanced magnetic resonance imaging; DWI: Diffusion-weighted imaging; HER2: Human epidermal growth factor receptor 2; 1H MRS: Proton MR spectroscopy; MRM: Modified radical mastectomy; MRS: MR spectroscopy; NAC: Neo-adjuvant chemotherapy; pCR: Pathological complete remission; SNR: Signal-to-noise ratio; THRIVE: T1 high-resolution isotropic volumetric examination; TR: Repetition time; TE: Echo time.

Acknowledgements

We would like to acknowledge the head of Women's imaging unit, Radiology department, Cairo University, Prof. Dr. Rasha Kamal, who helped the authors throughout this work.

Authors' contributions

SA is the guarantor of integrity of the entire study. KL and MS contributed to the study concepts and design. MS, AM and HLB contributed to the literature research. MS, HLB, KL and AM contributed to the clinical studies. MS and SS contributed to the experimental studies/data analysis. MS, KL and AM contributed to the statistical analysis. MS, KL and AM contributed to the manuscript preparation. MS, HLB and AM contributed to the manuscript editing. All authors have read and approved the final manuscript.

Funding

No source of funding.

Availability of data and materials

The corresponding author is responsible for sending the used data and materials upon request.

Declarations

Ethics approval and consent to participate

The study was approved by the ethical committee of the Radiology Department of El Kasr ElAiny Hospital, Cairo University, which is an academic governmental supported highly specialized multidisciplinary hospital. The included patients gave written informed consent.

Committee's reference number

Not applicable.

Consent for publication

All patients included in this research were legible, above 16 years of age. They gave written informed consent to publish the data contained within this study.

Competing interests

The authors declare that they have no competing interests.

Author details

¹Women's Imaging Unit, Radiology Department, Kasr El Ainy Hospital, Cairo University, El Manial, Cairo, Egypt. ²Oncology Department, Kasr El Ainy Hospital, Cairo University, Cairo, Egypt.

Received: 4 May 2021 Accepted: 27 July 2021

Published online: 03 August 2021

References

- Kaufmann M, von Minckwitz G, Mamounas EP, Cameron D, Carey LA, Masimo Cristofanilli M et al (2012) Recommendations from an international consensus conference on the current status and future of neoadjuvant systemic therapy in primary breast cancer. *Ann Surg Oncol* 19:1508–1516
- Hylton NM, Blume JD, Bernreuter WK, Pisano ED, Rosen MA, Morris EA et al (2012) Locally advanced breast cancer: MR imaging for prediction of response to neoadjuvant chemotherapy—results from ACRIN 6657/I-SPY trial. *Radiology* 263:663–672
- Li L, Wang K, Sun X, Wang K, Sun Y, Zhang G et al (2015) Parameters of dynamic contrast-enhanced MRI as imaging markers for angiogenesis and proliferation in human breast cancer. *Med Sci Monit* 21:376–382
- Pinker K, Bogner W, Baltzer P, Gruber S, Bickel H, Brueck B et al (2014) Improved diagnostic accuracy with multiparametric magnetic resonance imaging of the breast using dynamic contrast enhanced magnetic resonance imaging, diffusion-weighted imaging, and 3-dimensional proton magnetic resonance spectroscopic imaging. *Investig Radiol* 49(6):421–430
- Nilsen L, Fangberget A, Geier O, Olsen RD, Seierstad T et al (2010) Diffusion-weighted magnetic resonance imaging for pretreatment prediction and monitoring of treatment response of patients with locally advanced breast cancer undergoing neoadjuvant chemotherapy. *Acta Oncol* 49:354–360
- Woodhams R, Kakita S, Hata H, Iwabuchi K, Kuranami M, Gautam S et al (2010) Identification of residual breast carcinoma following neoadjuvant chemotherapy: diffusion-weighted imaging—comparison with contrast-enhanced MR imaging and pathologic findings. *Radiology* 254:357–366
- Baek HM, Chen JH, Nie K, Yu HJ, Bahri S, Mehta RS et al (2009) Predicting pathologic response to neoadjuvant chemotherapy in breast cancer by using MR imaging and quantitative ¹H MR spectroscopy. *Radiology* 251:653–662
- Dobruch-Sobczak K, Piotrkowska-Wróblewska H, Klimoda Z, Secomski W, Karwat P, Markiewicz-Grodzicka F et al (2019) Monitoring the response to neoadjuvant chemotherapy in patients with breast cancer using ultrasound scattering coefficient: a preliminary report. *J Ultrason* 19(77):89–97
- Marinovich ML, Sardaneli F, Ciatto S, Mamounas E, Brennan M, Macaskill P et al (2012) Early prediction of pathologic response to neoadjuvant therapy in breast cancer: systematic review of the accuracy of MRI. *Breast* 21(5):669–677
- Wang X, Peng W, Tan H, Xin C, Mao J (2010) Evaluation of dynamic contrast-enhanced MRI in monitoring early response of locally advanced breast cancer to neoadjuvant chemotherapy. *Chin Ger J Clin Oncol* 9(11):637–642
- Gao W, Guo N, Dong T (2018) Diffusion-weighted imaging in monitoring the pathological response to neoadjuvant chemotherapy in patients with breast cancer: a meta-analysis. *World J Surg Oncol* 16:145
- Fangberget A, Nilsen LB, Hole KH, Holmen MM, Engebraaten O, Naume B et al (2011) Neoadjuvant chemotherapy in breast cancer—response evaluation and prediction of response to treatment using dynamic contrast-enhanced and diffusion-weighted MR imaging. *Eur Radiol* 21:1188–1199
- Park SH, Moon WK, Cho N, Chang JM, Im S, Park IA et al (2012) Comparison of diffusion-weighted MR imaging and FDG PET/CT to predict pathological complete response to neoadjuvant chemotherapy in patients with breast cancer. *Eur Radiol* 22:18–25
- El-bakoury E, Khalil R, Abdelhamid A, Darwish A, Hassan H (2017) Diffusion weighted imaging in early prediction of neoadjuvant chemotherapy response in breast cancer. *Egypt J Radiol Nucl Med* 48(2):529–535
- Pereira FP, Martins G, Figueiredo E, Domingues MNA, Domingues RC, Barbosa da Fonseca LM et al (2009) Assessment of breast lesions with diffusion weighted MRI: comparing the use of different b values. *AJR Am J Roentgenol* 193(4):1030–1035
- Sharma U, Danishad KK, Seenu V, Jagannathan NR (2009) Longitudinal study of the assessment by MRI and diffusion-weighted imaging of tumor response in patients with locally advanced breast cancer undergoing neoadjuvant chemotherapy. *NMR Biomed* 22:104–113
- Baek HM, Chen JH, Nalcioglu O, Su MY (2008) Proton MR spectroscopy for monitoring early treatment response of breast cancer to neo-adjuvant chemotherapy. *Ann Oncol* 19:1022–U9
- Tozaki M, Sakamoto M, Oyama Y, Maruyama K, Fukuma E (2010) Predicting pathological response to neoadjuvant chemotherapy in breast cancer with quantitative H-1 MR spectroscopy using the external standard method. *J Magn Reson Imaging* 31:895–902
- Bolan PJ (2013) Magnetic resonance spectroscopy of the breast: current status. *Magn Reson Imaging Clin N Am* 21(3):625–39
- Mountford CE, Lean C, Malycha P, Russell P (2006) Proton spectroscopy provides accurate pathology on biopsy and in vivo. *J Magn Reson Imaging* 24(3):459–77
- Shin HJ, Baek HM, Cha JH, Kim HH (2012) Evaluation of breast cancer using proton MR spectroscopy: total choline peak integral and signal-to-noise ratio as prognostic indicators. *AJR Am J Roentgenol* 198(5):W488–97
- Bathen TF, Heldahl MG, Sitter B, Vettukattil R, Bofin A, Lundgren S et al (2011) In vivo MRS of locally advanced breast cancer: characteristics related to negative or positive choline detection and early monitoring of treatment response. *Magn Reson Mater Phys* 24(6):347–57

Publisher's Note

Springer Nature remains neutral with regard to jurisdictional claims in published maps and institutional affiliations.

Submit your manuscript to a SpringerOpen[®] journal and benefit from:

- Convenient online submission
- Rigorous peer review
- Open access: articles freely available online
- High visibility within the field
- Retaining the copyright to your article

Submit your next manuscript at ► [springeropen.com](https://www.springeropen.com)