

CASE REPORT

Open Access



The thin line that made the difference: a case report on a Bosniak IIF renal cystic mass treated with cyst decortication

Ali Forookhi¹, Marco Bicchetti¹, Sara Lucciola¹, Angelo Porreca², Gian Maria Busetto³ and Maurizio Del Monte^{1*}

Abstract

Background: Among all benign kidney lesions, renal cysts are the most common type. In the proposed update of 2019, the Bosniak classification of cystic renal masses is used to classify renal masses according to their likelihood of malignancy, both on computed tomography (CT) and on magnetic resonance imaging (MRI).

Case presentation: A middle-aged Caucasian male presented to our department with chronic right flank pain. Imaging studies revealed a right renal Bosniak IIF cyst, later complicated by traumatic haemorrhage. The patient consequently underwent cyst decortication for symptom relief. Biopsy results from samples taken during the laparoscopic operation revealed ISUP grade 1 cystic clear cell carcinoma.

Conclusion: The treatment of Bosniak IIF cysts has long been a matter of debate. As a result of scarcity of data on the probability of malignancy in MRI using the new classification, such cysts should be carefully scrutinised and staged before choosing a treatment option. Retroperitoneal seeding should always be considered in interventions involving an incomplete resection margin or cyst drainage.

Keywords: Renal cyst, Bosniak classification, Computed tomography, Magnetic resonance imaging

Background

A major focus in genitourinary radiology has been to classify renal cysts due to the multitude of presentations of renal cell carcinomas, including cystic variants [1]. Cystic lesions become significantly more likely to correspond to renal cell carcinoma (cystic variant) when their walls are enhancing and irregular, when septae are thick and numerous, and when nodular calcifications and solid tissue are present.

In the recently proposed update for 2019, Silverman et al. proposed a Bosniak classification of cystic renal masses based not only on computed tomography (CT), but also on magnetic resonance imaging (MRI).

Considering how recent the proposal is, there are limited data on the performance of the classification system for the assessment of malignant renal cysts found on MRI [2].

According to current recommendations, Bosniak IIF cystic renal masses should be imaged at 6 months and 12 months, followed by annual follow-ups for 5 years in order to evaluate for changes in morphological complexity [3, 4]. In this report, we present an exceptional case of a patient with complicated Bosniak IIF cystic renal mass who subsequently underwent cyst decortication for symptomatic relief.

Case presentation

A 43-year-old Caucasian male patient presented to the urology clinic complaining of a dull ache in the right flank for the past month. The patient had no relevant past medical history. Family history was negative for renal cell carcinoma. Physical examination revealed no palpable mass

*Correspondence: delmontemaurizio250285@gmail.com

¹ Department of Radiological Science, Oncology and Pathology, Sapienza University/Policlinico Umberto I, Viale Regina Elena 324, 00161 Rome, Italy
Full list of author information is available at the end of the article

nor any other significant findings. The patient reported no history of fever, oliguria, frequency, urgency, dysuria, or haematuria. A point-of-care ultrasound (POCUS) was performed to reveal a heterogeneous mass of moderate complexity with mild posterior acoustic enhancement in the right kidney. A referral to radiology at our tertiary referral centre was made for a follow-up MRI in order to characterise the mass.

Images were acquired on a 3T scanner (Discovery MR750, GE Healthcare) using a 32-multichannel surface phased-array body coil. The protocol included axial and coronal T2-weighted imaging (T2WI) spin echo, axial diffusion-weighted imaging (DWI) with apparent diffusion coefficient (ADC) map calculation and 2D T1WI gradient echo in/out phase. 3D dynamic T1WI with and without fat saturation acquisitions was obtained before and after the administration of intravenous paramagnetic contrast medium (Dotarem 15 mL at 3 mL/s flow rate) in

the axial and coronal plane. Routine subtraction imaging with the dynamic series was also obtained.

A heterogeneous cystic renal mass with a smooth minimally thickened enhancing wall of 3 mm was found at the superior pole of the right kidney. The mass was primarily composed of proteinaceous fluid with a total of four thin septae, two of which had significant post-contrast enhancement, in the “T1 subtraction images” (Fig. 1). The cyst was classified as Bosniak IIF, and the patient was referred back to the urology clinic for pain management and for a 3-month follow-up at our institution.

Three months later, the patient experienced a traumatic fall 1 week before his follow-up. His pain subsequently worsened, blood pressure increased, haemoglobin fell down, and he was immediately brought to our emergency room for an urgent CT scan. The studies revealed a moderate hematoma surrounding the right kidney enclosed by Gerota’s fascia (Fig. 2). Supportive care was provided until the symptoms

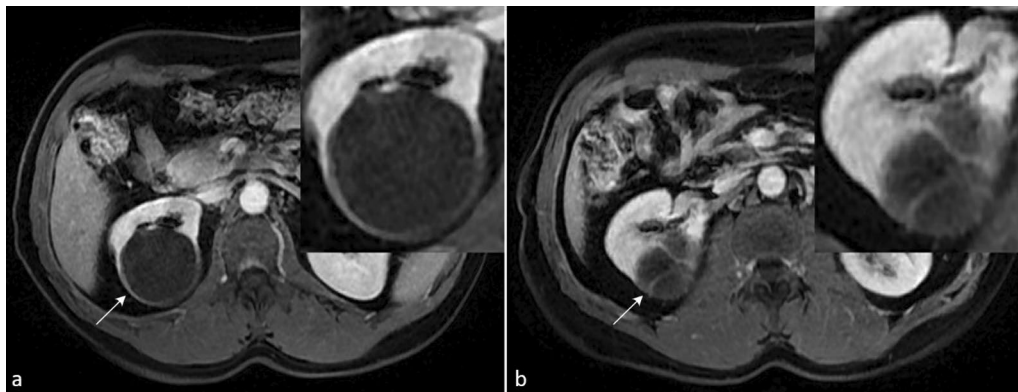

Fig. 1 Right Bosniak IIF cystic renal mass (arrow) at the superior pole of the right kidney. **a** Axial T1-weighted sequence in portal venous phase showing minimally thickened wall (3 mm). **b** Axial T1-weighted sequence in portal venous phase shows two of the four thin enhancing septae

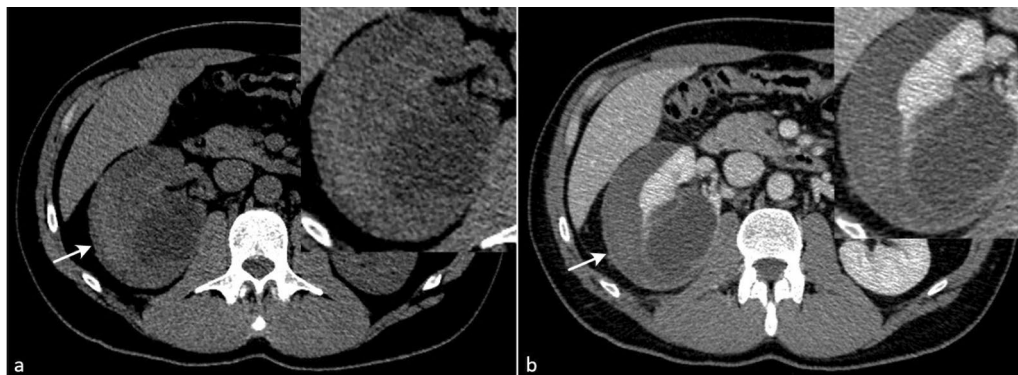


Fig. 2 CT showing a large hematoma (arrow) surrounded by Gerota’s fascia in the perirenal space. **a** Pre-contrast sequences showing the cystic mass surrounded by a hyperdense haematoma in the perirenal space. **b** Portal venous phase in CT showing Gerota’s fascia enclosing the fluid collection

subsided, and the patient was discharged for urological evaluation.

Upon experiencing this trauma, the patient's urologist recommended cyst decortication for symptom relief. Hence, a four-port transperitoneal laparoscopic robot-assisted approach was used to drain the cyst and biopsy suspicious regions. A biopsy sample consisting of fibrous and adipose tissue was obtained from the solid portion of the lesion seen in laparoscopy and sent to the pathology laboratory for analysis.

On histopathological examination, the lesion was found to be cystic, covered by a thick fibrous capsule, with a 4 mm focus of clear cells on the luminal side. Immunohistochemical staining showed a positivity for PAX8 and CD10, with the nuclei lacking clearly distinguishable nucleoli. These findings were compatible with a diagnosis of cystic variant International Society of Urological Pathology (ISUP) Grade 1 Clear Cell Carcinoma [5]. A post-operative MRI was used to assess the outcome of the procedure. The remnants of the proteinaceous fluid-filled cysts with thickened walls were observed at the superior pole of the right kidney (Fig. 3). In addition, a hypovascular nodular lesion (17 mm × 11 mm) was found within the cystic cavity (Fig. 4). On DWI and ADC sequences, neither hyperintensity nor hypointensity was observed within the region. The T2-weighted sequences showed a hypointense region within the posterior–superior aspect of the fluid collection, which most likely corresponded to fibrous tissue. The kidneys were of normal size and shape, and the ratio of cortical to medullary tissue was normal with even contrast distribution bilaterally. There were no signs of upper urinary tract obstruction. Upon receiving the diagnosis and being informed of the potential complications from the procedure, the patient decided to proceed with active surveillance.

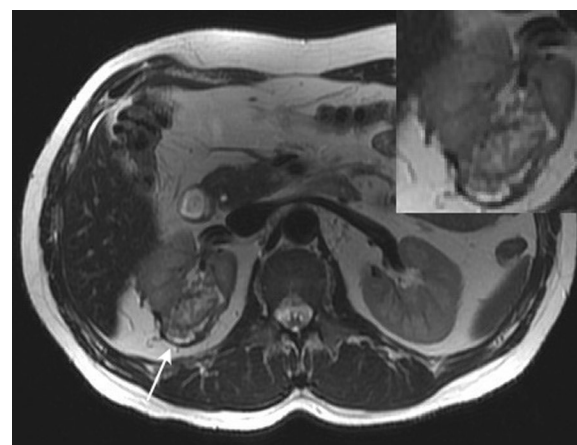


Fig. 4 Follow-up MRI at 3 months. Axial T2WI sequences highlighting a hypointense rim (arrow) in the posterior–superior aspect of the right perirenal space, most likely indicating benign fibrotic tissue

Discussion

In this case report, we highlight how important it is to consider whether a cystic lesion is malignant and prevent the treatment options being chosen prematurely, especially in the setting where evidence-based data are lacking.

Based on the current literature, following up with patients with Bosniak IIF lesions should be considered the gold standard for the management of these lesions. According to a systematic review published by Schoots et al. in 2016, Bosniak IIF complex renal cysts progressed to the Bosniak III or IV in 12% of cases. The malignancy rate in these cases was 86%, similar to the 89% malignancy rate observed in Bosniak IV complex cysts [6]. It should, however, be emphasized that this systematic review included studies using the classification proposed

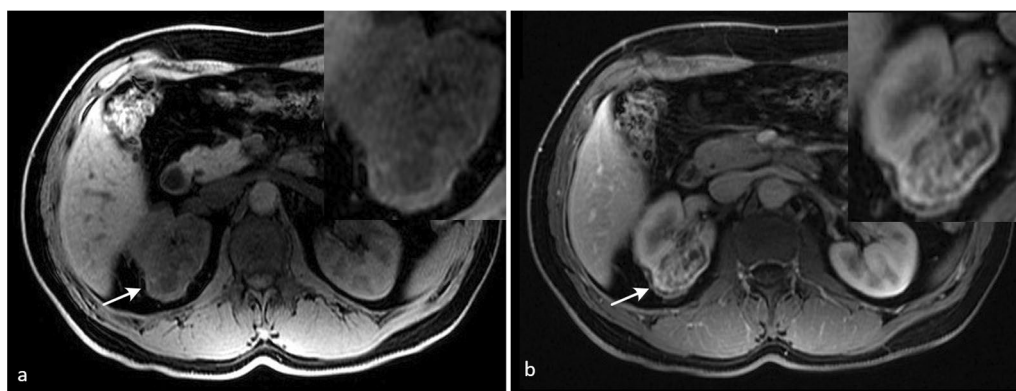


Fig. 3 Follow-up MRI at 3 months. **a** T1WI sequence showing regions of hyperintensity in the cystic space (proteinaceous material). **b** Contrast-enhanced axial T1-weighted sequence, in arterial phase, showing cyst's thickened wall (arrow)

in 2005 that was intended for CT imaging studies. Future studies in the field of cystic renal masses should focus on malignancy rates observed employing the 2019 Bosniak classification proposed for MRI scans.

In the case of patients that require urgent surgical treatment, partial nephrectomy would be the more prudent option. The possibility of retroperitoneal seeding should always be kept in mind even for low-grade clear cell carcinomas. Medical practice is fraught with the challenge of finding the right balance between caution and practicality.

Conclusion

In situations where evidence-based data are lacking, it is imperative to consider whether a cystic lesion is malignant. Further research should be conducted in order to fully understand the differences in malignancy rates in Bosniak IIF cysts between CT and MRI. It is crucial to consider the probability of malignancy in MRI; IIF cysts should be carefully scrutinised and staged using the new classification before choosing a treatment option. Retroperitoneal seeding should always be considered in interventions involving an incomplete resection margin or cyst drainage.

Abbreviations

MRI: Magnetic resonance imaging; CT: Computed tomography; T1WI: T1-weighted imaging; T2WI: T2-weighted imaging; DWI: Diffusion-weighted imaging; ADC: Apparent diffusion coefficient; POCUS: Point-of-care ultrasound.

Acknowledgements

Not applicable.

Author contributions

All authors (AF, MB, SL, AP, GMB, MD) have contributed significantly to the content of the article by participating in the data collection, interpretation of imaging results, and drafting of the manuscript. We confirm that there has been no previous publication of this manuscript, nor is it under consideration by another journal. All authors have read and approved the final manuscript.

Funding

No funding was obtained for this publication.

Availability of data and materials

The data that support the findings of this study are available on request from the corresponding author.

Declarations

Ethics approval and consent to participate

The patient included in this study gave written informed consent to participate in this research.

Consent for publication

Written informed consent was obtained from the patient for publication of this case report and accompanying images.

Competing interests

The authors declare that they have no competing interests.

Author details

¹Department of Radiological Science, Oncology and Pathology, Sapienza University/Policlinico Umberto I, Viale Regina Elena 324, 00161 Rome, Italy.

²Oncological Urology, Veneto Institute of Oncology IOV-IRCCS, Padua, Italy.

³Department of Urology and Renal Transplantation, University of Foggia, Policlinico Riuniti, Foggia, Italy.

Received: 5 April 2022 Accepted: 8 May 2022

Published online: 16 May 2022

References

1. Israel GM, Bosniak MA (2005) An update of the Bosniak renal cyst classification system. *Urology* 66(3):484–488
2. Silverman SG, Pedrosa I, Ellis JH, Hindman NM, Schieda N, Smith AD, Remer EM, Shinagare AB, Curci NE, Raman SS, Wells SA (2019) Bosniak classification of cystic renal masses, version 2019: an update proposal and needs assessment. *Radiology* 292(2):475–488
3. Schieda N, Davenport MS, Krishna S, Edney EA, Pedrosa I, Hindman N, Baroni RH, Curci NE, Shinagare A, Silverman SG (2021) Bosniak classification of cystic renal masses, version 2019: a pictorial guide to clinical use. *Radiographics* 41(3):814–828
4. Panebianco V, Giganti F, Kitzing YX, Cornud F, Campa R, De Rubeis G, Ciardi A, Catalano C, Villeirs G (2018) An update of pitfalls in prostate mpMRI: a practical approach through the lens of PI-RADS v. 2 guidelines. *Insights Imaging* 9(1):87–101
5. Grigley JR, Delahunt B, Eble JN, Egevad L, Epstein JI, Grignon D, Hes O, Moch H, Montironi R, Tickoo SK, Zhou M (2013) The International Society of Urological Pathology (ISUP) Vancouver classification of renal neoplasia. *Am J Surg Pathol* 37(10):1469–1489
6. Schoots IG, Zaccari K, Hunink MG, Verhagen PC (2017) Bosniak classification for complex renal cysts reevaluated: a systematic review. *J Urol* 198(1):12–21

Publisher's Note

Springer Nature remains neutral with regard to jurisdictional claims in published maps and institutional affiliations.

Submit your manuscript to a SpringerOpen[®] journal and benefit from:

- Convenient online submission
- Rigorous peer review
- Open access: articles freely available online
- High visibility within the field
- Retaining the copyright to your article

Submit your next manuscript at ► [springeropen.com](https://www.springeropen.com)